Cup orientation in new generation, dual mobility CMC I joint implant arthroplasty. Is there a gold standard?

Athanaselis E.D.[2], Wenger A.[1], Spühler D.L.[1], Karachalios T.[2], Varitimidis S.[2], Schmidt V.J.[1], Hainich J.Ch.[1]

[1] *Department of Plastic Surgery and Hand Surgery, Kantonsspital St. Gallen, St. Gallen, Switzerland*

[2] *Department of Orthopaedics, University General Hospital of Larissa, Larissa, Greece*

Affiliations:

Efstratios Athanaselis, MD, PhD

Senior Consultant, Department of Orthopaedics,

University General Hospital of Larissa-Larissa, Greece

Andrea Wenger, Dr. Med. Dr. Med. Univ.

Consultant, Department of Plastic Surgery and Hand Surgery,

Kantonsspital St. Gallen-St. Gallen, Switzerland

Dominik L. Spühler, MD

Consultant, Department of Plastic Surgery and Hand Surgery,

Kantonsspital St. Gallen-St. Gallen, Switzerland

Theofilos Karachalios, Professor of Orthopaedics

Department of Orthopaedics,

University General Hospital of Larissa-Larissa, Greece

Sokratis Varitimidis, Professor of Orthopaedics

Department of Orthopaedics,

University General Hospital of Larissa-Larissa, Greece

Volker J. Schmidt, P.D. Dr. Med.
Head of Department of Plastic Surgery and Hand Surgery,
Kantonsspital St. Gallen-St. Gallen, Switzerland
Jörg Ch. Hainich, Dr. Med
Senior Consultant, Department of Plastic Surgery and Hand Surgery, Kantonsspital St. Gallen-St. Gallen, Switzerland

Corresponding Author:
Efstratios D. Athanaselis MD, PhD
Senior Consultant, Department of Orthopaedics, University General Hospital of Larissa-Larissa, Greece
e-mail: athanaselis@uhl.gr
tel.: +302413502719

Abstract

Press-fit, ball-and-socket, and dual mobility implant arthroplasties of new generation with porous-coated stems and cups and metal-on-polyethylene bearings, gain ground in thumb carpometacarpal joint arthritis treatment. Orientation of the trapezium component (cup) is still a controversial issue and cup placement parallel to the scaphotrapezium joint level has been advocated.

We retrospectively analyzed a group of 80 CMC I joint arthroplasties, evaluating cup inclination in relation to proximal pole of trapezium and scaphotrapezium joint level, functional results and complication rates, aiming to examine the way that cup orientation may affect arthroplasty outcome.

The results revealed that in the studied group the cup was placed in a safe osteochondral area of the distal pole of the trapezium and most often in abduction and flexion of about 10° corresponding to surgeon's intention, with a satisfying outcome and significantly low rates of prosthesis dislocation and loosening.

In conclusion, there is no evidence that successful outcome of CMC I joint arthroplasty depends upon orienting cup parallel to the scaphotrapezium joint level.

Introduction

Thumb carpometacarpal arthritis (CMC I) is a common health issue especially in aging population. Radiographic findings are present in 5.8% of males and 7.3% of females, rising up to 33.1% and 39.0% respectively by the age of 80 [1]. Though clinical manifestation is present in less patients, arthritis of the base of the thumb can cause significant functional impairment in daily living due to the important role of thumb opposition.

Aiming to pain relief and improved functionality of thumb and hand, various surgical treatment options have been introduced since Gervis proposed simple trapeziectomy in 1947 [2]. Trapeziometacarpal arthrodesis, trapezium resection with interposition or suspension arthroplasty and ligament reconstruction using

tendon grafts, are surgical interventions that have been widely used and studied during the last decades. However, there is inconclusive evidence to support prominence of a specific technique among the others in terms of pain and function [3].

Implant arthroplasties were introduced in 1972 when a silicone implant, was used to replace the base of the thumb metacarpal [4]. De la Caffinière introduced in 1974 a cemented prosthesis [5]. Since then, prostheses have been improved and nowadays, second generation cementless, ball-in-socket joint prostheses gain ground in CMC I arthritis treatment. [6, 7].

Though trapeziectomy with or without tendon intervention techniques, is still the treatment of choice widely, the use of CMC I joint prostheses has been increasing during the last 10-15 years. New generation implants (e.g., Maia, Arpe, Ivory, TOUCH) show high survival rate (>90%) apart from important functional advantages over older techniques [7-9]. Press-fit, porous-coated stems and cups, ball-and-socket, metal-polyethylene bearings and dual mobility are advances that have improved CMC I joint implant arthroplasty outcome [6]. Though ball-and-socket prostheses integrate many degrees of freedom minimizing dislocation, liner wear and loosening rates, positioning of the components is an important parameter of arthroplasty survival. This has to do mostly with the trapezial cup orientation that is crucial and besides, much more technically demanding [10-13]. Cup should be placed in distal pole of trapezium preserving osteochondral joint surface for better fixation. Meanwhile, some authors recommend a parallel orientation of the cup to the scaphotrapezium joint level. Taking into account these two parameters, fixation of the cup and biomechanical behavior of the arthroplasty as well, can be optimized. However, the application of both of these guidelines is not always possible.

The aim of this project is to evaluate whether cup orientation affects thumb CMC joint arthroplasty functional results and complication rates.

Material and method

We retrospectively reviewed medical records of patients that were treated for thumb carpometacarpal arthritis with prosthesis arthroplasty from 2019 to 2023 in Kantonsspital St. Gallen. The study group included eighty cases of CMC I arthritis of stage II-IV according to Eaton-Glickel classification [14] treated with prosthesis arthroplasty in sixty-five patients (19 males, 46 females).

A new generation uncemented, ball-and-socket, dual mobility prosthesis (MAÏA™ prosthesis, Lépine) was used in all cases. It is composed by a porous-coated stem (metacarpal component), a porous-coated hemispherical cup (trapezium component) and a modular neck (straight or with palmar offset). All cases were operated by skilled hand surgeons with high expertise using dorso-radial approach.

Post-operative x-rays were examined particularly for the evaluation of the orientation of the cup (trapezial component). For that purpose, the angle between the cup and the proximal pole of the trapezium and the scapho-trapezium joint (STJ) line was measured for each patient and arthroplasty in two views: the antero-posterior and the lateral as they have been described by Kapandji [15].

This angle, contained within two lines representing cup's plane and the proximal pole of the trapezium pictures cup inclination in comparison to scaphotrapezium joint level. The antero-posterior view reveals the positioning of cup in palmar abduction or adduction according to the STJ. The lateral view demonstrates the tilt of the cup in flexion or extension to the STJ. Angle was measured between the line connecting the most distal points of the cup and the line that connects the two corners of the proximal pole of the trapezium (figure 1). In anteroposterior view, a negative value of angle indicates a cup oriented in abduction and a positive value indicates an adducted cup. Likewise, in lateral view, angle is negative for cups placed in extension and positive when they are oriented in flexion. Obviously, angles of zero degrees in both views should be measured in

case of a cup placed parallel to the proximal pole of the trapezium and the scapho-trapezium joint level.

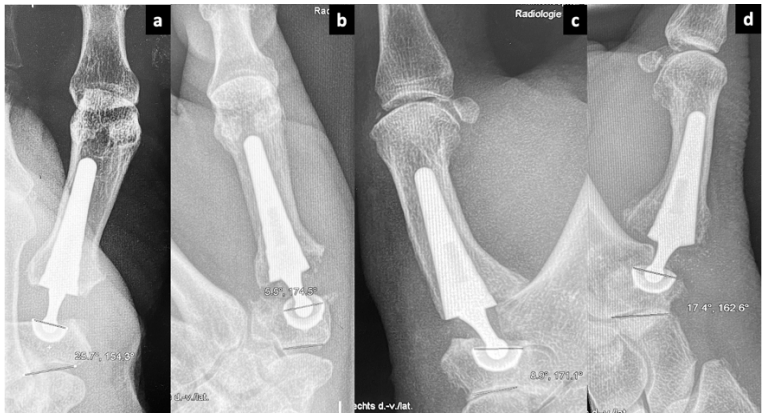

Figure 1: cup inclination is evaluated by measuring angles between lines drawn on cup brim and proximal pole of trapezium in antero-posterior (a, b) and lateral thumb views (c, d).

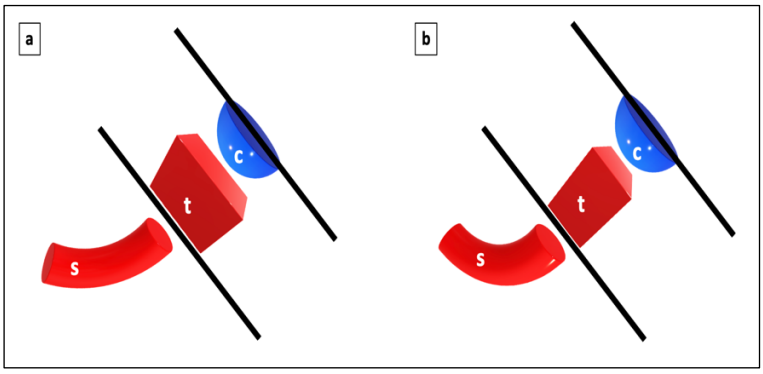

Figure 2: in an oblique projection diameter of the cup should be drawn between the most distant points of its brim as part of the plane of the cup. These lines indicate a cup parallel to the scaphotrapezium joint only in case they are parallel in two different x-ray views (a, b).
(c=cup, t=trapezium, s=scaphoid)

Unfortunately, available x-rays are not always of best quality according to Kapandji guidelines. This was an insuperable issue due to the retrospective type of the study. However, this can partially affect the outcome of angle measurements: the obliquity in a projection can bias the measured angle but it cannot disregard a case that cup is oriented absolutely parallel the ST joint. In such case the aforementioned lines being on the planes that represent the base of the trapezium, and the brim of the cup, must be parallel in any aspect (x-ray view) as these planes are so (i.e., in case the cup is oriented parallel to the scapho-trapezium joint) (figure 2).

Moreover, data regarding radiographs (implants stability or translation, radiolucent lines, arthroplasty dislocation) and clinical outcome (thumb ROM, pain, sensation) were collected during a mean follow-up period of 26,4 months (range 1-53) by patients' examination at 2, 6, 12 weeks and yearly.

Results

Eighty implantations were studied in total. Prosthesis was applied in 37 right and 43 left upper limbs while 12 patients (5 males, 7 females) were bilaterally operated, and 3 male patients underwent a revision surgery. The mean age of patients was 62,3 years (range 45-90). In male patients the average age was 62,7 years (range 45-90) and in female 62,2 years (range 46-86). In 4 cases (3 patients), arthroplasty of CMC I joint was combined with scaphotrapeziotrapezoid joint (STT) resurfacing arthroplasty due to basal thumb joint arthritis of stage IV. In one of these patients, both interventions took place bilaterally.

Post-operative antero-posterior and lateral x-rays of the thumb were studied measuring angles of cup inclination. In anteroposterior views negative values correspond to a cup lying in palmar abduction whereas, positive values indicate adduction. In lateral views negative values are measured in case of a cup in extension and positive ones in cup flexion. Zero angles in both views correspond to parallel positioning. The average angle measured in AP views was -9,9° ranging from -38,7° to +23,5°. Accordingly, the mean angle in lateral views was 10,5° ranging from -17,4° to +38,3° (chart 1, 2, 3).

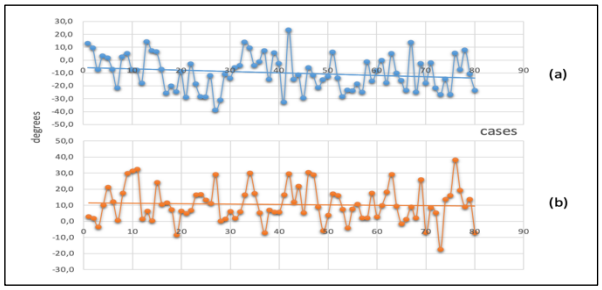

Chart 1: measured degrees of cup inclination in relation to scaphotrapezium joint line. Abduction (-) and adduction (+) in antero-posterior x-rays (a). Extension (-) and flexion (+) in lateral x-rays (b).

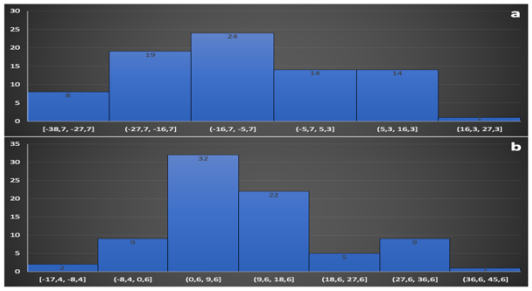

Chart 2: cases distribution in the range of measured values of abduction-adduction (a) and extension-flexion (b) degrees.

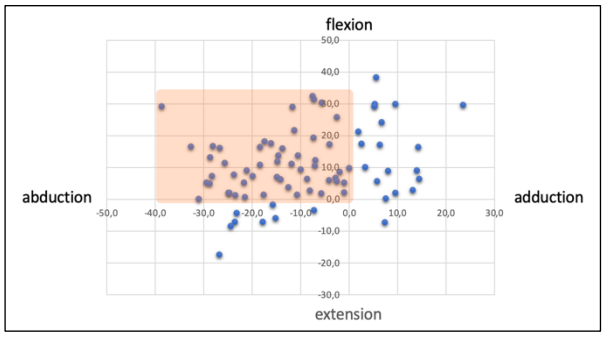

Chart 3: cases distribution according to measured angles of cup inclination in two dimensions. The majority of the cases is found in flexion-abduction quadrant.

Thumb ROM was significantly improved. Palmar abduction increased in average from 23° pre-operatively to 35° (range 28-38°) post-operatively and radial abduction from 28° to 38° (range 31-42°). Accordingly, Kapandji score increased from 5,7 to 7,8. Seventy-one patients (88,75%) were very satisfied or satisfied with the functional outcome in daily living. Pain evaluated by VAS score was reduced from 7,1 (moderate) to 1,9 (mild) in average. Hyposensitivity in the dorso-radial aspect of the thenar was reported by 16 patients, lasting for the first 3-4 months post-operatively. There was no surgical site infection.

During the follow-up period, complications occurred in 4 male patients including 2 cases with trapezium fracture, 1 case with cup loosening and 1 dislocation of the prosthesis. One of the patients with trapezium fracture denied revision surgery reporting satisfying function instead. The other 3 patients underwent cup revision surgery. Cup loosening in progress was suspected in 3 cases due to radiographic findings (radiolucent line). Nevertheless, there were no clinical signs or symptoms. Tenosynovitis of the 1st extensor compartment (De Quervain syndrome) appeared in 2 cases within 3 months post-operatively and it was treated operatively.

Discussion

Saddle-shape of distal pole of the trapezium implies complex kinesiology of thumb carpometacarpal joint. Extension-flexion rotation axis is located in the trapezium while abduction-adduction motion has its center of rotation in the first metacarpal. Ball-and-socket implants and moreover, dual mobility function (adopted from total hip arthroplasty) are characteristics of second generation's CMC I joint arthroplasties. However, their effectiveness in reproducing basal joint's biomechanics is controversial [16-18].

Cup component of new generation CMC I joint implant arthroplasties, is hemispherical or conical, porous-coated and press-fit. It is placed in distal pole of trapezium after verifying proper position and orientation. For a stable cup

fixation, preservation of osteochondral bone of the distal joint surface of the trapezium is a prerequisite. Cup must be placed in the center of the distal joint surface of the trapezium. Targeting to a central point during preparation of the trapezium, protects it from an iatrogenic fracture and ensures a stable fixation [10].

On the other hand, there is currently a lot of debate in the literature over the cup orientation issue as the number of studies on implant arthroplasty of the basal joint of the thumb, increases. It has been highlighted by many authors, that orientation of the cup parallel to the scaphotrapezium joint level is crucial for the biomechanical behavior of the arthroplasty. Neutral cup placement, considered to be a parallel to scaphotrapezium joint (STJ) or just to the proximal pole of the trapezium, shows lowest risk of prosthesis dislocation in full range of thumb movement [11, 19, 20]. Due to the relative simplicity of the scaphotrapezium joint, STJ line can be used as a radiographic guide for the cup orientation as long as there is no severe osteoarthritic deformation [21].

However, the application of both of these guidelines is not always possible. Morphology, inclination and osteophytes of the distal pole of the trapezium often restrict the suitable area for cup application. Moreover, osteotomy and bone resection in an effort to rearrange the surface parallel to STJ, may decorticate distal pole and expose cancellous bone of the trapezium, deteriorating cup's stable fixation.

Despite the fact that the saddle-shaped distal trapezium pole surface is not a flat plateau, anatomical variations of the trapezium and more often, deformity due to excessive degenerative destruction of the distal pole makes it difficult to preserve a sufficient osteochondral central area for cup fixation along with orienting it parallel to the scaphotrapezium joint line. In case of thumb carpometacarpal joint degenerative arthritis, trapezium has quite often decreased height in an asymmetrical way with radial side being shorter than the ulnar one, producing quite significant inclination of its distal pole in many cases [11, 13, 22, 23].

Preparation of a flat surface by removing osteophytes cannot rearrange its orientation without sacrificing osteochondral tissue and compromising the rigidity of the area where cup will be applied.

On the other hand, Duerinckx and Caekebeke in 2016, suggested that the cup should be oriented parallel to the proximal pole of the trapezium in anteroposterior view but slightly flexed (7°) in lateral view which can be alternatively succeeded using a neck with palmar offset [13]. Moreover, a recent biomechanical study showed that dislocation risk is high if cup is positioned in 10° or more of dorsal inclination relative to STJ while flexion does not affect arthroplasty's stability. Accordingly, an abducted or adducted cup of more than 20° seems also, to increase dislocation rate. However, the use of a neck with offset can reduce dislocation risk adding degrees of freedom in arthroplasty's ROM but its effectiveness is not unlimited [20].

In our study, the results reveal significant incompliance with the "parallel cup" rule. Surgeons' choice for cup orientation consists of about 10° of abduction and flexion (9,9° and 10,5° respectively) and it is always combined with an offset neck. Though there is a variety of measured angles ranging from 38,7° of abduction to 23,5° of adduction and from 17,4° of extension to 38,3° of flexion, the majority of coupled values are located in the abduction-flexion quadrant and flexion quadrants (chart 1, 2, 3). Moreover, a tendency for increased abduction and decreased flexion is detected during the 4-year period of the application of the CMC I joint implant arthroplasty (chart 1). These findings agree with surgeon's intention in cup orientation aiming in combination with an offset neck, to maximize thumb mobility and minimize impingement and dislocation risk.

The exact position of the cup implantation depends not only on the joint surface morphology and inclination, but also on sufficient rigid osteochondral coverage of bone. For a stable cup implantation, surrounding osteophytes must be excised without jeopardizing it. In 55 case (69%) cup found to be placed in the central area of the distal joint surface of the trapezium. In the rest cases cup was

eccentrically fixed with dorsal (8), dorso-radial (7) and radial (6) positions to be more common, whereas volar (1), volar-ulnar (1) and dorso-ulnar (2) positions were rarely selected (table 1).

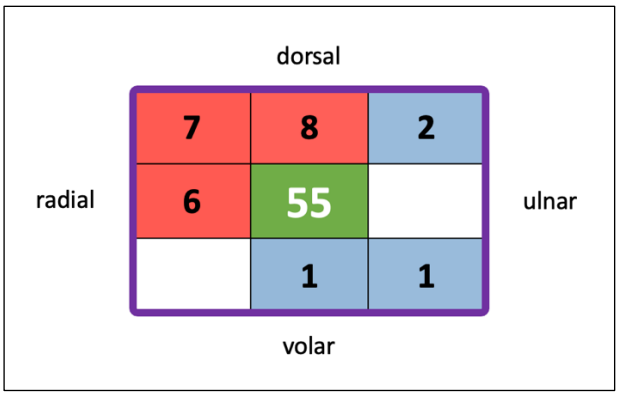

Table 1: Distribution of cup positions on the surface of distal pole of trapezium. In most of the cases, cup was placed centrally while among eccentric positioning, dorsal and dorso-radial areas dominate.

Surgeon's perception of the available surface may be influenced by the surgical approach and by residual osteophytes. Restricted view of the distal pole and excessive bone can bias against the correct position of implantation and the orientation of the cup, as well. Dorso-radial approach is preferable due to the sufficient visualization of the CMC joint that it provides, and osteophytes are excised from the base of the metacarpal and from the trapezium especially on its ulnar side. However, in 7 cases residual osteophytes have been marked in post-operative x-rays.

Furthermore, adequate range of thumb metacarpal motion without dislocation depends on cup orientation. Combined flexion and abduction angle of about 10°, seems to achieve unrestricted but stable thumb opposition. Both abduction and flexion are components of thumb opposition while volar dislocation is limited by capsuloligamentous constraints around the CMC joint and especially the dorsoradial ligaments which stabilize the joint anyway [24]. On the other hand, the selection of a neck with offset also improves the functional outcome avoiding neck-cup impingement mechanism of dislocation [13, 18, 20, 25, 26]. Of course, thumb mobility is thoroughly examined with the trial neck in order to reveal possible dislocation, impingement or redundant pistoning. Modifications of neck

size, type (offset or straight) and osteophytes excision may solve the problem. Otherwise, re-orientation of the cup will be needed (figure 3).

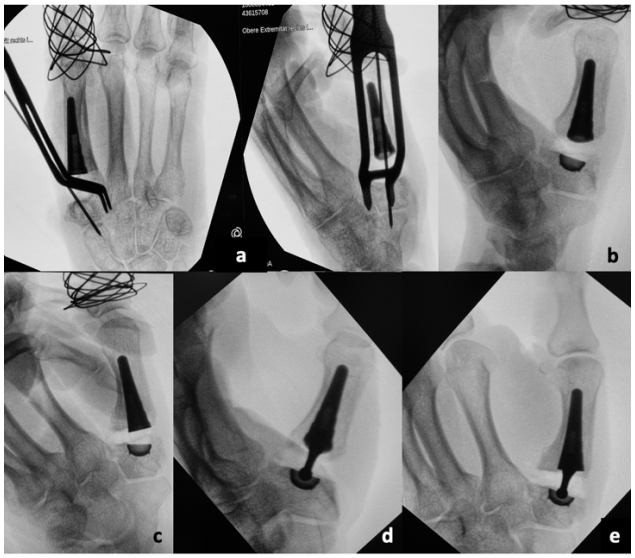

Figure 3: after stem implantation in thumb metacarpal and trapezium distal pole preparation, position and orientation of the cup are defined and checked intra-operatively by the image intensifier, using a K-w as a guide over which, cup socket will be prepared in trapezium (a). Cup is press-fitted and a trial neck is applied for checking the mobility of the thumb and the stability of the arthroplasty (b, c). Permanent offset neck of proper size with is placed and the dual mobility head is reduced in the cup (d, e).

STT arthritis is considered as one of the major contraindications for CMC I joint arthroplasty. Degenerative findings at the proximal pole of the trapezium can cause pain by thumb movement and functional disability despite the treatment of CMC joint. Decreased mobility in STT joint can also increase loading of arthroplasty. Thus, co-existing STT arthritis in 4 cases in our series was treated with STT arthroplasty at the same time.

Considering that an improperly oriented cup can drive to dislocation and consequent altered biomechanics of the arthroplasty may provoke implant loosening and wear [18, 25-27], results of our study validate proper application and function of arthroplasty's components. The insignificant rates of post-operative dislocation (1 case=1,26%) and cup loosening (1 case=1,26%), verify the effectiveness and reliability of the technique.

Dislocation happened in one case 1,5y post-operatively. Although patient did not comply with rehabilitation guidelines, starting quite early to use hand in heavy outdoor activities, radiographic evaluation revealed that cup had been placed volarly and radially in 14,4^{o} of adduction and 6,4^{o} of flexion resulting in impingement of the offset neck. Cup was revised reducing adduction and flexion,

residual osteophytes were removed, and capsule was reefed due to marked joint laxity (figure 4).

Figure 4: CMC I subluxation and stage II arthritis in 47-years-old male left hand (a, b). CMC I joint arthroplasty with volarly and radially placed stem in adduction and flexion resulting in impigement (c, d, e, f, g). Consequent arthroplasty dislocation was treated with cup revision and residual metacarpal osteophytes resection (h, i).

Cup loosening was diagnosed 4 months post-operatively in a case in which cup was oriented in 2º of abduction and 8,6º of flexion. It may be associated with dorsal positioning of the cup though this site of placement was marked in 17 cases in total. Implants (cup and stem) were removed, and culture samples were collected for excluding septic loosening though there was no such clinical suspicion. Medullary canal of the metacarpal was fulfilled with antibiotic loaded cement and trapezium cavity was grafted with autologous bone from the iliac crest fixed with K-w. New prosthesis was applied 9 months later (figure 5).

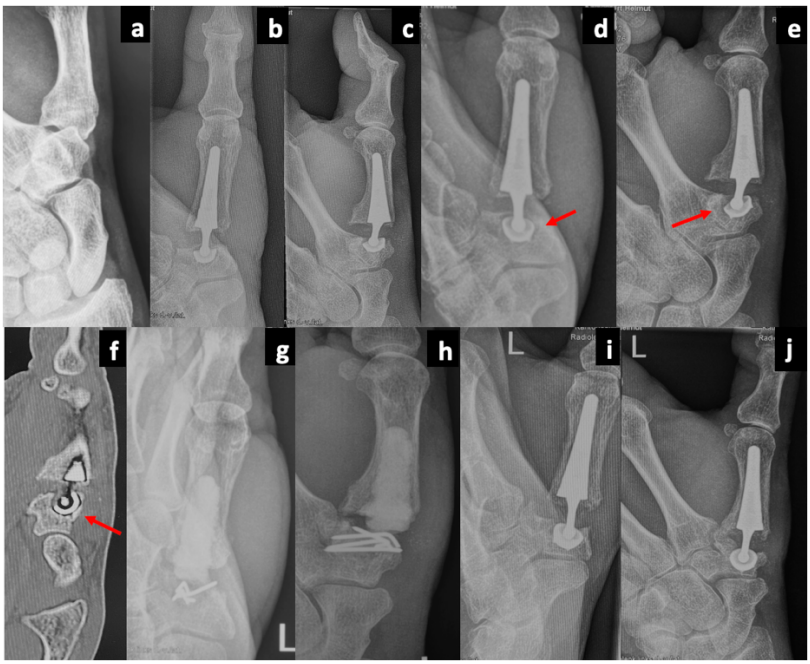

Figure 5: CMC I stage I-II painfull arthritis in 70-years-old male left hand (a). CMC I joint arthroplasty (b, c) and cup loosening 4 months post-operatively with radiolucent lines (red arrow) in x-rays and ct-scan (d, e, f). Cup and stem removal, autologous bone grafting and K-w fixation (g, h). Revision arthroplasty 9 months later (i, j).

Radiographic radiolucent lines around cup component were marked in 3 cases. In absence of any clinical symptom, no intervention has been planned so far.

Furthermore, there were 2 cases (2,5%) with trapezium fracture. In one case, in which the cup was placed dorso-ulnarly in 5,8° of abduction and 1,9° of flexion, fracture happened 17 months post-operatively. It was treated by cup removal, bone grafting with autologous bone from the iliac crest, fixation with k-w's and new cup application 3 months later, after consolidation of the trapezium was clinically and radiographically confirmed (figure 6). In the other case, trapezium dissociation was diagnosed in less than a month post-operatively caused maybe by "over-impaction" of cup. However, patient denied revision surgery claiming that he was satisfied with his hand function. Apart from this case, there were 2 others with deep cup impaction in trapezium.

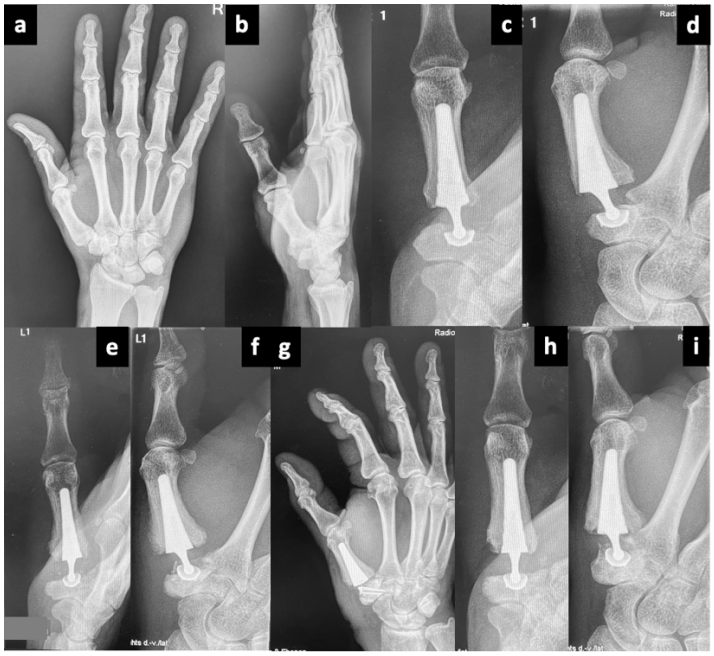

Figure 6: CMC I subluxation and stage II arthritis in 54-years-old male right hand (a, b). CMC I joint arthroplasty and trapezium fracture 17 months post-operatively (c, d, e, f). Cup removal, autologous bone grafting and K-w fixation (g). Revision arthroplasty with new cup 3 months later (h, i).

Tenosynovitis De Quervain as a post-operative complication, was diagnosed in 2 cases and it was treated by 1st extensor compartment release. Considering this complication and assuming that the modification in tendons' route together with the increased ROM of thumb can provoke such symptomatology, 1st extensor compartment release was decided to be performed as a standard procedure during the implementation of the prosthesis.

Minor complications include mild hyposensitivity around the skin incision and in the dorso-lateral site of the thenar caused probably by end branches of superficial radial nerve traction during the operation. All cases have recovered and there was no permanent sensation loss or neuroma formation.

There are some limitations in our study. We have already described the methodology that was followed for measuring the angle between the cup and the STJ. The lack of standard AP and lateral views of the thumb carpometacarpal joint according to Kapandji guidelines, certainly affects the measurements. However, as it has also been explained, a cup placed parallel to the STJ should give measured angles of zero degrees in every view and radiographic projection. Therefore, though the results may be biased to a degree, the repetitive findings, coincident with surgeon's intention, signify the followed technique in cup positioning and orientation. The absence of a control group is another drawback but the extremely low rates of complications in the studied group, practically diminish the need of comparison. Of course, cup orientation in CMC I joint implant arthroplasty still remains a controversial issue necessitating further clinical and biomechanical research.

Conclusion

Good functional results and low complication rates of CMC I joint arthroplasty with cup component been placed not parallel to the scaphotrapezium joint, indicate that this is not an essential rule for a successful outcome. The cup must be positioned and oriented in a way that ensures stable fixation in trapezium and unrestricted thumb's mobility without dislocation tendency. In the present study, satisfying outcome was reached by placing the cup in slight flexion and abduction in comparison to scaphotrapezium joint level.

References

1. van der Oest MJW, Duraku LS, Andrinopoulou ER, Wouters RM, Bierma-Zeinstra SMA, Selles RW, Zuidam JM. The prevalence of radiographic thumb base osteoarthritis: a meta-analysis. Osteoarthritis Cartilage. 2021 Jun;29(6):785-792. doi: 10.1016/j.joca.2021.03.004. Epub 2021 Mar 17. PMID: 33744429
2. Gervis WH. Osteo-arthritis of the Trapezio-metacarpal Joint treated by Excision of the Trapezium. Proc R Soc Med. 1947 Jul;40(9):492. PMID: 19993599; PMCID: PMC2183574
3. Wajon A, Vinycomb T, Carr E, Edmunds I, Ada L. Surgery for thumb (trapeziometacarpal joint) osteoarthritis. Cochrane Database Syst Rev. 2015 Feb 23;2015(2):CD004631. doi: 10.1002/14651858.CD004631.pub4
4. Swanson AB. Disabling arthritis at the base of the thumb: treatment by resection of the trapezium and flexible (silicone) implant arthroplasty. J Bone Joint Surg Am. 1972 Apr;54(3):456-71. PMID: 5055148
5. de la Caffinière JY. Prothèse totale trapézo-métacarpienne [Total trapezo-metacarpal prosthesis]. Rev Chir Orthop Reparatrice Appar Mot. 1974 Jun;60(4):299-308. French. PMID: 4281097
6. Teissier J, Teissier P, Toffoli A. Trapeziometacarpal prostheses. Hand Surg Rehabil. 2021 Sep;40S:S106-S116. doi: 10.1016/j.hansur.2020.09.013. Epub 2021 Feb 1. PMID: 33540123
7. Martin-Ferrero M. Ten-year long-term results of total joint arthroplasties with ARPE® implant in the treatment of trapeziometacarpal osteoarthritis. J Hand Surg Eur Vol. 2014 Oct;39(8):826-32. doi: 10.1177/1753193413516244. Epub 2013 Dec 11. PMID: 24334554
8. Kapandji A. La prothèse cardan souple de l'articulation trapézo-métacarpienne. In: Saffar P, editor. La rhizarthrose. Monographie du GEM. Paris: Expansion Scientifique Française; 1990. p. 154-62

9. Goubau J, Benis S, Tchurukdichian A, Van Hoonacker P, Kerckhove, Berghs B. La prothèse Ivory: résultats à plus de cinq ans de recul. Étude multicentrique. Chir Main 2011;30(Suppl):55-8
10. Ledoux P. Echec de prothèse totale trapézo-métacarpienne non cimentée. Etude multicentrique [Failure of total uncemented trapeziometacarpal prosthesis. A multicenter study]. Ann Chir Main Memb Super. 1997;16(3):215-21. French. doi: 10.1016/s0753-9053(97)80004-x. PMID: 9453742
11. Lussiez B. Radiological analysis of two types of trapezium cup. About 50 cases. Chirurgie de la Main. 2011, 30: 86-90
12. Teissier J, Alkar F. Trapeziometacarpal Maia prosthesis for basal thumb arthritis. A series of 100 prosthesis with a minimum follow-up of 3 years. Chirurgie de la Main. 2011, 30: 77-82
13. Duerinckx J, Caekebeke P. Trapezium anatomy as a radiographic reference for optimal cup orientation in total trapeziometacarpal joint arthroplasty. J Hand Surg Eur Vol. 2016 Nov;41(9):939-943. doi:10.1177/1753193416630496. Epub 2016 Sep 28. PMID: 26896453
14. Eaton RG, Glickel SZ. Trapeziometacarpal osteoarthritis. Staging as a rationale for treatment. Hand Clin. 1987 Nov;3(4):455-71. PMID: 3693416
15. Kapandji A. Anatomie fonctionnelle et biomécanique de la métacarpo-phalangienne du pouce [Functional anatomy and biomechanics of the metacarpo-phalangeal joint of the thumb (author's transl)]. Ann Chir. 1981;35(4):261-7. French. PMID: 7247304
16. Huang K, Hollevoet N, Giddins G. Thumb carpometacarpal joint total arthroplasty: a systematic review. J Hand Surg Eur Vol. 2015 May;40(4):338-50. doi: 10.1177/1753193414563243. Epub 2015 Jan 19. PMID: 25600851
17. Crisco JJ, Halilaj E, Moore DC, Patel T, Weiss AP, Ladd AL. In Vivo kinematics of the trapeziometacarpal joint during thumb extension-flexion and abduction-adduction. J Hand Surg Am. 2015 Feb;40(2):289-96. doi:

10.1016/j.jhsa.2014.10.062. Epub 2014 Dec 24. PMID: 25542440; PMCID: PMC4306611

18. Murai A, Kurosawa A, Tada K, Tachiya H, Tamai A, Akahane M, Matsuta M, Nakamura Y, Kawashima H, Tsuchiya H. Optimal Center of Rotation for Ball-And-Socket Thumb Carpometacarpal Arthroplasty Identified Using Three-Dimensional Kinematic Analysis: A Pilot Study. Front Bioeng Biotechnol. 2022 Jun 1;10:868150. doi: 10.3389/fbioe.2022.868150. PMID: 35721848; PMCID: PMC9200493
19. Jacoulet P. Résultats de la prothèse trapézomátacarpienne ARPE: à propos de 37 implantations [Results of the ARPE trapezometacarpal prosthesis: a retrospective study of 37 cases]. Chir Main. 2005 Feb;24(1):24-8. French. doi: 10.1016/j.main.2004.11.003. PMID: 15754707
20. Brauns A, Caekebeke P, Duerinckx J. The effect of cup orientation on stability of trapeziometacarpal total joint arthroplasty: a biomechanical cadaver study. J Hand Surg Eur Vol. 2019 Sep;44(7):708-713. doi: 10.1177/1753193419851775. Epub 2019 Jun 2. PMID: 31156021
21. Cooney WP, Linscheid RL, Askew LJ. Total arthroplasty of the thumb trapeziometacarpal joint. Clin Orthop Relat Res. 1987 Jul;(220):35-45. PMID: 3595008
22. Barron OA, Glickel SZ, Eaton RG. Basal joint arthritis of the thumb. J Am Acad Orthop Surg. 2000 Sep-Oct;8(5):314-23. doi: 10.5435/00124635-200009000-00005. PMID: 11029559
23. Goorens CK, Goubau J, Van Hoonacker P, Kerckhove D, Berghs B, Scheerlinck T. Addition-subtraction osteotomy without ligamentoplasty for symptomatic trapezial dysplasia with metacarpal instability. Acta Orthop Belg. 2013 Oct;79(5):517-23. PMID: 24350512
24. Edmunds JO. Traumatic dislocations and instability of the trapeziometacarpal joint of the thumb. Hand Clin. 2006 Aug;22(3):365-92. doi: 10.1016/j.hcl.2006.05.001. PMID: 16843802

25. Holme TJ, Karbowiak M, Clements J, Sharma R, Craik J, Ellahee N. Thumb CMCJ prosthetic total joint replacement: a systematic review. EFORT Open Rev. 2021 May 4;6(5):316-330. doi: 10.1302/2058-5241.6.200152. PMID: 34150326; PMCID: PMC8183150
26. Ganhewa AD, Wu R, Chae MP, Tobin V, Miller GS, Smith JA, Rozen WM, Hunter-Smith DJ. Failure Rates of Base of Thumb Arthritis Surgery: A Systematic Review. J Hand Surg Am. 2019 Sep;44(9):728-741.e10. doi: 10.1016/j.jhsa.2019.05.003. Epub 2019 Jun 28. PMID: 31262534
27. Facca S, Liverneaux PA. Feasibility of computer-assisted surgery for trapeziometacarpal prosthesis: a preliminary experimental study. Surg Radiol Anat. 2012 Nov;34(9):857-64. doi: 10.1007/s00276-012-0972-5. Epub 2012 Apr 25. PMID: 22532375

Acknowledgments

I would like to thank Dr. Jörg Hainich, Senior Consultant Hand Surgeon in the Department of Plastic Surgery and Hand Surgery in Kantonsspital of St. Gallen-Switzerland, for providing me the material of this study as it was based on his series of CMC I joint implant arthroplasties. I would also like to thank Dr. Andrea Wenger, Dr. Dominik Spühler, Consultants and Dr. Volker Schmidt, Head of the Department of Plastic Surgery and Hand Surgery in Kantonsspital of St. Gallen, for their assistance throughout this study and of course, the whole staff of the Department for the hospitality and the cooperation during my stay. Furthermore, I should thank Sokratis Varitimidis and Theofilos Karachalios, Professors in Orthopaedic Department of University Hospital of Larissa-Greece, for encouraging me to do this research fellowship. Finally, I am grateful to International Bone Research Association (IBRA) for the continuing education programs and the IBRA team for the substantial support, giving the opportunity to fellows to have a great international training experience.