Loss of fixation in fragment-specific Volar Hook Plate for Volar Marginal Rim Fractures: a case report

Dr Bruno Battiston[1], Dr Giuliana Olivi Tanaka[2]

1- Hand and Microsurgery Unit Orthopedic DPT. - C.T.O. Hospital – Città della salute e della scienza di Torino, Italy

2- Hand and Microsurgery Group of Institute of Orthopeadic and Traumatology of Faculty of Medicine of the University of São Paulo, Brazil

Keywords: volar hook plate, volar marginal rim fractures, distal radius fractures

Summary

Fragmentation of the volar marginal edge of distal radius fractures is a challenging problem to maintain correct internal fixation. Specific fixation of the fragment is indicated, but they involve difficult techniques and have limited resistance to bending and to axial load. Failure to reduce and maintain reduction of these volar ulnar intra-articular injuries results in disastrous volar carpal subluxation. We present a case of fixation with a specific volar hook plate to approach this fragment with posterior failure of reduction and radiocarpal dislocation.

Introduction

Distal radius fracture is the most common fracture of the upper extremity, accounting for 15% of all fractures[1].

In the last decade, treatment trends for distally displaced radius fractures have been popularized with a volar approach by Orbay and rigidly fixed using fixed-angle plates, which restores anatomy, joint congruity and stability and allows for early rehabilitation and return early to day-to-day activities[1]. Contemporary volar locking plates are designed to stabilize the lateral and external columns of the distal radius using variable angle locking screws and are intended to be positioned close to the dividing line[2].

The anatomy of the distal radius is concave and relatively flat compared to the dorsal surface, except for its distal lips, which slope volar to form the volar lunar facet. The concave surface of the volar radius is limited distally by the dividing line, which is easily palpable as a bony prominence through the fibrous layer and close (2 mm) to the joint line in its ulnar aspect[3]. Distal to the dividing line, the radius slopes in the dorsodistal direction and contains proximal insertions of the volar wrist capsule and the volar capsular ligaments, essential to prevent volar carpal subluxation. The volar lunar facet projects approximately 3 mm anterior to the flat volar surface of the distal radius and is vulnerable to injury[1].

Several biomechanical studies have reported that the center of force application is located on the volar ulnar palmar edge, which forms an articular portion of the sigmoid notch and serves as an attachment for the short radiolunar ligament, being considered the cornerstone of the radiocarpal joint and the distal radioulnar joint (DRUJ), which affects carpal stability. Therefore, failure to fix fragments in distal radius fractures can lead to loss of reduction and volar carpal subluxation[4,5].

A subset of intraarticular fractures involving the volar marginal border region, also known as the volar ulnar corner or ulnar corner, can be difficult to maintain reduction with current fixed-angle volar plate technology[2,6]. When this fragment is not adequately stabilized, devastating carpal subluxation or malunion can occur, which has made it one of the most difficult types of joint injuries to treat due to its unique anatomy. Failure to reduce and maintain reduction of these volar ulnar intra-articular lesions of the distal marginal edge results in disastrous volar carpal subluxation[6].

As volar subluxation occurs due to a shear force on this fracture, open reduction through the volar side using buttress plate is applied in many cases. However, the palmar carpal ligament pulls the volar dislocating fragment and causes rotation to the dorsal side upon application of the reduction. This dorsal rotational deviation of the volar bone fragment remains when treated with a simple buttress effect alone.

Fracture fragments are often small and distal to the dividing line, causing the volar plates to have a relatively thick profile relative to the unique anatomical dimensions of the lunate facet, leaving the volar marginal edge fragment inadequately supported, with unfavorable biomechanical shear forces[1,4].

Recently, many studies have reported that standard volar locking plates designed to be positioned proximal to the dividing line may not be able to adequately stabilize and reinforce the volar lunate face fragments distal to the dividing line in intra-articular fractures of the distal radius, although fixation volar fracture with a locked plate is a well-established technique for distal radius fractures[4].

These cases evolve with residual intra-articular volar bone displacement, with avascular necrosis and subsequent resorption and often result in limited range of motion of the wrist joint, carpal bone subluxation and early arthropathic changes of the wrist joint[6,7].

Fixation options for the volar lunate facet are technically difficult to perform and include temporary Kirschner wire fixation, ulnar end of a T-plate, tension wire technique, wire form fixation, and headless compression screw fixation[1,3].

Bakker and Shin introduced the volar hook plate (TriMed Orthopedics, Santa Clarita, CA) which was designed to treat volar marginal rim fracture in conjunction with fragment-specific fixation techniques. This implant was designed to be placed distal to the dividing line and allow stable fixation of the volar ulnar corner.

These distally placed plates specifically designed for implantation distal to the dividing line allow direct fixation of very distal fragments. Therefore, it has been the most used procedure for intra-articular fractures of the distal radius with fragments distal to the dividing line. Several studies have reported good clinical results and efficacy for fixation of distally positioned plates. However, some have observed loss of fragment reduction or instability of the distal radial joint in patients with small fragments, even after treatment with a distally positioned volar locking plate.

Even with improvements in distal radius fracture fixation, it remains difficult to stabilize and maintain the fragment in certain fracture patterns. Few studies have observed a correlation between the fracture pattern of the radiocarpal joint and DRUJ involving volar ulnar fragments and a loss of reduction in these fragments in intra-articular fractures of the distal radius[4].

Involvement of the ulnar marginal aspect of the lunate facet may not always be readily apparent on standard preoperative radiographs. Furthermore, the standard operative approach for these fractures is through the distal limb of the Henry approach,

which may limit adequate exposure to this region of the distal radius. The deforming forces of the distal volar radioulnar ligament and ulnar radiocarpal ligaments which attach to the fragment of the volar ulnar semilunar facet increase the risk of dislocation if the fragment is not adequately supported[5].

Computed tomography (CT) is useful in accurately evaluating the radiocarpal joint and disruption of the DRUJ surface in relation to the volar ulnar fragments. According to studies, it was found that fragments of the ulnar volar edge can affect the loss of reduction after surgery and the presence of displaced small volar ulnar edges is a risk factor for loss of reduction[2,4].

It is important to understand the patterns of intra-articular distal radius fractures with volar ulnar fragments distal to the dividing line and allow surgeons to select more appropriate treatments with plate fixation placed for distal radius fracture, especially to prevent loss of reduction of the radius fragment. ulnar volar border[4].

We present a case of fixation with a specific volar hook plate to approach this fragment with subsequent failure of reduction and radiocarpal dislocation.

Case report

A 30-year-old right-handed man suffered an injury to his right wrist as a result of sports trauma, diagnosed with a right distal radius fracture with prior conservative treatment attempted and referred to our department for surgical treatment 1 month post-trauma.

Anteroposterior and lateral radiographs (Fig. 1) and a coronal and axial computed tomography (Fig. 2 and Fig. 3) showed a fragment of the radial styloid, a volar ulnar fragment of the lunate fossa, with a fracture of the dorsal cortex.

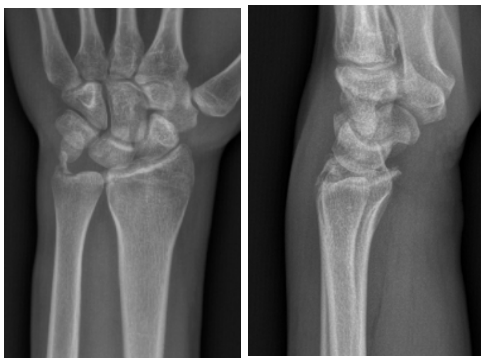

Fig. 1

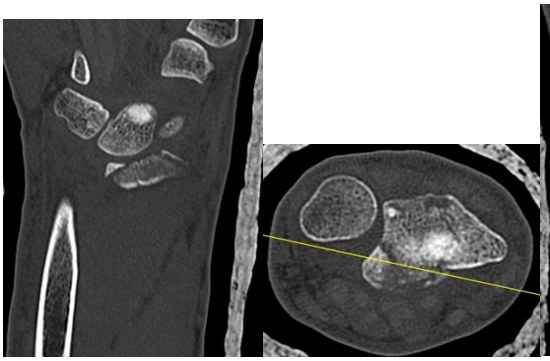

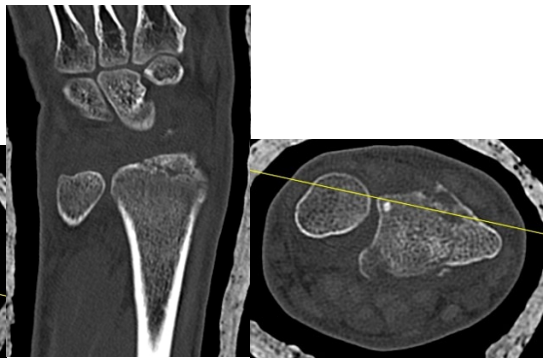

Fig. 2 Fig. 3

At 1 month after the injury, internal fixation reduction was performed using a 1.5 hook plate on the ulnar fragment and capsulodesis with a mini 2/0 anchor.

The patient was placed in a supine position with the injured arm extended on a hand table. Regional anesthesia was performed. Volar approaches with pneumatic tourniquet.

A 5 to 6 cm longitudinal skin incision is made over the PL tendon. Subcutaneous skin flaps are then elevated on the ulnar side of the PL. When the fascia is released between the PL and the flexor carpi ulnaris tendons, the forearm flexor tendons are pulled away radially and the pronator quadratus is sharply elevated from the radial side of the radius and abruptly elevated from the distal margin, taking care not to violate the radiocarpal ligaments. It is important to elevate the pronator quadratus to the most ulnar aspect of the radius and obtain excellent visualization of the entire volar ulnar fragment.

The fracture is visualized, cleaned of hematoma and debris, the edges of the fracture are clearly visualized and a reduction is obtained.

The volar ulnar corner is anatomically reduced first. (Fig. 4) It is important to understand that often the volar ulnar corner is covered with the insertions of the volar carpal ligament and all that can be seen is the fracture line. The volar carpal ligaments must be kept intact and not violated.

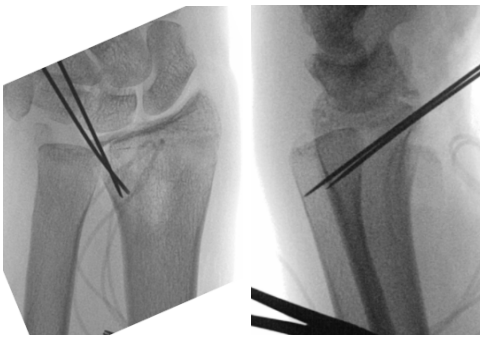

Fig. 4

The plate and inserter are held so that the teeth of the hook plate are placed approximately 1 to 2 mm from the distal edge of the radius. The axis of the hook plate is positioned parallel to the axis of the spoke[6].

Using a specifically designed guide, the distal hook path is pre-drilled with the reduced volar ulnar corner. The plate is inserted and the proximal screws are placed.

The hook plate was placed to sufficiently cover the distal portion of the bone fragment displaced to the volar side, including the volar fragment of the lunate facet. To optimally position the plate, it was placed near the distal side of the ulna at a level at which the distal locking screw is not inserted into the joint and temporarily fixed with guide pins. After skin closure, a bulky dressing and plaster orthosis are applied.

Immediately after surgery, radiographs confirmed reduction and restoration of volar carpal translation (Fig. 5), however, after 1 month of follow-up, radiographic examinations showed loss of reduction of the volar labrum of the semilunar facet with volar displacement and radiocarpal dislocation (Fig. 6). Computed tomography shows failure in fixation and consolidation of the volar ulnar fragment (Fig. 7)

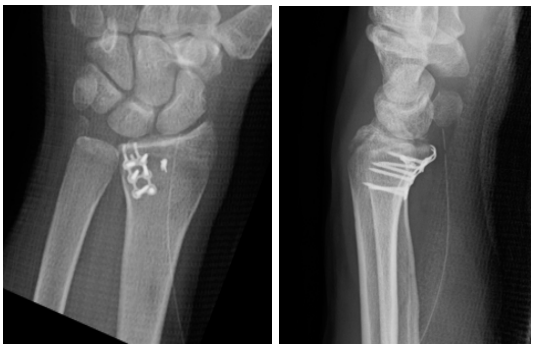

Fig. 5

Fig. 6

Fig. 7

Discussion

The treatment strategy for distal radius fractures with volar lunate facet fragment has been reported frequently, but we focused on postoperative relocation of fractures with volar displacement, which is difficult to treat.

Based on its thickness, this ligament may play a key role in maintaining stability of the radiolunar joint. A volar shear fracture with comminution creates a functional avulsion of the radiolunar ligament, which can lead to instability[2,8].

Furthermore, Harness et al insisted: "*Surgeons should pay attention to the presence of a small fragment of the ulnar lunate facet*[8]."

The problem of lunate facet fixation has become well defined, leading to greater awareness of clinical and radiographic management options. Several techniques have been described for fixing the fragments, including temporary ones with Kirschner wire, or with plates and screws.

Indications for use of the volar ulnar hook plate are fracture fragments at least 5 mm long, 7 mm wide, and 4 to 5 mm in anteroposterior dimensions. This technique is not suitable for fractures with dimensions below this minimum requirement.

The incidence of complications in the literature is varied. Previous studies have described cases of fixation failure including joint collapse, malunion, pseudarthrosis, carpal subluxation or dislocation, and wrist dysfunction.

Failure to adequately recognize and protect this volar ulnar fragment can be devastating and often results in radiocarpal subluxation that requires complex reconstructive or salvage procedures. F Harness et al. reported 7 patients who failed primary fixation. These patients were treated with reduction and internal fixation with a volar t-plate, radioscapholunate arthrodesis, scapholunate repair, and nonsurgical management.

Therefore, to avoid dorsal displacement it will be important to obtain good subchondral support on the dorsal side compared to the buttress effect, covering the volar lunate facet fragment, inferring that the difference in the buttress effect vector due to the difference in plate shape is more closely related to the new displacement of fragments after surgery rather than the need for additional fixation[8].

The reason was that the plate floated from the distal fragment due to inadequate surgical procedure, failure of radial fixation or the plate floated from the distal fragment due to loss of postoperative correction of the ulnar fragment. One hypothesis would be that the initial displacement of the fracture (for example, initial translation of the carpus in the sagittal plane and initial proximal lunate subsidence), the amount of lunate facet available for fixation (smaller volar fragments having a greater chance of failure), in addition to the position of the plate and number of screws in the lunate facet fragment, which would be significant risk factors for loss of reduction in these fractures[2].

Additionally, many dorsal dislocation fractures have been associated with damage to the pronator quadratus muscle. Therefore, it is believed that iatrogenic complications can be prevented with precise surgical procedures to minimize the loss of postoperative correction[9].

Several studies have demonstrated the importance of recognizing and properly fixing volar shear fractures of the distal radius to avoid joint incongruity.

Combining techniques that allow fixation at small margins volar fragments can provide better rotational stability, neutralize tensile forces and complement the buttress effect of the plate.

The ability to effectively treat the fracture with realignment and stable fixation appears to be based on several factors. The amount of time that passed between the time of recognition and the time of repeat surgery will certainly be a factor. Additionally, the size of the fragment displacement may require more than just support with the ulnar end of a T-shaped plate. Consideration should be given to additional support of the fragment with tensioned wire technique as described by Chin and Jupiter, with wires Kirschner wire on the left close to the cortical edge and prominent on the dorsal side for later recovery, with a radiolunar Kirschner wire, or with an external fixator[10,11].

In conclusion, when evaluating volar shear fractures, attention should be paid to the presence of a small fragment of the ulnar lunate facet. When standard radiographs reveal the possibility of such a fragment, two-dimensional and even three-dimensional computed tomography may well provide important additional information preoperatively. Second, when faced with a more complex volar shear fracture, the surgeon may consider an ulnar base incision between the ulnar artery and nerve and flexor tendons to allow direct access to the volar ulnar corner of the radius. Finally, adjunctive fixation of the fragment with a smaller implant placed more distally, or temporary external fixation, may prevent displacement of the fragment from the volar lunar facet[5,12].

Future studies on this difficult subset of fractures using pre- and postoperative computed tomography to compare outcomes of patients treated with supplemental fixation and improve assessment will be beneficial[7].

Bibliography

1- Maureen A O'Shaughnessy, Alexander Y Shin, Sanjeev Kakar. Volar Marginal Rim Fracture Fixation With Volar Fragment-Specific Hook Plate Fixation. J Hand Surg Am. 2015 Aug;40(8):1563-70. doi: 10.1016/j.jhsa.2015.04.021. Epub 2015 Jun 10.

2- Ashok S Gavaskar, S Parthasarathy, J Balamurugan, Rufus V Raj, Raja Anurag, D Gopinath. Volar hook plate stabilization of volar marginal fragments in intra-articular distal radius fractures. Injury. 2021 Jan;52(1):85-89. doi: 10.1016/j.injury.2020.10.004. Epub 2020 Oct 6.

3- Kenta Minato, Masataka Yasuda, Shogo Shibata A Loop-Wiring Technique for Volarly Displaced Distal Radius Fractures With Small Thin Volar Marginal Fragments. J Hand Surg Am. 2020 Mar;45(3):261.e1-261.e7. doi: 10.1016/j.jhsa.2019.10.022. Epub 2019 Dec 16.

4- Mitsuhiko Nanno, Norie Kodera, Yuji Tomori, Shinro Takai. Volar Locking Plate Fixation for Intra-Articular Distal Radius Fractures with Volar Lunate Facet Fragments Distal to the Watershed Line. J Nippon Med Sch. 2020 Mar 11;87(1):24-31. doi: 10.1272/jnms.JNMS.2020_87-106. Epub 2019 Oct 15.

5- Rohit Garg, Chaitanya S Mudgal. When a volar locking plate is not the right choice in fractures of the distal radius: Case based technical considerations. J Clin Orthop Trauma. 2020 Jul-Aug;11(4):542-553. doi: 10.1016/j.jcot.2020.05.040. Epub 2020 Jun 8.

6- Adam J Bakker [1], Alexander Y Shin. Fragment-specific volar hook plate for volar marginal rim fractures. Tech Hand Up Extrem Surg. 2014 Mar;18(1):56-60. doi:10.1097/BTH.0000000000000038.

7- John D Beck, Neil G Harness, Hillard T Spencer. Volar plate fixation failure for volar shearing distal radius fractures with small lunate facet fragments. J Hand Surg Am. 2014 Apr;39(4):670-8. doi: 10.1016/j.jhsa.2014.01.006. Epub 2014 Mar 6.

8- Kiyohito Naito, Yoichi Sugiyama, Mayuko Kinoshita, Hiroyuki Obata, Kenji Goto, Nana Nagura, Yoshiyuki Iwase, Osamu Obayashi, Kazuo Kaneko. Functional Outcomes in Volar-Displaced Distal Radius Fractures Patients with Marginal Rim Fragment Treated by Volar Distal Locking Plates. J Hand

Microsurg. 2019 Aug;11(2):100-105. doi: 10.1055/s-0038-1675245. Epub 2018 Dec 28.

9- Hiroyuki Obata, Kiyohito Naito, Ayaka Kaneko, Keniji Goto, Yoichi Sugiyama, Nana Nagura, So Kawakita, Yoshiyuki Iwase, Kazuo Kaneko. Clinical Outcomes in Distal Radius Fractures Accompanied by Volar Lunate Facet Fragments: A Comparison between Dorsal and Volar Displaced Fractures. J Hand Surg Asian Pac Vol. 2020 Dec;25(4):417-422. doi: 10.1142/S2424835520500447.

10- Yoichi Sugiyama, Kiyohito Naito, Hiroyuki Obata, Mayuko Kinoshita, Kentaro Aritomi, Kazuo Kaneko, Osamu Obayashi. Devising for a distal radius fracture fixation focus on the intra-articular volar dislocated fragment. Ann Med Surg (Lond). 2016 Apr 14:8:1-5. doi: 10.1016/j.amsu.2016.04.003. eCollection 2016 Jun.

11- Daniel Tordjman, Richard M Hinds, Omri Ayalon, S Steven Yang, John T Capo. Volar-Ulnar Approach for Fixation of the Volar Lunate Facet Fragment in Distal Radius Fractures: A Technical Tip. J Hand Surg Am. 2016 Dec;41(12):e491-e500. doi: 10.1016/j.jhsa.2016.09.007.

12- Neil G Harness, Jesse B Jupiter, Jorge L Orbay, Keith B Raskin, Diego L Fernandez. Loss of fixation of the volar lunate facet fragment in fractures of the distal part of the radius. J Bone Joint Surg Am. 2004 Sep;86(9):1900-8. doi: 10.2106/00004623-200409000-00007.