# Open Reduction and Internal Fixation of a Type II Wagstaffe Fracture: A Case Report

Martim C. Pinto[1], Alexandre Leme Godoy-Santos[2]

1- Department of Orthopedic Surgery, Hospital Vila Franca de Xira, Vila Franca de Xira, Portugal.

2- Hospital Israelita Albert Einstein, Av. Albert Einstein, 627 - Jardim Leonor, São Paulo - SP, 05652-900, Brasil; Faculdade de Medicina, USP, R. Dr. Ovídio Pires de Campos, 333 - Cerqueira César, São Paulo - SP, 05403-010, Brasil.

**Keywords:** Ankle fracture, Wagstaffe type II fracture, Anterior inferior tibiofibular ligament, Open reduction internal fixation

**Summary**

In 1875, Wagstaffe reported avulsed fragments of the distal fibula associated with fractures to the ankle. Type II describes a fracture-avulsion of the anterior inferior tibiofibular ligament, from the fibula, combined with a fibular fracture. These fractures entail a bony injury to the anterior syndesmosis, that may deem a syndesmotic instability if not properly fixed. We report the case of a 42-year-old male that suffered an ankle fracture while landing a skateboard maneuver. Interestingly, the patient was submitted to an open reduction and internal fixation with an anterior plate to fix the Wagstaffe fragment and a posterior plate to fix the fibula fracture. At 6 months postoperatively, the patient reported no pain or stiffness and returned to skateboarding.

## Introduction

Lateral malleolus fractures remain one of the most treated fractures by orthopedic surgeons. Epidemiologically, they represent approximately half of all ankle fractures.[1] It is well emphasized in the literature, that appropriate reduction and stability of the ankle mortise is essential to avoid irreversible post-traumatic ankle osteoarthritis and lead to long-term good functional results. Anterior inferior tibiofibular ligament (AITFL) avulsion fractures are a significant concern in the context of ankle fractures, estimated to accompany approximately 25% of all ankle fractures.[2] The integrity of the distal tibiofibular syndesmosis plays a pivotal role in maintaining the stability of the ankle joint and, consequently, weight-bearing functionality. As a result, the management of syndesmotic instability following ankle fracture fixation is crucial for achieving optimal functional outcomes and reducing the risk of post-traumatic ankle arthritis.[3]

Interestingly, the Wagstaffe fracture diagnosis itself may impose a challenge, as simple ankle x-rays (anteroposterior, mortise and lateral view) have a moderate to poor sensitivity missing 30 to 50% of the beforementioned fractures.[4–6] That said, a "simple" lateral malleolus fracture may impose the need for a CT-scan.[4]

The preferred method for stabilizing the ankle syndesmosis has long been the use of screws, although the exact techniques and approaches have remained a subject of debate. Syndesmotic screw fixation, while effective in many cases, is not without its drawbacks, including concerns regarding malreduction, screw-related complications, and the necessity for future screw removal.[7,8] Consequently, alternative fixation methods, such as suture button fixation, and bioabsorbable screws, have emerged as potential alternatives to the traditional syndesmotic screw fixation.

At the core of syndesmotic stability lies the AITFL, one of the four critical ligaments of the distal tibiofibular syndesmosis. It is situated in order to resist lateral

displacement of the distal fibula, is particularly vulnerable to external rotational forces, making it susceptible to rupture or avulsion fractures at the fibula or tibia attachment sites.[9,10] While some literature has reported positive outcomes with the reduction and fixation of AITFL avulsion fractures, the evidence supporting this approach as an effective mean of stabilizing syndesmotic injuries remains limited. Since not all AITFL injuries are associated with syndesmotic instability and fixation of a Wagstaffe fracture doesn't always obliviate additional syndesmotic stabilization.[2,11] On the other hand, to our understanding, fixation of the anterior syndesmosis should always increase syndesmotic stability, to some extent.

In summary, the management of distal tibiofibular syndesmotic injuries, including AITFL avulsion fractures and associated lateral malleolar fractures, poses challenges that warrant ongoing exploration and research. This case report aims to shed light on Wagstaffe fragment surgical fixation.

**Case Presentation**

A healthy 42-year-old male was riding his skateboard and landed a maneuver unproperly causing a moderate energy torsional trauma to his left ankle. Fortunately, only his ankle was affected, and he had no associated injuries. He couldn't bear weight immediately, forcing him to search for medical care.

Physical examination of his left lower leg denoted a substantial swelling, hematoma around the lateral malleolus and pain on palpation of the medial malleolus. There were no wounds, no pain on palpation and there was normal range of motion of the hindfoot, midfoot or forefoot. His dorsalis pedis and posterior tibial pulses were both present, and capillary refill time on his toes was brisk. Sensibility throughout his

left foot was intact, with integral superficial peroneal and sural nerves. Further examination of his left knee and thigh revealed no abnormalities.

Following X-ray, a Weber B fibular fracture was identified and a computed tomography (CT) scan was deemed necessary for further investigation and surgical planning (Figure 1). On CT scan, a Wagstaffe type II fracture was located (Figure 2 and 3).

Figure 1 – Ankle X-rays – Anteroposterior (left), mortise (middle) and lateral (right)

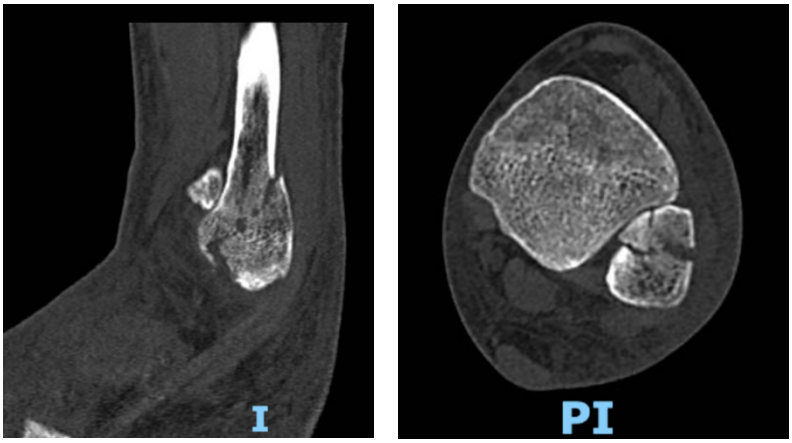


Figure 2 – Ankle CT scan – Sagittal cut (left) and Axial cut (right)

Figure 3 – Ankle CT scan 3D reconstruction. Green arrows showing the Wagstaffe fragment

Due to good soft tissue conditions, it was possible to operate the patient on the third day of admission. On the operating room, the patient was positioned supine, with a bump under the left hip, was scrubbed and the surgical fields were put standardly.

A lateral approach to the fibula was used and a careful dissection was performed, the periosteum was elevated, and the fracture exposed. Subsequently, the fracture was reduced using K-wires and reduction clamps and appropriate reduction was confirmed under fluoroscopy. The fibula fracture was fixed with a two locking plate construct: an anteromedial 2.4 mm and a posterolateral 2.7 mm Aptus Foot from Medartis (Basel, Switzerland). Syndesmosis was stressed under fluoroscopy using the hook test and it was deemed stable. The subcutaneous and skin layers were closed with vycril and nylon sutures, respectively.

Following surgery, the patient was advised to remain non-weightbearing for six weeks, during which he used a soft tissue dressing. To mitigate the risk of venous thromboembolism, he received a daily dose of 40 mg of enoxaparin as prophylaxis. After the six-week period, the patient progressed to partial weightbearing, utilizing a moon boot. He was able to start physical therapy 4 weeks postoperatively.

At the four-month mark post-surgery, the patient achieved both clinical and radiographic union (figure 3) with range of motion comparable to the contralateral side (figure 4). Six months after surgery he was able to go back to skateboarding.

Figure 4 – Ankle X-ray and Ankle CT 4 months after surgery, showing complete union

Figure 5 – Clinical images at 6 months after surgery showing full range of motion.

**Discussion**

This 42-year-old male is not the typical lateral malleolar fracture. This case highlights several important aspects of managing lateral malleolus fractures for a maximized and appropriate outcome.

A Wagstaffe fragment increases the complexity of a lateral malleolus fracture. Disregarding the fixation of this fragment may result in unstable distal tibiofibular joint and chronic ankle joint pain caused by impingement of the avulsed fragment.[12] The interrogation usually stays on the actual need for fixation and method used, as there is controversy related to avulsion fracture fixation.

It appears that the size of the avulsed fragment affects how it is fixed. Diallo and colleagues conducted a case series on lateral ankle avulsion fractures (anterior talofibular ligament and calcaneofibular ligament) with ten avulsion fractures that were 5 mm or larger in size. They used screw fixation resulting in rotational stability and it was efficient in restoring function and stability.[13] On average, the length of the Wagstaffe fragment has a size of 17.88 mm[14] which facilitates its fixation, when comparing to other avulsion fractures of smaller size.

On the other hand, nonunion of these fractures, may result in chronic ankle instability, with reports perceiving a non-union rate of around 35%.[15–17]

A recent anatomic cadaveric study performed by Fisher et al. showed that the AITFL fibular origin was both larger and more distal than the Wagstaffe fracture fragments, suggesting that a ligamentous failure also must occur to result in syndesmotic instability.[14] Additionally, it was also proposed that the size of the fracture fragment did not seem to be related to syndesmotic instability during testing. [14] Only a few studies have revealed good clinical outcomes after AITFL avulsion fracture reduction and fixation.[6,12,18] A more recent study observed the radiographic and functional outcomes of anatomical reduction and fixation of anterior inferior tibiofibular ligament avulsion fracture without syndesmotic screw fixation in rotational ankle fracture and noticed that more than 80% of patients obliviated the need for syndesmotic screw fixation.[6]

We suggest that fixing a Wagstaffe type II fracture with with a two locking plate construct, an anteromedial 2.4 mm and a posterolateral 2.7 mm Aptus Foot from Medartis (Basel, Switzerland) is a suitable method and may yield good functional outcomes.

1. Aiyer AA, Zachwieja EC, Lawrie CM, Kaplan JRM. Management of Isolated Lateral Malleolus Fractures. *Journal of the American Academy of Orthopaedic Surgeons*. 2019;27(2):50-59. doi:10.5435/JAAOS-D-17-00417
2. Birnie MFN, van Schilt KLJ, Sanders FRK, Kloen P, Schepers T. Anterior inferior tibiofibular ligament avulsion fractures in operatively treated ankle fractures: a retrospective analysis. *Arch Orthop Trauma Surg*. 2019;139(6):787-793. doi:10.1007/S00402-019-03138-2
3. van Zuuren WJ, Schepers T, Beumer A, Sierevelt I, van Noort A, van den Bekerom MPJ. Acute syndesmotic instability in ankle fractures: A review. *Foot and Ankle Surgery*. 2017;23(3):135-141. doi:10.1016/J.FAS.2016.04.001
4. Haapamaki V V., Kiuru MJ, Koskinen SK. Ankle and foot injuries: Analysis of MDCT findings. *American Journal of Roentgenology*. 2004;183(3):615-622. doi:10.2214/AJR.183.3.1830615/ASSET/IMAGES/09_03_0335_04D.JPEG
5. Pankovich AM. Fractures of the fibula at the distal tibiofibular syndesmosis. *Clin Orthop Relat Res*. 1979;143:138-147. doi:10.1097/00003086-197909000-00021
6. Bae KJ, Kang SB, Kim J, Lee J, Go TW. Reduction and fixation of anterior inferior tibiofibular ligament avulsion fracture without syndesmotic screw fixation in rotational ankle fracture. *J Int Med Res*. 2020;48(4):1-15. doi:10.1177/0300060519882550
7. Miller AN, Barei DP, Iaquinto JM, Ledoux WR, Beingessner DM. Iatrogenic syndesmosis malreduction via clamp and screw placement. *J Orthop Trauma*. 2013;27(2):100-106. doi:10.1097/BOT.0B013E31825197CB
8. Gardner MJ, Demetrakopoulos D, Briggs SM, Helfet DL, Lorich DG. Malreduction of the Tibiofibular Syndesmosis in Ankle Fractures. *http://dx.doi.org/101177/107110070602701005*. 2006;27(10):788-792. doi:10.1177/107110070602701005
9. Yuen CP, Lui TH. Distal Tibiofibular Syndesmosis: Anatomy, Biomechanics, Injury and Management. *Open Orthop J*. 2017;11(1):670-677. doi:10.2174/1874325001711010670
10. Ogilvie-Harris DJ, Reed SC. Disruption of the ankle syndesmosis: diagnosis and treatment by arthroscopic surgery. *Arthroscopy*. 1994;10(5):561-568. doi:10.1016/S0749-8063(05)80015-5
11. Bae KJ, Kang SB, Kim J, Lee J, Go TW. Reduction and fixation of anterior inferior tibiofibular ligament avulsion fracture without syndesmotic screw fixation in rotational ankle fracture. *Journal of International Medical Research*. 2019;48(4). doi:10.1177/0300060519882550
12. Park JW, Kim SK, Hong JS, Park JH. Anterior tibiofibular ligament avulsion fracture in weber type B lateral malleolar fracture. *J Trauma*. 2002;52(4):655-659. doi:10.1097/00005373-200204000-00007

13. Diallo J, Wagener J, Schweizer C, Lang TH, Ruiz R, Hintermann B. Intraoperative Findings of Lateral Ligament Avulsion Fractures and Outcome After Refixation to the Fibula. *Foot Ankle Int*. 2018;39(6):669-673. doi:10.1177/1071100718760273/SUPPL_FILE/FAI760273-ICMJE.PDF
14. Fisher A, Bond A, Philpott MDG, et al. The anatomy of the anterior inferior tibiofibular ligament and its relationship with the Wagstaffe fracture. *Foot and Ankle Surgery*. 2021;27(3):291-295. doi:10.1016/j.fas.2021.01.003
15. El Ashry SR, El Gamal TA, Platt SR. Atypical Chronic Ankle Instability in a Pediatric Population Secondary to Distal Fibula Avulsion Fracture Nonunion. *Journal of Foot and Ankle Surgery*. 2017;56(1):148-152. doi:10.1053/j.jfas.2016.04.018
16. Yamaguchi S, Akagi R, Kimura S, et al. Avulsion fracture of the distal fibula is associated with recurrent sprain after ankle sprain in children. *Knee Surgery, Sports Traumatology, Arthroscopy*. 2019;27(9):2774-2780. doi:10.1007/S00167-018-5055-7/TABLES/3
17. Haraguchi N, Toga H, Shiba N, Kato F. Avulsion fracture of the lateral ankle ligament complex in severe inversion injury: Incidence and clinical outcome. *American Journal of Sports Medicine*. 2007;35(7):1144-1152. doi:10.1177/0363546507299531/ASSET/IMAGES/LARGE/10.1177_0363546507299531-FIG5.JPEG
18. Chung HJ, Bae SY, Kim MY. Treatment of Anteroinferior Tibiofibular Ligament Avulsion Fracture Accompanied with Ankle Fracture. *Journal of Korean Foot and Ankle Society*. 2014;15(1):13-17. Accessed September 25, 2023. http://www.koreamed.org/SearchBasic.php?RID=1722560