Synovial plica: Cause of undiagnosed chronic ulnar mid-carpal pain

Author: Salvador David Rogel, MD. Climba (Buenos Aires, Argentina)

This prospective study was carried out with patients operated in climba between September 2021 and July 2022.

ABSTRACT

Chronic wrist pain represents a challenge both in diagnosis and in its treatment, since there are many pathologies that can cause the same symptom. The presence of a synovial plica could be a frequent cause of pain, and usually it may not generate symptoms or trigger an episode of painful synovitis after an injury. The use of wrist arthroscopy both as a method to diagnose by visualizing small wrist joints as well as a treatment for chronic wrist pain has become widespread.

The hypothesis of this investigation is based on the fact that there is a small number of patients with this chronic ulnar midcarpal pain syndrome, where a clear diagnosis is not found. In some cases, during the arthoscopy procedure, a lunotriquetal synovial plica can be detected as a clear origin of the chronic pain.

The aim of this work will be to prospectively evaluate the clinical-functional results of those patients who had undergone surgery due to a chronic ulnar midcarpal pain whose cause is a synovial plica. A prospective analysis will be carried out for two years in patients undergoing wrist arthroscopy, with a diagnosis of synovial plica and absence of other pathologies on MRI.

Patients will be treated with diagnostic and therapeutic arthroscopy with a follow-up period of six months. Variables will be age, gender, time of pain, Quick DASH score, ulnar deviation and extension maneuver, and ROM.

INTRODUCTION

Chronic wrist pain represents a challenge both in diagnosis and in its treatment, since there are many pathologies that can cause the same symptom. [1] Chronic dorsal wrist pain in hyperextension is also called dorsal wrist syndrome. [2] In addition this chronic pains could develop in the knee or elbow, as the presence of a synovial plica could be a frequent cause of pain, and usually it may not generate symptoms or trigger an episode of painful synovitis after an injury. [3-5

Surgeons question themselves the existence of dorsal impingement as a pathology by definition; those who defend it theorize that its etiology could be due to acute trauma or chronic repetitive micro-trauma, and sometimes include partial avulsions of the dorsal wrist ligaments. [6,7] In sports practice, high forces transmitted through a closed fist and consequently to the wrist, could generate this chronic condition. During medical examination, it is common to observe an X-ray without detectable abnormalities. [8-12] Evaluation of chronic wrist pain is challenging, and a medical interview and physical examination are essential. [1]

In the case of chronic wrist pain, triangular fibrocartilage complex injury, scapholunate ligament injury, lunotriquetral ligament injury, chondral injuries, synovial pathologies, septic arthritis, inflammatory arthropathies, synovial osteochondromatosis, pigmented villonodularnovitis should be dismissed through scans. The use of wrist arthroscopy both as a method to diagnose by visualizing small wrist joints as well as a treatment for chronic wrist pain has become widespread. Furthermore, this technique is used to evaluate wrist instabilities, intrinsic ligaments, soft tissue injuries, tumors, and fractures, where complications occur in less than 5% of cases and commonly involve nerve injuries at the surgical site. [14]

The hypothesis of this investigation is based on the fact that there is a small number of patients with this chronic ulnar midcarpal pain syndrome, where a clear diagnosis is not found and, after months of non-surgical treatment, positive results are not achieved. Due to its intra-articular origin, arthroscopy could help with the diagnosis and treatment of this syndrome in a single intervention. In some cases, during the arthoscopy procedure, a lunotriquetal synovial plica can be detected as a clear origin of the chronic pain.

The aim of this work will be to prospectively evaluate the clinical-functional results of those patients who had undergone surgery due to a chronic ulnar midcarpal pain whose cause is a synovial plica.

MATERIAL AND METHODS

As an observer, a prospective analysis was carried out for two years in patients treated with arthroscopy, with a diagnosis of synovial plica and an absence of other pathologies in the MRI. This analysis took place in Teknon Medical Center in Barcelona, Spain and in CLIMBA trauma center in Buenos Aires, Argentina from January 2021 to January 2023.

The study population were those subjects who met the inclusion criteria: patients with closing physes and a diagnosis of isolated synovial plica with non-demonstrable adjacent pathologies in the MRI scan, after being treated with non-surgical treatment without satisfactory results. Patients were treated with diagnostic and therapeutic arthroscopy.

Exclusion criteria:

- Associated traumatic pathologies.
- Comorbidities: diabetes, rheumatoid arthritis, connective disorders.

VARIABLES

Age: Was measured in years.

Gender: Was categorized as male or female.

Time of pain: Was measured in months. That is to say, the time in months with non-stop wrist pain until the day of arthroscopy.

QuickDASH questionnaire: The QuickDASH score before the surgery, and 3 months after surgery.

Painful maneuver: The absence or presence of pain before passive ulnar deviation maneuvers and wrist flexion and extension.

ROM: Was measured in degrees. The maximum active-extension capacity between the healthy and affected wrist was compared. It was evaluated with a goniometer.

Synovial plica diagnosis: The presence of chronic ulnar midcarpal pain, with non-demonstrable adjacent wrist pathologies in the MRI scan, after being treated with non-surgical treatment without satisfactory results.

SURGERY TECHNIQUE

The patient was placed in supine position, and a sterile field was setted around the upper limb that was treated. Also, a temporary tourniquet was used at a pressure of 240 mmhg and, by means of a traction tower, the wrist was placed at a traction of 35N for dry arthroscopic technique.

Radio-carpal and midcarpal arthroscopic portals were performed. First, 1 cm skin incisions were made in portals 3-4 and 6R, and in a second step, ulnar and radial midcarpal portals were executed.

Upon entering the radiocarpal joint with the camera, a diagnostic exploration was carried out. The following were examined: (1) the articular chondral surfaces, (2) the state and quality of the ligaments, (3) the synovial tissue, and (4) the presence of plicas.

A synovectomy of the anomalous or congestive synovial tissue that invaded the articular surface up to the capsular plane was performed, without affecting it.

In a second stage, after leaving the radiocarpal joint, the midcarpal portals were made and the midcarpal joint was explored to carry out the same procedure described above.

The portals were sutured and the wrist was immobilized for two weeks with a splint. Rehabilitation work with an occupational hand therapy specialist was restarted after 2 weeks.

CASE REPORT

Radiocarpal and midcarpal arthroscopic exploration was performed on the patients and, after confirming the diagnosis, the midcarpal plica was shaved. They underwent the same surgery between September 2021 and July 2022. The quickDASH score was used a few minutes before entering the surgery and 3 months after it. The ROM measurement in flexion and extension was also taken before the surgery. The rest of the variables were taken in medical visits.

	Age	**Gender**	**Time of pain**	**QuickDASH Score**	**Painful maneuver**	**ROM extension healthy/altered**	**Diagnosis of synovial plica**	**QuickDASH Score Postop**
1	25	Male	6 months	51	Present	80/80	Yes	9
2	22	Male	6 months	33	Present	80/80	Yes	7
3	15	Women	9 months	12	Present	80	Yes	0
4	55	Women	12 months	61	Present	90/85	Yes	7
5	32	Male	6 months	55	Present	90/85	Yes	10

Table 1. Patients and results.

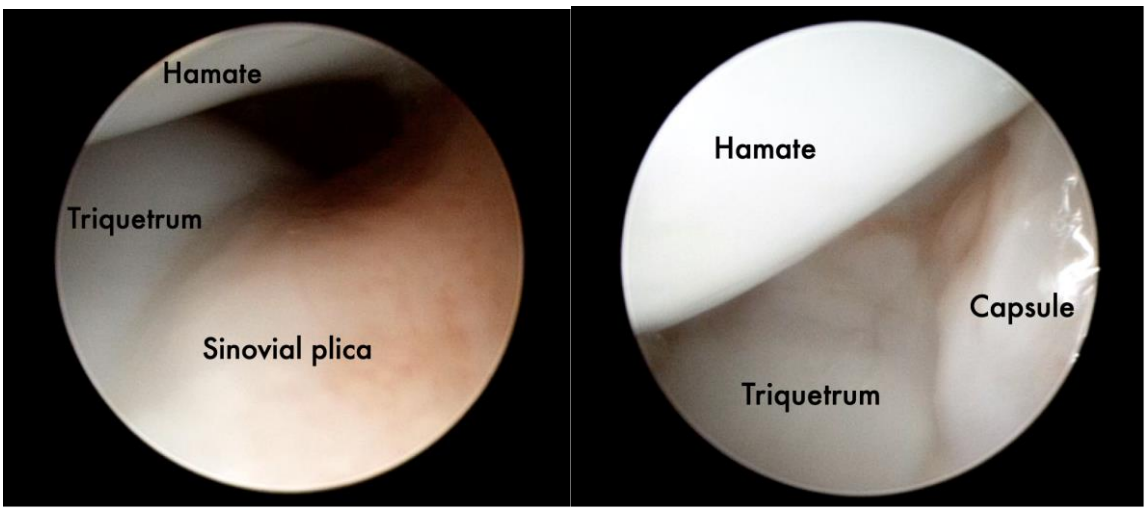

Figure 1-2: In the first image, it can be seen how the synovial plica invades 50% of the triquetrum load-bearing surface and, after shaving, it completely disappears, leaving the capsule denuded without midcarpal invasion.

DISCUSSION

The arthroscopic approach is a powerful tool that helps to elucidate clinically and imaging inconclusive diagnoses. The possibility of performing a minimally invasive diagnosis with minor morbidity makes it even more valuable, since today there are no prospective studies on synovial plica in the wrist. The results were remarkable, taking into account the considerable drop in the QuickDASH score. The ROM did not demonstrate post-surgical changes in any of the cases, although it did show a greater load tolerance. The limitation of the work was to find a more representative number of patients with this undiagnosed pain, since a large number of patients tolerate pain or discomfort in daily activities, others improve with non-surgical treatment, and others are never correctly diagnosed. An advantage that can be seen after surgery is that in patients who have undergone rehabilitation work for a long time, the complication rate is less than 5% [(15)], and rehabilitation work is usually more successful. The arthroscopic technique is complex, but once triangulation is mastered, it can be easily reproduced by an inexperienced arthrocopist. The results showed that all the patients who did not recover after 6 months of non-surgical treatment had a favorable post-surgical outcome. In conclusion, the diagnosis of synovial plica for the treatment of midcarpal pain does not have to be carried out arthroscopically, but it is an option to consider in patients who did not have a positive response to prolonged rehabilitation work or could not be diagnosed by imaging.

Conflicts of interest: The author declares that he does not have conflicts of interest related to the subject matter or materials discussed in this article.

BIBLIOGRAPHY

1) Nagle DJ. Evaluation of chronic wrist pain. J Am Acad Orthop Surg, 2000, January. Volume 8, *p*. 45.
2) Weinzweig J, Watson HK. Dorsal wrist syndrome repair. Watson HK, Weinzweig J, editors. Philadelphia. 2001. *p*. 829–31.
3) Ruch DS, Papadonikolakis A, Campolattaro RM, The posterolateral plica: a cause of refractory lateral elbow pain, J Shoulder Elbow Surg. 2006, May, *p*. 367-370.
4) Maffulli N, Testa V, Capasso G. Mediopatellar synovial plica of the knee in athletes: results of arthroscopic treatment. Med Sci Sports Exerc. Italy. 1993, March *p*. 985-988.
5) Duparc F, Putz R, Michot C, Muller JM, Freger P. The synovial fold of the humeroradial joint: anatomical and histological features, and clinical relevance in lateral epicondylalgia of the elbow. Surg Radiol Anat, France: 2002, july. *p*. 302-307
6) Srinivasan R, Wysocki R, Jain D, Richard M, Leversedge F, Ruch D. Arthroscopic treatment of dorsal wrist syndrome. Arthroscopy. 2013. Volume 29, *p* 25.
7) Jain K, Singh R. Short-term result of arthroscopic synovial excision for dorsal wrist pain in hyperextension associated with synovial hypertrophy. Singapore Med J. 2014. Volume 55, *p* 547-549.
8) Joch W, Fritche P, Krause I. Biomechanical analysis of boxing. In: Fidelius K, Kdzior K, eds. Biomechanics VII-A. Baltimore, MD: University Park Press. 1981. *p*. 343-349.
9) Smith Ms. Physiological profile of senior and junior England international amateur boxers. J Sports Sci. 2006. Volume 5, *p* 74-89.
10) Smith MS, Dyson RJ, Hale T, Janaway L. Development of a boxing dynamometer and its punch force dis-crimination efficacy. J Sports Sci. 2000. Volume 18, *p* 445-450.
11) Walilko TJ, Viano DC, Bir CA. Biomechanics of the head for Olympic boxer punches to the face. Br J Sports Med. 2005. Volume 39. *p* 710-719.
12) Wollstein R, Watson HK, Wear-Maggitti K, Schmidt S, Carlson L. Surgical technique for the treatment of radial wrist pain. Scand J Plast Reconstr Surg Hand Surg. 2008. Volume 42, *p* 149–152.
13) Moriatis Wolf J, Dukas A. Advances in Wrist Arthroscopy. 2019 March Volume 39, *p* 447-448.
14) Bianco M, Sanna N, Bucari S, Fabiano C, Palmieri V, Zeppilli P. Female boxing in Italy: 2002-2007 report. Br J Sports Med. Italy. 2011. Volume 45, *p* 563-570.
15) Danielle H. Rochlin. Prevalence of Ganglion Cyst Formation After Wrist Arthroscopy: A Retrospective Longitudinal Analysis of 2420 Patients.2020, American Association for Hand Surgery. HAND 1–6.