The BioPro thumb carpo-metacarpal hemi-arthroplasty: a case report

Key words:
Total trapeziometacarpal osteoarthritis, trapeziometacarpal joint replacement, thumb carpometacarpal arthroplasty

Introduction

Arthritis at the thumb carpometacarpal joint (CMCJ) is common, affecting 33% of women and 19% of men, but is not associated with prior injury, or occupation [1,2]. Excising the trapezium, utilising a haematoma arthroplasty, first described in 1949 provides good pain relief and function [2]. Concerns with thumb joint instability led to the addition of a ligament reconstruction and tendon interposition (LRTI), but work by Davis et al showed that this did not confer a significant clinical improvement [3,4]. Despite this, LRTI has remained a common additional procedure to a trapeziectomy. Patients return to most activity by three months after a trapeziectomy, although some patients can take much longer. In addition, concerns remain that after a trapeziectomy, there can be persistent weakness in thumb pinch and grip, thumb height shortening and potential for thumb metacarpal collapse into the excised trapezium's space causing pain and adduction deformity. To address this, arthroplasty of the thumb CMCJ was introduced.

Thumb CMCJ arthroplasty may offer a quicker recovery and better grip strength [5], leading to more normal function for higher demand patients. Initially, silicone spacers were used in the 1960s, but suffered early failure and extrusion. Monoblock polyethylene on metal cemented implants were later used in the 1970s however since 1995, modular anatomical uncemented implants have been introduced and since 2012, dual mobility polyethylene liners have been used [6,7]. Evidence is still emerging as to whether trapeziectomy or arthroplasty provides better outcomes for thumb CMCJ arthritis and head-to-head randomised control trials between the two interventions have not yet been conducted as thumb CMCJ arthroplasty remains an uncommon treatment. In addition, outcomes for thumb arthroplasty have not yet been published as dual mobility implants are still new and are not routinely submitted to national joint registries, such as the UK NJR, although are part of the British Society for Surgery of the Hand (BSSH) outcomes registry. Since 2015, thumb CMCJ arthroplasty has increased in Belgium and elsewhere in Europe, likely in response to newer prosthetic designs [8,9].
Here, we present a case report of a newer option for hemi-arthroplasty of the thumb CMCJ.

Case presentation

A 74-year-old man presented with radial sided thumb pain in his left non-dominant extremity. His pain was refractory to splinting and oral analgesics and he declined injections as they had been previously ineffective elsewhere. He wished to consider surgical interventions. He had no allergies and had controlled hypertension. Radiographs demonstrated osteoarthritis with joint narrowing and loss of height at the thumb carpo-metacarpal joint (CMC) (figure 4). However, the ST joint was preserved, and he had adequate trapezium depth to consider an arthroplasty (minimum 8mm). Importantly, he also had SLAC wrist with radial styloid arthrosis on his radiograph.
On examination, he had squaring of the thumb base, was neurologically intact and had normal wrist movements including dart throwers movement. His pain was reproduced on grind test of the thumb CMCJ but was pain-free more proximally. In addition, he had no central or radial column tenderness and Kirk-Watson test did not reproduce his pain, helping to discern between the two radial sided pathologies of thumb CMCJ arthritis and radial styloid arthritis.
After exhausting non-surgical options and being counselled to his options, he decided on thumb CMCJ arthroplasty, to preserve thumb height and pinch and grip strength. As there was operating capacity, he was offered surgery the following day.

Management and outcome

The patient underwent a thumb CMCJ BioPro hemi-arthroplasty as an ambulatory procedure. The patient was brought on the morning of surgery to an ambulatory surgical centre (ASC) and after re-confirming consent, underwent a regional block and sedation. They were positioned supine, with the arm on a radiolucent arm board (figure 5). A dorsal incision centred over the thumb carpo-metacarpal joint, taking care to avoid branches of the superficial radial nerve. EPB was mobilised and a longitudinal capsulotomy was made. The metacarpal neck was exposed, and a transverse cut with a saw used to resect the articular surface. Osteophytes were excised with a rongeur, with particular attention for any deep, hidden osteophytes. A burr created a central cavity in the trapezium, ensuring that the cortical wall was not breached. Then broaches were used to ream the metacarpal canal and provide a seat for the head of the implant in the trapezium. A trial implant was inserted, and position assessed under fluoroscopy (figure 6). When satisfactory, this was replaced with the non-cemented implant and reduced, with confirmation of stability (figure 7,8). The capsule and dermis were closed in layers with 4-0 vicryl and an occlusive non-absorbent dressing applied, with a bulky soft bandage and sling (due to the regional block).

The patient was discharged out of the facility from the recovery area of the ASC. They were reviewed in clinic the day after surgery and began early hand therapy. They had sustained hand therapy, focusing on improving grip and pinch strength (figure 9). The patient reported that pain relief was immediate after surgery and that his range of motion and strength was excellent. The patient completed hand therapy over 3-months, with discharge from care at the 3-month clinic review.

Discussion of case

Increasingly, patients have high expectations of function as retirement ages rise. This case has taught me that the indications for arthroplasty are for high or moderate demand patients. Arthrodesis is indicated for young manual workers and a trapeziectomy for older (or physiologically older) patients with lower functional demands. Outcomes for thumb CMCJ are good in the short term, but longer-term outcomes are yet to be published. If revision of the implant becomes necessary due to implant loosening, it can be revised to a trapeziectomy, or new implants may be inserted.

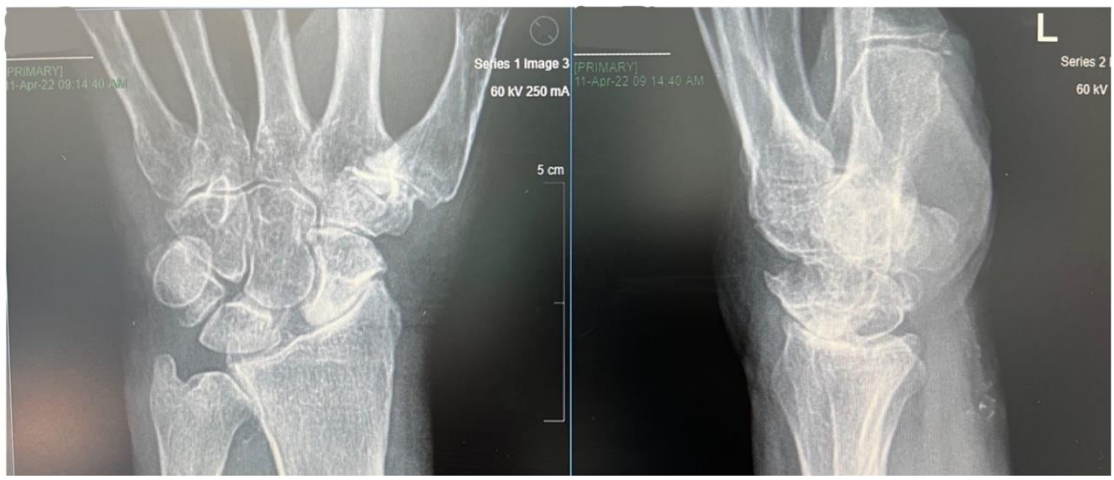

Figure 1: pre-operative radiographs showing thumb CMCJ osteoarthritis and SLAC wrist

Figure 2: Operative set up for thumb CMCJ arthroplasty

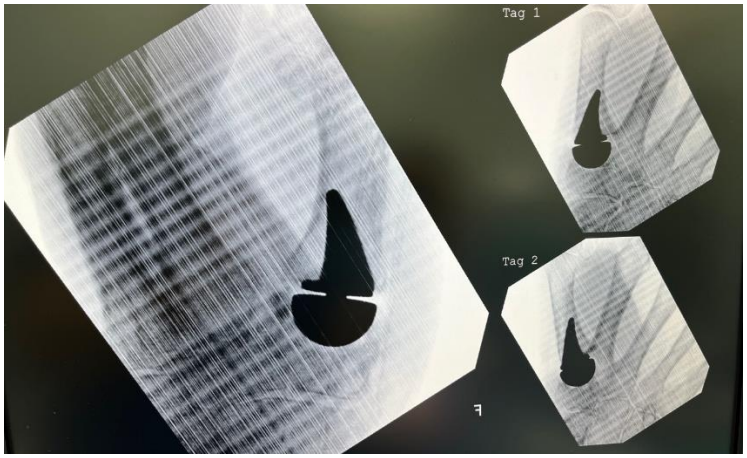

Figure 3: Intra-operative radiographs showing implant position and the inbuilt varus attitude of the metacarpal prosthesis to adduct the thumb metacarpal

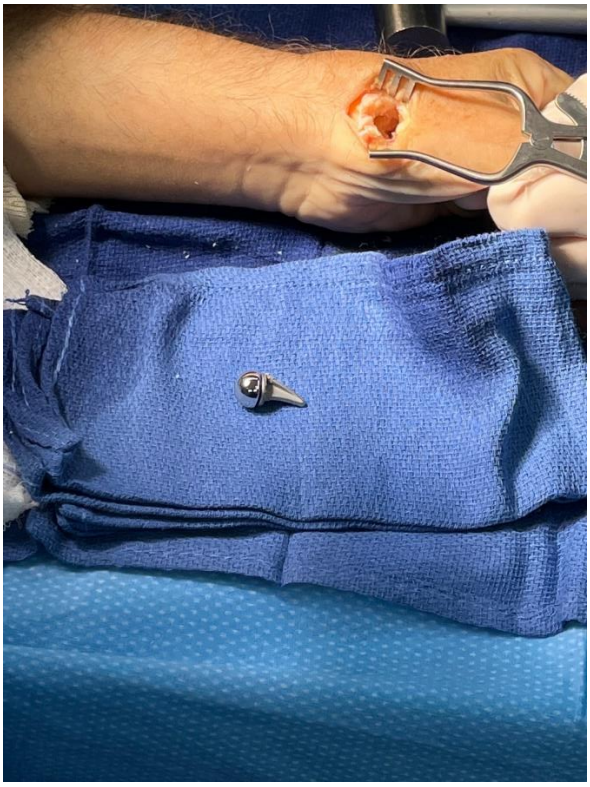

Figure 4: Thumb CMCJ hemi-arthroplasty and incision

Figure 5: Intra-operative radiograph showing radial cortex of the trapezium prevents implant extrusion

Figure 6: Post operative hand therapy turning different sized objects in rice to provide resistance, building grip and pinch strength

References

1. Kellgren JH, Lawrence JS. Osteo-arthrosis and disk degeneration in an urban population. *Ann Rheum Dis*. Dec 1958;17(4):388-97. doi:10.1136/ard.17.4.388
2. North ER, Eaton RG. Degenerative joint disease of the trapezium: A comparative radiographic and anatomic study. *Journal of Hand Surgery*. 1983;8(2):160-167. doi:https://doi.org/10.1016/S0363-5023(83)80008-2
3. Weilby A. Tendon Interposition Arthroplasty of the First Carpo-Metacarpal Joint. *Journal of Hand Surgery*. 1988;13(4):421-425. doi:10.1016/0266-7681_88_90171-4
4. Davis TR, Pace A. Trapeziectomy for trapeziometacarpal joint osteoarthritis: is ligament reconstruction and temporary stabilisation of the pseudarthrosis with a Kirschner wire important? *J Hand Surg Eur Vol*. Jun 2009;34(3):312-21. doi:10.1177/1753193408098483
5. Chug M, Williams N, Benn D, Brindley S. Outcome of uncemented trapeziometacarpal prosthesis for treatment of thumb carpometacarpal joint arthritis. *Indian J Orthop*. Jul 2014;48(4):394-8. doi:10.4103/0019-5413.136270
6. Holme TJ, Karbowiak M, Clements J, Sharma R, Craik J, Ellahee N. Thumb CMCJ prosthetic total joint replacement: a systematic review. *EFORT Open Rev*. May 2021;6(5):316-330. doi:10.1302/2058-5241.6.200152
7. Raj S, Clay R, Ramji S, et al. Trapeziectomy versus joint replacement for first carpometacarpal (CMC 1) joint osteoarthritis: a systematic review and meta-analysis. *Eur J Orthop Surg Traumatol*. Jul 9 2021;doi:10.1007/s00590-021-03070-5
8. Yin Q, Berkhout MJL, Ritt MJPF. Current trends in operative treatment of carpometacarpal osteoarthritis: a survey of European hand surgeons.
9. Pritchett J, Habryl L. A promising thumb Basal joint hemiarthroplasty for treatment of trapeziometacarpal osteoarthritis. *Clin Orthop Relat Res*. 2012;470(10)doi:10.1007/s11999-012-2367-7