Revision Nonunion ORIF for Scaphoid Waist Fracture Utilizing a Volar Carpal Artery Vascularized Graft

Keywords: scaphoid nonunion, vascularized bone graft, volar carpal artery, SNAC wrist

Scaphoid fractures represent the most common carpal bone fracture, typically occurring after a fall onto an outstretched hand. A large proportion of these fractures occur at the waist of the scaphoid. While the majority of these go on to uneventful union, there is still about a 5-15%[1] nonunion rate, due to the tenuous retrograde blood supply of the scaphoid.

Nonunions of the scaphoid can pose a difficult problem. Most surgeons would agree that for nonunions with humpback deformity or cystic changes, bone grafting is likely necessary. There are a large variety of bone grafting options, including non-vascularized and vascularized options. Options include distal radius bone graft, iliac crest bone graft, 1,2 intercompartmental supraretinacular artery pedicled graft, medial femoral condyle pedicled graft, the volar carpal artery graft, as well as others.[2,3]

I chose the following case for a variety of reasons. First, there is a lot of literature about this topic, and so there is a lot to read about, from diagnosis to management to post-operative care. Second, this case led to a lot of good discussion with the consultant during the case about their management of nonunions and choice of graft. Lastly, my experience to this point has mainly been with cancellous or corticocancellous grafting or MFC graft. I haven't had much exposure to local pedicled grafts and so this was an interesting case for me to see and read more about.

The first reported use of vascularized bone graft (VBG) in the wrist was by Roy-Camille in 1965, using the scaphoid tubercle on an abductor pollicis brevis muscle pedicle.[3,4] There are several advantages to vascularized bone grafts, including transfer of preserved osteocytes, increased perfusion, accelerated graft consolidation, and improved delivery of osteogenic and angiogenic properties.[3] The distal radius is incredible in that is has a complex leash of vascularity, allowing both dorsal and volar vascularized graft options. Indications for the use of VBGs in the treatment of scaphoid nonunion include a failed previous conventional graft or AVN of the proximal pole. [5]

This is a case of an 18-year-old male who presented to clinic with chronic pain in his wrist. He had previously had a scaphoid fracture, that went on to nonunion. This was then treated with ORIF with cancellous grafting about a year prior. He presented with persistent pain as well as limited range of motion, with about 30 degrees of extension and 60 degrees of flexion.

Imaging showed a nonunion of the waist of the scaphoid with prior screw fixation. He had both DISI deformity, with humpback and cystic changes within the scaphoid with no significant arthrosis of the radioscaphoid joint. Due to the chronicity of the nonunion, as well as persistent symptoms, the patient was indicated for nonunion revision ORIF. As he had already undergone prior nonunion ORIF that had now failed, the decision was to proceed with a local vascularized bone graft.

The patient was taken to the operating theater and placed supine on a hand table. The prior volar incision was used and the screw was removed. The scaphoid nonunion was thoroughly debrided and showed good bleeding bone on both proximal and distal fragments. The defect was measured and the appropriately sized volar carpal artery vascularized bone graft was elevated (see details below). This was then inset into the scaphoid defect and a screw was placed retrograde across the fracture site. A radio-lunate pin was placed for maintenance of neutral lunate alignment from his prior DISI.

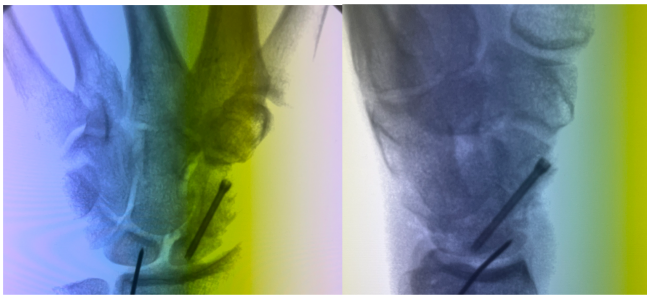

The patient was placed in a volar splint, discharged the day of surgery, and his immediate post-operative course was unremarkable. His two-week appointment showed his incision was healing well and he remained immobilized. Long term follow-up will hopefully show a healed scaphoid nonunion. The plan is to obtain a CT to evaluate healing around 12 weeks.

Volar distal radius bone grafts are a viable solution for scaphoid nonunions. The ultimate goal of nonunion ORIF is to heal the fracture and restore carpal geometry, intrascaphoid angle, and scapholunate angle.[6] There are 4 possible options, with the volar carpal artery graft being one of the more common ones.[7] It is a vascularized graft off the radial branch of the volar carpal artery, harvested from the volar ulnar distal radius epiphysis, 0.5-1.5 cm proximal to the joint and just distal to the pronator quadratus. The mean length of the pedicle is about 3cm, allowing sufficient mobilization for placement within a scaphoid nonunion.[7]

A study of 9 patients who underwent volar carpal artery VBG and volar plating revealed bone union in 8/9 patients, patient satisfaction in 8/9 patients, improved grip strength compared to preoperatively and similar flexion and extension compared to pre-operatively.[8] Another study of 9 patients showed union in all patients, improvement in pain in all patients, and significant improvement in Mayo wrist scores in all patients.[9] Another study of 15 proximal pole scaphoid nonunions with AVN showed 84% of scaphoids went on to union at 12 weeks, and all had correction of humpback deformity and improvement in carpal geometry measures including intrascaphoid angles and SL angles.[10] A study out of France looking at 111 cases shows results similar to the above studies.[11]

Overall, this was an interesting case for me to see and to learn more about local vascularized bone graft options for scaphoid nonunions. I think this is definitely something I will add to my possible choices for graft. I think that in the setting of a revision nonunion where non-vascularized graft has failed or a proximal pole with AVN, a local vascularized option will likely be my next choice. As I would choose to go volar for most nonunions to help correct the humpback deformity, I would feel a lot more comfortable doing a volar carpal artery graft after reviewing this case. I think the only other possible change I would make is using a locking plate instead of a screw in the setting of revision or primary nonunion surgery.

This is one of the many interesting cases I saw during my month in Australia. I am very grateful for the incredible opportunity I had and cannot thank IBRA enough for making it possible.

References

1. Steinmann SP, Adams JE. Scaphoid fractures and nonunions: diagnosis and treatment. *J Orthop Sci*. 2006;11(4):424-431. doi:10.1007/s00776-006-1025-x

2. Sgromolo NM, Rhee PC. The Role of Vascularized Bone Grafting in Scaphoid Nonunion. *Hand Clin*. 2019;35(3):315-322. doi:10.1016/j.hcl.2019.03.004

3. Derby BM, Murray PM, Shin AY, et al. Vascularized bone grafts for the treatment of carpal bone pathology. *Hand N Y N*. 2013;8(1):27-40. doi:10.1007/s11552-012-9479-0

4. Alluri RK, Yin C, Iorio ML, Leland H, Mack WJ, Patel K. A Critical Appraisal of Vascularized Bone Grafting for Scaphoid Nonunion. *J Wrist Surg*. 2017;6(3):251-257. doi:10.1055/s-0036-1597575

5. Payatakes A, Sotereanos DG. Pedicled vascularized bone grafts for scaphoid and lunate reconstruction. *J Am Acad Orthop Surg*. 2009;17(12):744-755. doi:10.5435/00124635-200912000-00003

6. Karaismailoglu B, Fatih Guven M, Erenler M, Botanlioglu H. The use of pedicled vascularized bone grafts in the treatment of scaphoid nonunion: clinical results, graft options and indications. *EFORT Open Rev*. 2020;5(1):1-8. doi:10.1302/2058-5241.5.190021

7. Elzinga K, Chung KC. Volar Radius Vascularized Bone Flaps for the Treatment of Scaphoid Nonunion. *Hand Clin*. 2019;35(3):353-363. doi:10.1016/j.hcl.2019.03.012

8. Dodds SD, Halim A. Scaphoid Plate Fixation and Volar Carpal Artery Vascularized Bone Graft for Recalcitrant Scaphoid Nonunions. *J Hand Surg*. 2016;41(7):e191-e198. doi:10.1016/j.jhsa.2016.04.021

9. Dailiana ZH, Malizos KN, Zachos V, Varitimidis SE, Hantes M, Karantanas A. Vascularized Bone Grafts From the Palmar Radius for the Treatment of Waist Nonunions of the Scaphoid. *J Hand Surg*. 2006;31(3):397-404. doi:10.1016/j.jhsa.2005.09.021

10. Sommerkamp TG, Hastings H, Greenberg JA. Palmar Radiocarpal Artery Vascularized Bone Graft for the Unstable Humpbacked Scaphoid Nonunion With an Avascular Proximal Pole. *J Hand Surg*. 2020;45(4):298-309. doi:10.1016/j.jhsa.2019.10.037

11. Gras M, Mathoulin C. Vascularized bone graft pedicled on the volar carpal artery from the volar distal radius as primary procedure for scaphoid non-union. *Orthop Traumatol Surg Res*. 2011;97(8):800-806. doi:10.1016/j.otsr.2011.08.008