IBRA CASE STUDY

Pyrocarbon ulnohumeral interposition arthroplasty (HaPy)

Keywords: pyrocarbon, osteoarthritis, ulnohumeral, elbow, interposition.

Summary:

The use of pyrocarbon implants in orthopedic surgery is less common than that of other implants. Used in small joints of the foot or hand, attempts have been made to expand indications for this type of implant in other locations. In this case, within an ongoing research project, a young patient with elbow osteoarthritis is presented, in whom an interposition with a spherical pyrocarbon implant has been performed. This patient suffered an accident in 1998 for which he required more than one surgery. He developed post-traumatic osteoarthritis for this reason, presenting pain, a 7 on a scale of 1 to 10, and limitation of his daily activity. He was proposed to be included in a trial about the safety of these implants in the elbow as the main objective, and secondarily to improve his symptoms. I describe the surgical aspects of the case, the preoperative and early postoperative situation, and the future expectations of this type of implant in young patients.

Introduction

Pyrocarbon implants were introduced for metacarpophalangeal joint arthroplasty in the 1980s as potential alternatives to silicone. The biocompatibility and mechanical properties of pyrocarbon represented significant advantages such an elastic modulus analogous to that of cortical bone. The use of pyrocarbon implants in upper extremity arthroplasty has thus grown significantly over the past decade, culminating in a breadth of literature[1]. Pyrolytic carbon has more recently been developed for use in TM arthroplasty. This is a synthetic material formed by pyrolysis of a hydrocarbon gas. Unlike silicone, Artelon, and titanium, the modulus of elasticity of pyrolytic carbon is similar to that of cortical bone, which theoretically may prevent subsidence and better mimic the native biomechanical properties of the native TM joint. An additional benefit of pyrolytic carbon may be the potential adherence of certain joint boundary lubrication molecules to its surface, specifically phospholipids, which have been identified as a significant component of synovial fluid lubrication[2].

Overall complication and reoperation rates in the hand and wrist are about 28.2 percent and 17 percent, respectively. The proximal interphalangeal joint is associated with the highest complication rate (42.7 percent), followed by carpometacarpal joint (18.8 percent), metacarpophalangeal joint (17.6 percent), wrist (16 percent), elbow (15.7 percent), and shoulder (12.9 percent). In the hand and wrist, major complications include dislocations and subluxations (8.4 percent), stiffness and limited motion (4.4 percent), deformity (3.1 percent), hardware failure (1.9 percent), fractures (1.7 percent), persistent pain (1.7 per- cent), and infections (0.9 percent)[3].

Regarding elbow prosthetic surgery, there is a growing number of patients who benefit from these procedures. This has its advantages and disadvantages. Among

the disadvantages, prosthetic surgery in young patients implies a greater probability of requiring revision, either due to wear or prosthetic loosening. The objective of the study described in this case is to have a biocompatible and durable prosthetic option, either as a definitive element or as an intermediate element prior to a total elbow prosthesis.

There is no known history of the use of this type of pyrolytic carbon implants in the elbow except in cases of radial head fractures[4]. This study is directed at the ulnohumeral joint of the elbow, the main articular element in this region.

CASE PRESENTATION

We present the case of a 54 year-old male, with diagnosed post-traumatic osteoarthritis of the left elbow. The patient is right handed and unemployed.

Background: fall from a bicycle in 1998. Closed injury. He required several surgeries at another center, including bone grafting. He has not required any surgery for years but has developed post-traumatic osteoarthritis with pain of 7 on a scale of 1 to 10, which is affecting his daily activity and his night's rest.

He was studied for adrenal gland problems and weight loss, weakness in the lower limbs, and persistent cough. He is a rolling tobacco smoker (up to 50 grams per week). He doesn't drink alcohol.

The plan for this patient was an open biopsy and removal of osteosynthesis material with a second stage, performing interposition arthroplasty with HaPy prosthesis (one vs two stages procedure).

Physical examination prior to the intervention: good appearance of the surgical wound in the midline. There was a small scabbed area that appeared recent. Elbow mobility was 40-130º, and complete pronosupination. No distal neurovascular involvement with preserved sensitivity and normal strength.

X-rays: osteoarthritis of the elbow with osteosynthesis material.

He presented significant pain due to post-traumatic osteoarthritis of the left elbow. He had tried oral analgesia and intra-articular corticosteroid injections, without improvement. We discussed surgical treatment options such as arthrodesis, which is not a good option due to poor function, interposition arthroplasty, or total elbow replacement. We discuss advantages and disadvantages of each of them. The ongoing research on a new form of interposition called the “HaPy Elbow Trial” was offered to the patient, who consented to inclusion.

Surgical risks were explained including possible infection, injury to nerves, blood vessels or tendons, bleeding and hematoma, formation of intravascular thrombi in the lower limbs or in the lungs, which could trigger a lethal problem.

Summary of the surgical protocol: induction antibiotic prophylaxis. Midline lateral paraolecranon approach. Osteoarthritis was seen in both aspects of the ulnohumeral

joint. Several intraoperative samples were taken for microbiological culture, 2 samples for pathological anatomy and 2 for bacterial PCR. Fixation material was removed from the distal humerus. The distal humerus and proximal ulna were prepared with saw and reamer to engage the 21mm HaPy Pyrocarbon Insertion Implant. Stability with elbow mobility was checked. Limitation for elbow extension. Repair of the triceps with transosseous tunnels in the olecranon with Orthocord No. 2. Closing in layers. Postoperative mobility: 30º extension to 150º flexion. Full pronosupination.

The patient remained one night at the hospital and was discharged. At 3 weeks postop, patient was checked in the clinic, pain had improved, and there were no major complications. Range of mobility (ROM) was -45º/100º with full pronosupination.

DISCUSSION OF CASE

It is soon to determine the evolution of this implant, but a path has been opened with this study to verify their safety, also showing promising results. The biocompatibility of these implants makes them very durable, so it can allow activity and acceptable functionality for years. One of the advantages of this implant for future surgeries is the preservation of bone stock and the non-use of bone cement, which makes it easier to extract and to face a total elbow prosthesis with the most preserved anatomy. With this research, a very interesting alternative is studied in the prosthetic field, which is not usually considered in the elbow. Hopefully the results show that patients can be happy.

ACKNOWLEDGEMENT AND REFERENCES

I would like to thank Prof. Watts for his welcome and dedication during my visit to Wrightington NHS Hospital, and the entire team that coordinates the care of patients with elbow injuries.

1. Abi-Rafeh, Jad M.D., M.Sc.; ElHawary, Hassan M.D., M.Sc.; Azzi, Alain J. M.D., M.Sc.; Thibaudeau, Stephanie M.D.. Pyrocarbon Arthroplasty Implants in the Upper Extremity: A Systematic Review of Outcomes and Pooled Analysis of Complications. Plastic and Reconstructive Surgery 148(6):p 946e-958e, December 2021. | DOI: 10.1097/PRS.0000000000008514.
2. Mark A. Vitale, Fraser Taylor, Mark Ross, Steven L. Moran, Trapezium Prosthetic Arthroplasty (Silicone, Artelon, Metal, and Pyrocarbon), Hand Clinics, Volume 29, Issue 1, 2013, Pages 37-55, ISSN 0749-0712, ISBN 9781455770960, https://doi.org/10.1016/j.hcl.2012.08.020.
3. Abi-Rafeh, Jad M.D., M.Sc.; ElHawary, Hassan M.D., M.Sc.; Azzi, Alain J. M.D., M.Sc.; Thibaudeau, Stephanie M.D.. Pyrocarbon Arthroplasty Implants in the Upper Extremity: A Systematic Review of Outcomes and Pooled Analysis of Complications. Plastic and Reconstructive Surgery 148(6):p 946e-958e, December 2021. | DOI: 10.1097/PRS.0000000000008514.

4. Ricón, F.J., Lajara, F., Fuentes, A. *et al.* Pyrocarbon arthroplasty in acute unreconstructable radial head fractures: mid-term to long term results. *J Orthop Traumatol* **19**, 13 (2018). https://doi.org/10.1186/s10195-018-0499-6.

Figures 1 and 2. Preop x-rays.

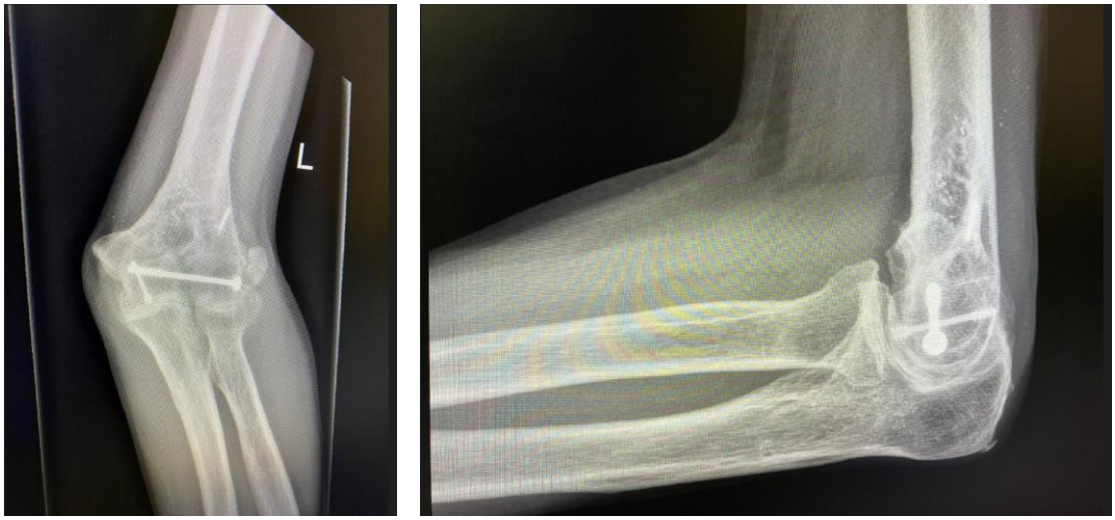

Figures 3, 4, 5 and 6. Range of motion in flexion-extension and pronosupination

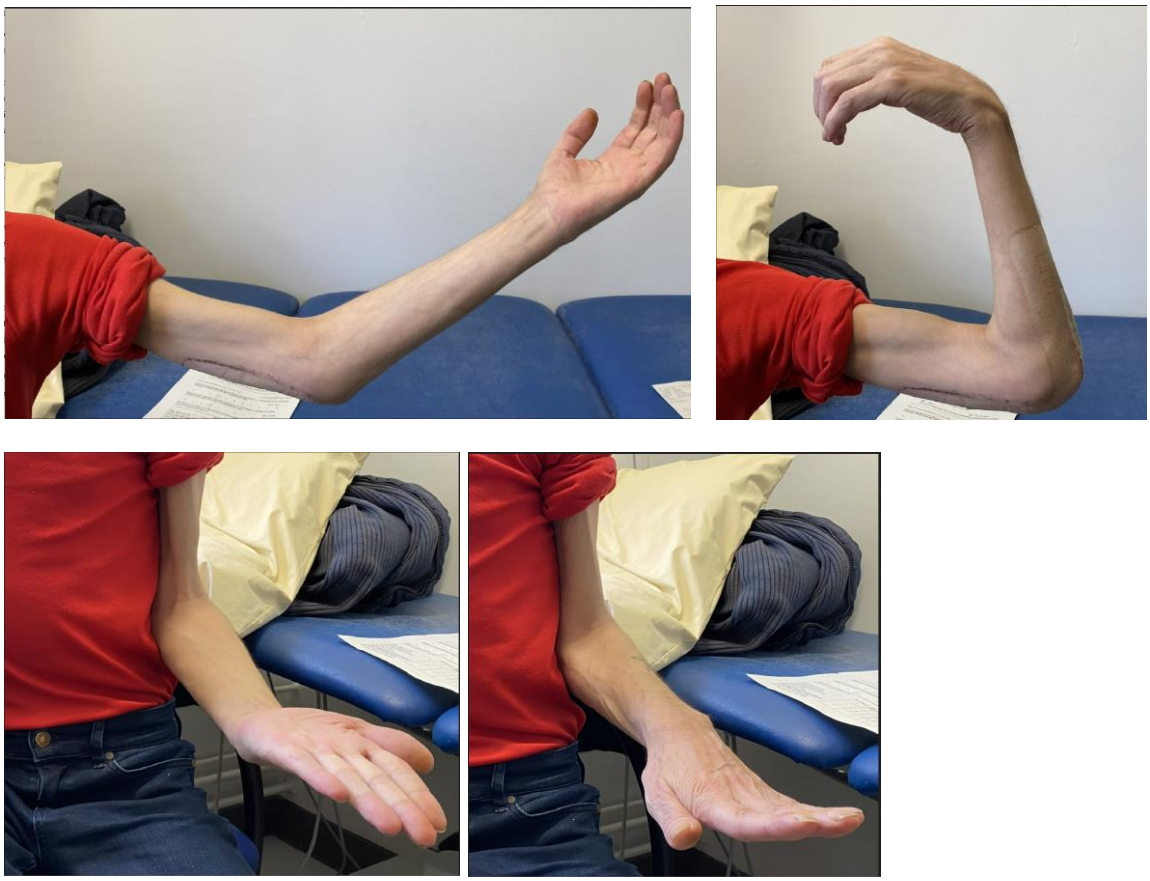

Figures 7, 8 and 9. Intraoperative images

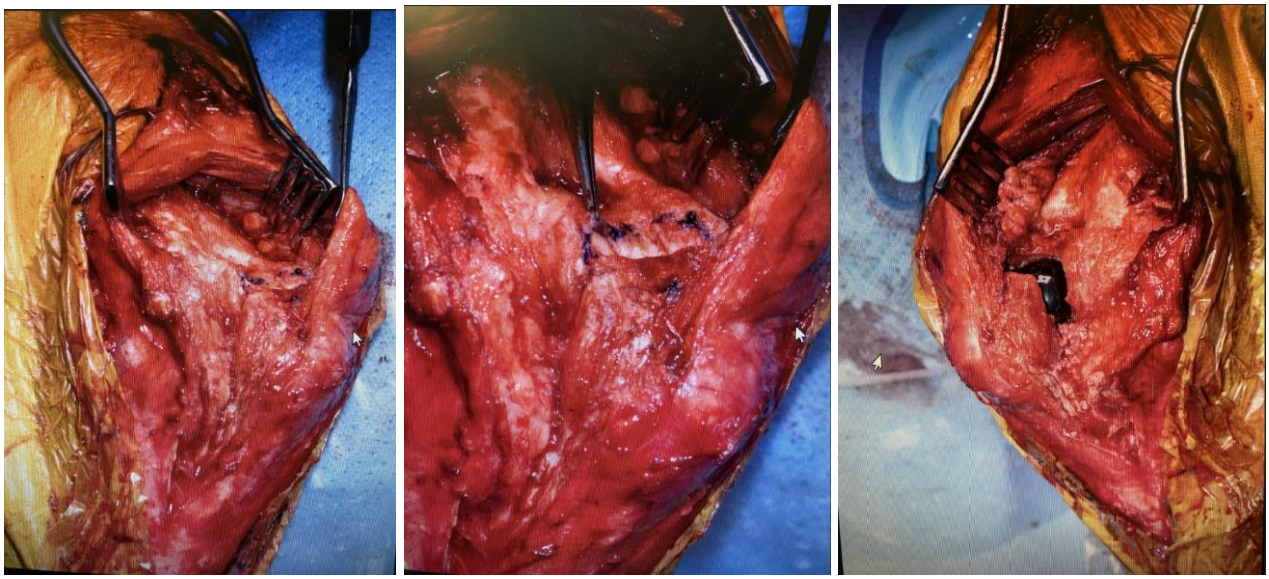

Figures 10 and 11. Postop x-rays.