# The sequalae of an unrecognized coronoid fragment: report of a case

**Keywords:** coronoid fracture; olecranon fracture; elbow instability; radial nerve palsy

## Abstract

The coronoid process is a key structure of the proximal ulna, providing stability within the ulnohumeral articulation. Coronoid fractures usually occur in association with specific injury patterns. In this study, we report on a case of a missed coronoid fragment in a 66y old patient, who had sustained a "benign" looking olecranon fracture along with a radial neck fracture. Significant instability after initial fixation with a dorsal plate was addressed by placing a bridging external fixator, furtherly complicated by iatrogenic radial nerve palsy. During revision surgery in our institution, the coronoid fragment was accessed and stabilized through a medial approach, thus restoring completely elbow stability over a full range of motion. The nerve was found to be entrapped by both humeral pins and managed my primary repair. The LUCL was found to be detached from its humeral origin and reattached with a bone anchor. This case implies that proximal ulna fractures can be considerably more complex than initial x-rays suggest. Subtle signs of instability can be present even in the absence of a true elbow dislocation and should be recognized pre-operatively to avoid adverse complications.

## Introduction

The stability of the elbow is primarily provided by the ulnohumeral articulation, the lateral ulnar collateral ligament (LUCL) complex and the anterior bundle of the MCL. Secondary stabilizers include the radiocapitellar contact, the anterior capsule and the common flexor and extensor tendons. Muscles crossing the elbow, such as the anconeus, brachialis and triceps muscle can act as dynamic constraints (Karbach et al..2017). Within the ulnohumeral articulation, the coronoid process is a key structure functioning as a bony buttress to posteriorly directed translation forces. O' Driscoll et al. have classified coronoid fractures according to their anatomic location, thus identifying three different types: 1) tip 2) anteromedial facet 3) and basal fractures (Fig.1). Each type is associated with specific fracture patterns and concomitant lesions: transverse tip fractures usually accompany terrible triads, anteromedial facet fractures are associated with varus posteromedial instability, while basal fractures occur in conjunction with trans-olecranon fracture dislocations (Tarassoli et al., 2013). All of them are well-recognized injury patterns accounting for the majority of traumatic elbow instability cases. However, traumatic elbow instability may be present even in more atypical fracture patterns.

| Coronoid Fracture Classification | | | (O'Driscoll et al. 2003. AAOS ICL.) |
|---|---|---|---|
| Fracture Type | Fracture Subtype | Description | |
| **Tip** | 1 | ≤ approximately 2 mm of coronoid bony height (ie, flake fracture) | |
| | 2 | > approximately 2 mm of coronoid height | |
| **Anteromedial** | 1 | Anteromedial facet | |
| | 2 | Anteromedial facet + tip | |
| | 3 | Anteromedial facet + sublime tubercle (± tip) | |
| **Basal** | 1 | Coronoid body and base | |
| | 2 | Transulnar basal coronoid fractures | |

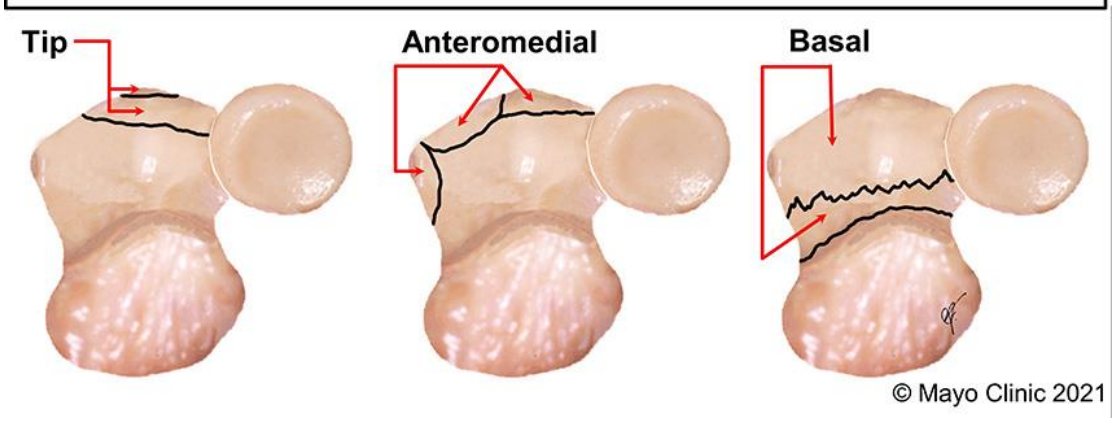


**Fig 1.** O'Driscoll classification of coronoid fractures

**Case presentation**

In this study, we report on a case of 66year old female patient, who had sustained an olecranon fracture associated with an undisplaced radial neck fracture. Based on the initial x-rays, the fracture could be classified as a Mayo IIb since no apparent evidence of disruption of the ulnohumeral alignment is present (Fig.2). The patient had undergone open reduction and internal fixation with an anatomical LCP olecranon plate in another institution. The injury on the radial side had not been addressed. After the completion of the osteosynthesis, the joint was reported to be grossly unstable, and it was deemed necessary to place an external fixator over the elbow. After patient' s awakening, inability to extend the wrist and the fingers suggested an iatrogenic radial nerve palsy. Thus, the patient was referred to our clinic for further evaluation and treatment.

Figure 2: Initial x-rays: note the presence of the unrecognized coronoid fragment (yellow arrow)

X-ray and CT control at our institution demonstrated a satisfying reduction of the olecranon fracture, but obvious signs of elbow instability probably due to escape of a missed coronoid fragment (Fig.3). Neurovascular evaluation was suggestive of a high radial nerve palsy. It was decided to investigate the course of the radial nerve around the pins insertion area and then to stabilize the coronoid fragment through a medial approach with the LCP in place.

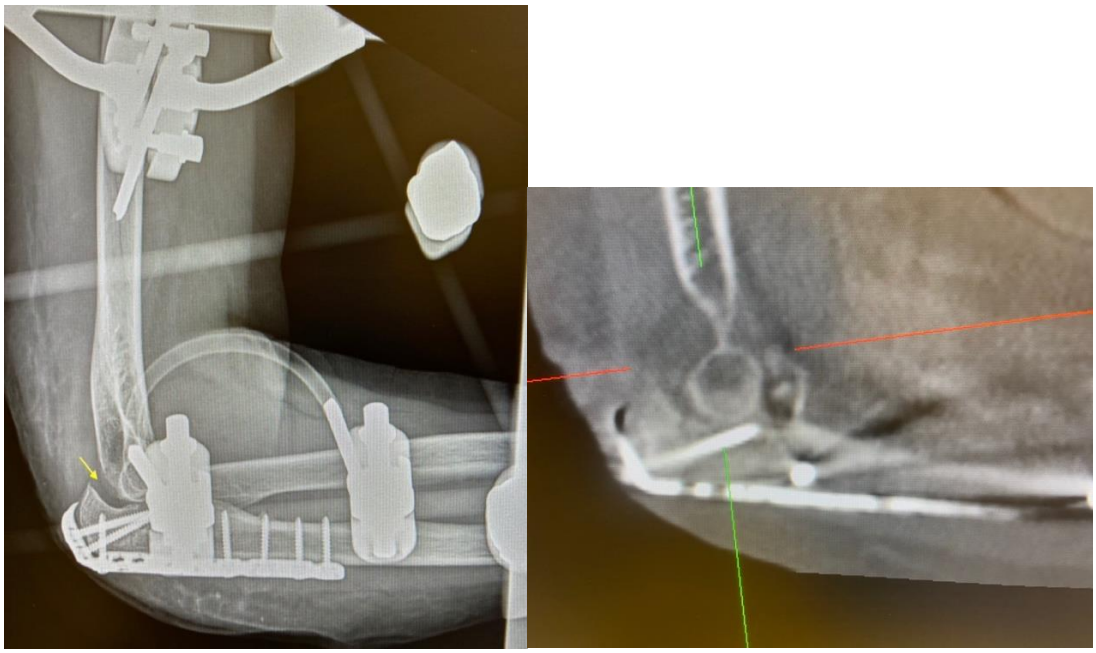

Figure 3: Post-operative x-ray and CT view after initial fixation. Despite the presence of hardware, ulnohumeral subluxation can be seen (yellow arrow) on x ray and escape of coronoid fragment on the CT

**Management and outcomes**

The external fixator was removed before draping, leaving the humeral pins in situ. Clinical examination under anaesthesia revealed significant instability, as the elbow was being moved into extension. Initially, a skin incision was made on the lateral aspect of the distal humerus, focused on the site of pin insertion, in order to identify potential injury to the radial nerve. Indeed, it was recognized that the nerve was penetrated by both pins. The pins were carefully removed, leaving two lesions of 2-3mm on the nerve. Since there was continuity of the majority of the fibers, it was decided to try a primary repair of the injured ones (fig.4a-b).

Figure 4a,b. A)Intraoperative view of the pin penetrating the radial nerve. The first pin has already been removed leaving a hole through the nerve (yellow arrow). B) radial nerve after primary repair

The coronoid fragment was accessed using an FCU split approach. A skin incision was made centered over the medial epicondyle and the ulnar nerve was identified both proximally and distally. The nerve was kept intact within its sulcus in order to avoid iatrogenic instability post-operatively. The interval between the two heads of the flexor carpi ulnaris was developed providing access to the coronoid fragment (Fig.5). Intraoperative manipulations showed that pronation of the forearm caused subluxation of the ulnohumeral joint, similarly to a varus posteromedial rotatory type instability.

The fracture site was irrigated, and the coronoid fragment was anatomically reduced and provisionally stabilized with a 1.6 mm K-wire (fig.6). Then, a Trilock 2.0 coronoid plate (Medartis®) was placed and secured using 2 screws both proximally and distally.

Figure 5. Fracture site exposed through the FCU interval. Ulnar nerve recognized proximally and distally

Clinical examination after coronoid fixation showed complete restoration of elbow stability over a full range of motion. The posterior band of the MCL and the origin of the flexor pronator mass were reattached to the medial epicondyle. Finally, a small skin incision was made on the lateral side centered over the radial head. Deep dissection revealed a detachment of the LUCL from its humeral

Figure 6: fluoroscopic image after preliminary reduction

origin. No motion was observed at the radial neck fracture site, suggesting fracture healing in an acceptable position. A bone anchor was placed into the lateral epicondyle to reattach the LUCL. Subcutaneous fat and skin were closed in the routine manner. A functional brace with an extension block at 30° was placed, allowing for early protected range of motion. The patient was discarded two days later, while wound healing was uneventful. Routine follow-up after three weeks showed a congruent joint on x-ray (Fig.7).

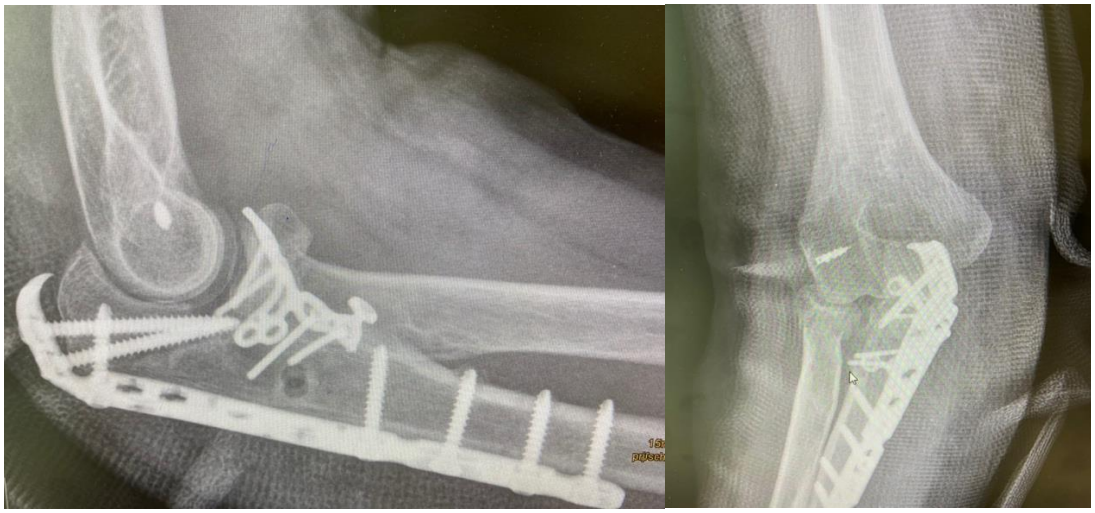

Figure 7: Post-operative x-rays showing good reduction of the coronoid fragment and joint congruency without signs of instability

**Discussion**

Proximal ulna fractures can potentially pose significant challenges to the surgeon, as they may represent only a part of a more complex lesion. In many cases, the true extent of the injury may be underestimated, leading to poor treatment. Goals of treatment should be anatomical reduction within the ulnohumeral joint and restoration of elbow stability. Identification of the fragments is a key element to achieving optimal outcomes. In this case, there are no apparent signs of instability on initial x-rays except for the presence of a relatively small coronoid fragment. Inability to recognize this fragment and the concomitant LUCL injury has led to poor management and the necessity to place and external fixator. The post-operative CT, although limited by the presence of hardware, reveals subluxation of the ulnohumeral joint and escape of the coronoid fragment.

Coronoid fragments associated with trans-olecranon fractures - dislocations are typically basilar and relatively larger in size. Thus, they can usually be secured with screws inserted through a posterior plate. In addition, the radial head and the collateral ligaments typically remain intact. On the other hand, posterior olecranon fracture dislocations may have more atypical fracture characteristics. However, they are characterized by disruption of the proximal radioulnar joint, thus belonging to the spectrum of Monteggia equivalents (Chan et al., 2016). Our case cannot be classified to either of these two types: the fragment was considerably smaller and the fracture line extended into the anteromedial facet. The latter has been the focus of interest of recent research, as it resists to varus stress. Moreover, it is unsupported by the ulna metaphysis, thus being prone to fracture (Ring et., 2015). Biomechanical studies suggest that ulnohumeral posterior displacement does not occur if more than 50% of the coronoid height is maintained, given the collateral ligaments remain intact (Closkey et al., 2000).

The reason for selecting this case was to emphasize the fact that elbow instability does not always follow predictable injury patterns. Instability can accompany even more "benign" looking fractures without the presence of a true elbow dislocation. As mentioned previously, olecranon fractures can be only a part of more complex lesions, especially if the fracture line extends into key structures of the proximal ulna such as the coronoid or the cresta supinatoris. A concomitant radial head fracture, ecchymosis on the lateral aspect of the elbow or a small coronoid bony fragment are all suggestive of potential instability and should alert the surgeon. In any case, if persistent elbow instability is observed after olecranon osteosynthesis, the surgeon should be prepared to address any potential reasons, such as the coronoid, the LUCL complex or the MCL. Most of these structures can be addressed through the posterior approach, used for the olecranon fracture. Additionally, radial nerve palsy is an uncommon but potentially devastating complication of pins placement into the humeral shaft. Cadaveric data suggest that the nerve travels along the lateral aspect of the humeral shaft at an area of 6mm to 13.5mm as measured from the rotational center of the elbow (Wegmann et al., 2014). However, there is a noteworthy variability in the course of the nerve and even a more proximal or distal pin insertion is not unlikely to injure the nerve. Thus, bridging external fixators over the elbow should only be reserved for those cases of persistent instability after having addressed all potential bony and ligamentous lesions.

**References:**


1. Chan K, King GJ, Faber KJ. Treatment of complex elbow fracture-dislocations. Curr Rev Musculoskelet Med. 2016 Jun;9(2):185-9. PMID: 26984334

2. Closkey RF, Goode JR, Kirschenbaum D, Cody RP. The role of the coronoid process in elbow stability. A biomechanical analysis of axial loading. J Bone Joint Surg Am. 2000 Dec;82(12):1749-53. PMID: 11130649.

3. Karbach LE, Elfar J. Elbow Instability: Anatomy, Biomechanics, Diagnostic Maneuvers, and Testing. J Hand Surg Am. 2017 Feb;42(2):118-126. PMID: 28160902

4. Ring D, Horst TA. Coronoid Fractures. J Orthop Trauma. 2015 Oct;29(10):437-40 PMID: 25785359.

5. Tarassoli P, McCann P, Amirfeyz R. Complex instability of the elbow. Injury. 2017 Mar;48(3):568-577. PMID: 24161720.

6. Wegmann K, Lappen S, Pfau DB, Neiss WF, Müller LP, Burkhart KJ. Course of the radial nerve in relation to the center of rotation of the elbow--the need for a rational safe zone for lateral pin placement. J Hand Surg Am. 2014 Jun;39(6):1136-40. PMID: 24799145.