Christian K Spies - case study - IBRA scholarship 2023

Tension band suturing of a multifragmentary olecranon fracture

Keywords:
tension band suture, olecranon, fracture

Summary:
Fifty-four year-old hobby cyclist fell and suffered from a multifragmentary olecranon fracture. After initial treatment in a fracture clinic he was referred to Wrightington Hospital 2 weeks later and surgery was undertaken at that time. After analysing the fracture pattern and intraoperative testing the fracture was suitable for tension band suturing. The postoperative treatment included active motion without load for 6 weeks.

Introduction:

Olecranon fractures are common fractures of the upper limb ranging from simple transverse intra-articular fractures to injuries that may result in substantial articular comminution (1). To address these fracture patterns tension band wire fixation, plate osteosynthesis and intra-medullary fixation have been applied. Common complications are discomfort based on prominence of the material implanted, wound healing problems and the necessity for hard ware removal. The latter aspects may be as high as 75% for tension band wiring and 50% for plate fixation (2-5). Therefore, techniques which facilitate low-profile material and at the same time stability to allow early active motion may be desirable.

Case Presentation:

A 54 year-old hobby cyclist fell and suffered from a multifragmentary olecranon fracture. He was treated at a fracture clinic at the day of injury with a plaster of Paris arm cast. Then he was referred to the Wrightington Hospital for further treatment. After preoperative work-up he was prepared for surgery. The x-ray presented a multifragmentary olecranon fracture with a quite large intermediate part (figure 1a). The CT scan defined the fracture pattern precisely (figure 1b).

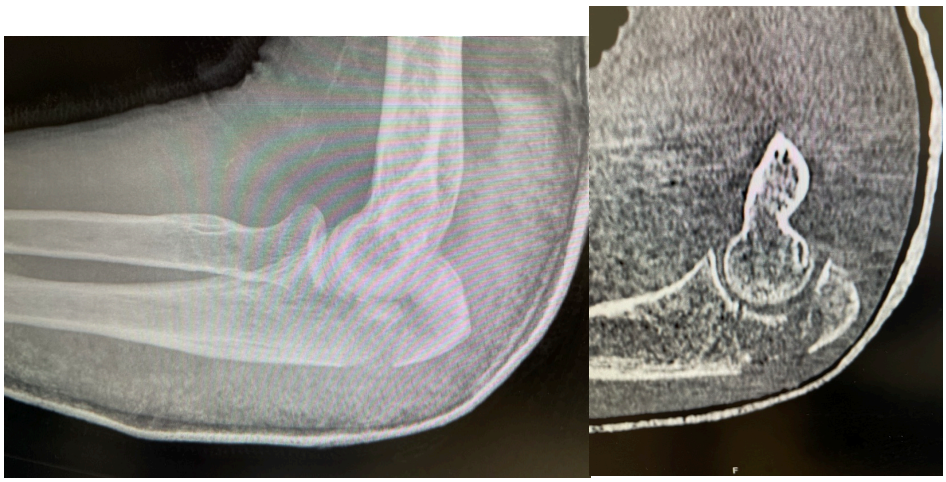

Figure 1 x-ray (left) and CT scan (right) reveals a multifragmentary olecranon fracture

We classified the fracture as Mayo type 2b. The surgical strategy was set and the plan was to reduce and fix the fracture with tension band suturing. Using the posterior approach and preparation of the fracture the Mayo type 2b fracture could be confirmed intraoperatively. Therefore, the technique of tension band suturing using a very resistent and non-resorbable suture was applied (figure 2) (6).

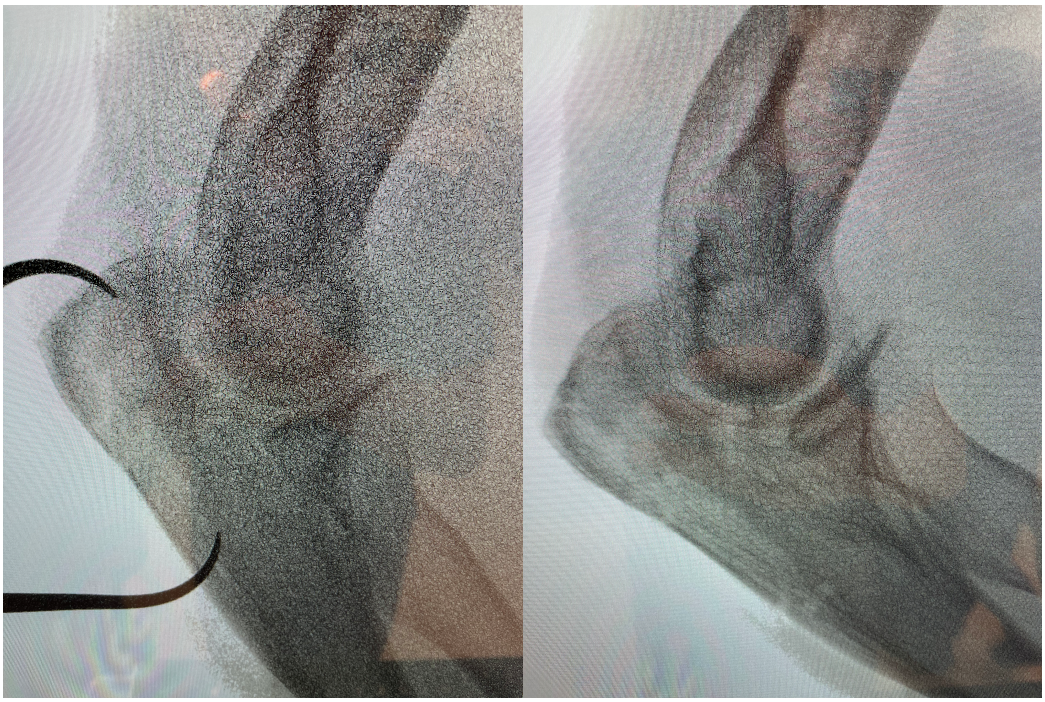

Figure 2 intraoperative lateral view: reduction of the fracture using pointed clamps (left); situs after tension band suturing (right)

The patient was encouraged to start moving his elbow without load for 6 weeks.

Discussion:

Tension band suturing is a straight forward technique which is quick and reliable as long as the fracture pattern is properly analysed and fracture stability tested. Preoperative work-up including adequate radiological diagnostics is crucial. The most important intraoperative aspect is stability testing of the elbow joint. If there is any hint of instability of the humeroulnar joint then this technique should be abandoned and a plate osteosynthesis may be the better choice.

Acknowledgement:

I do thank and appreciate Professor Watts' shared expertise and his kind permission to use the fluoroscopic pictures presented.

References:

1. Duckworth AD, Clement ND, Aitken SA, et al. The epidemiology of fractures of the proximal ulna. Injury 2012; 43: 343–346.

2. Brolin TJ and Throckmorton T. Olecranon fractures. Hand Clinics 2015; 31: 581–590.

3. Snoddy MC, Lang MF, An TJ, et al. Olecranon fractures: factors influencing re-operation. International Orthopaedics (SICOT) 2014; 38: 1711–1716.

4. Macko D and Szabo RM. Complications of tension-band wiring of olecranon fractures. J Bone Joint Surg Am 1985; 67: 1396–1401.

5. Buijze G and Kloen P. Clinical evaluation of locking compression plate fixation for comminuted olecranon fractures. The Journal of Bone and Joint Surgery 2009; 91: 2416–2420.

6. Phadnis J, Watts AC. Tension band suture fixation for olecranon fractures. Shoulder Elbow 2017; 9(4); 299-303.