IBRA case study

Title

Bilateral volarly displaced shear fracture of the distal radius, a case report

Keywords

bilateral, distal radius, shearing, smith, Barton

Summary

Distal radius fractures are the most common fractures of the upper extremity, with bimodal distribution, associated with high energy traumas in the young population and low energy traumas in the elderly due to osteoporosis. The case presented in this study summarizes the treatment of a woman who faced bilateral volarly displaced shear fractures of the distal radius, both inherently unstable and with chance of poor outcome if not properly recognized and treated[1-9]. The shearing fractures of the distal radius are rare, few studies describe the assessment and results achieved by actual most often methods of fixation[1]. This pattern involves deforming forces and poorly outcomes with nonoperatively treatment being better treated, in most cases, with early open reduction and internal fixation[2]. In this patient, both fractures were evaluated at the emergency with radiographs and CT scans, classified, indicated for surgery, and operated in a one-time procedure, by the hand surgeon Radek Kebrle, achieving adequate reduction and fixation with a volar plate and locking screws and had no complications in the first week's post-operative.

Introduction

Distal radius fractures (DRF) are the most common fractures of the upper extremity, the incidence is reported as 16 in 10000[2], the distribution is bimodal, most frequently seen in the young population due to high energy trauma and in the old population after low energy trauma. It is rarely presented as a bilateral fracture, seen only in 1,6% of the DRF from the national Swedish fracture register[1]. Probably due to being rare, there is no consensus on the treatment of bilateral DRF, its management and concern about this peculiarity in the patient treatment and there are not many articles published in this topic about DRF.[3,4]

The volar Barton distal radius fractures were described as oblique fractures of the volar margin of the articular surface with the carpus subluxation proximally and volarly within the volar fragment. It was believed, in the past years, as a large single volar fragment, but, in more recent studies, it is more often to identify comminution of the volar fragment and dorsal cortical breaks, an aspect that changes the classification of the fracture from *partial* articular to *complete* articular (fracture line extending through the dorsal cortex of the metaphysis of the distal radius, reported as up to 75% of patients with a volar Barton distal radius fracture).[5] This cortical break line can be missed on plain radiographs views, being better analyzed with a CT scan and believed to be associated with more comminution of the volar fragment.[5]

The case report is about a woman, 48 years old, who faced a bilateral distal radius fracture with volar dislocation after a fall from her own height, presenting the dorsal cortical break, impaction of the articular surface and loss of bony and ligamentous support due to the shearing forces involved, on both sides. It is important to recognize the fracture as resulting from shearing forces because of their instability and risk of poor outcomes if a wrong diagnosis results in delayed treatment of the fracture.[2,5,6] The assessment of the fracture with only an "in situ" buttress plate

is not sufficient to restore the articular surface anatomy, due to the flexion of both the anterior and dorsal rim fragments and the impaction of the articular surface, it may explain malalignments in some patients, especially when using an intentionally under contoured buttress plate.[6] In Radeks' opinion, a good intraoperative technique is to precisely achieve the contact and alignment of the metaphyseal fragments to the distal radius volar and dorsal diaphyseal cortices and use it as a reduction parameter, to achieve the proper position of the articular surface and prevent volar carpal translocation.[7] In some cases, it may be necessary to raise the articular surface through the fracture and sometimes also use bone graft to support the articular main fragments. Many strategies have been described as fixation methods of volar shearing DRF, such as column specific plates, 1-hole plate and cancellous screw, volar fragment specific hook plate, pre-contoured volar plate and others.[5,6,8]

Studying this specific case provides an overview of the changes in the assessment of volar dislocation shear fractures of the distal radius, evolving in the past 20 years, with different classification details and fixation techniques.

Case presentation

MD, 48 years old, faced a bilateral closed DRF after a fall from her own height, at her home, with both outstretched arms on May 6th, 2022. She went to the clinic "Klinika Dr. Pirka" and, in the emergency room, were performed x-rays and CT scans of both her wrists (Figure 1, 2, 3 and 4), splinting and analgesia. Both fractures were classified as a Fernandez Shear fracture/Volar Barton's/Smith type II, but her left wrist fracture had also comminution of the volar fragment and the above described dorsal break. The treatment indicated was the surgery for open reduction and internal fixation, scheduled for May 16th. She waited for the surgery at home, being admitted in the morning of the surgery and staying in the hospital for 1 more day after the procedure. Before going home, she was told the basics about post-operative care, to rest, to use the splints on both wrists until the day of the return consultation, the use of painkillers if necessary and to return in a week for wound care and in two weeks again to remove the stiches.

(Figure 1. Left wrist radiograph front and lateral views)

(Figure 2. Right wrist radiograph front and lateral views)

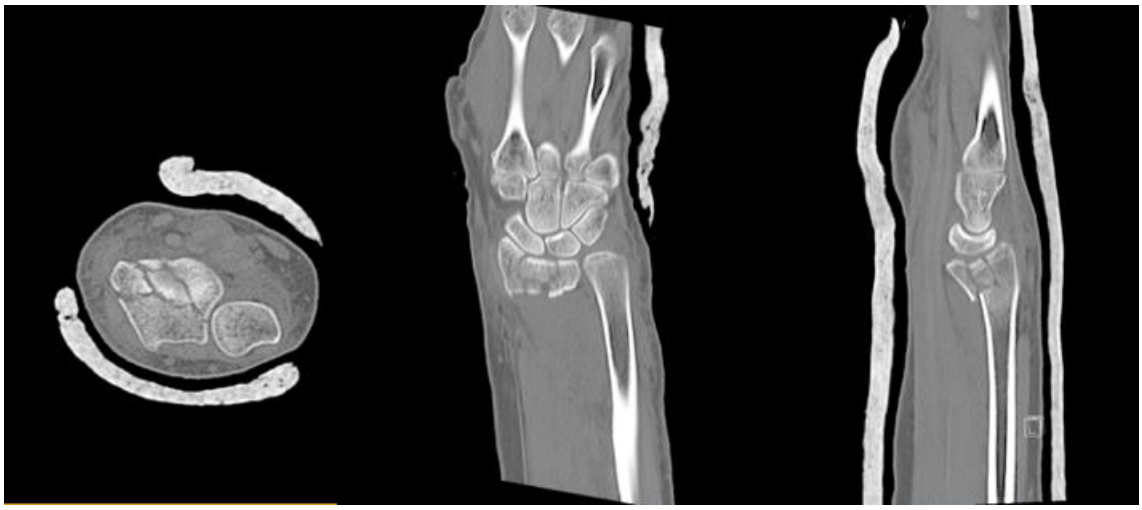

(Figure 3. Left wrist CT scan axial, coronal and sagittal views)

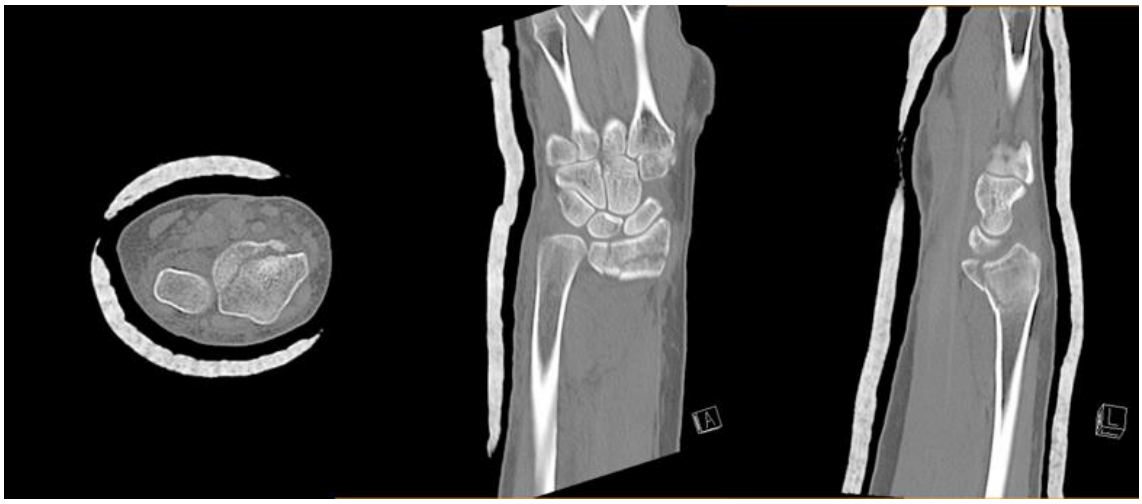

(Figure 4. Right wrist CT scan axial, coronal and sagittal views)

The patient reported a lot of pain at the moment of the injury, improving only after the immobilization of both wrists in the emergency room. The patient was afraid of feeling pain again after surgery, but, doctor Radek explained to her the expected post-operative, with only mild pain thanks to the anesthesia. She was confident with the treatment and had her time to ask questions about it before the procedure.

The physical exam of her wrists by the time of the surgery presented minor swelling, probably because of the preoperative splinting and followed instructions by her to stay at home and rest. She also had no nerve palsy and no associated injuries.

In the radiographs of the left wrist, it is possible to evaluate the fracture as a result of shear forces throughout the volar rim, the long axis of the wrist is volar to the long axis of the radius, there is comminution of the volar fragments and loss of radial height. In the sagittal plane of the CT scan of the left wrist, it is visible the dorsal break line, impaction of the central articular fragment and its size can be estimated with the axial view, being considered one of the main fragments.

The radiographs of the right wrist shows a volar shear fracture of the distal radius, the carpi is subluxate to anterior and proximally to the radius axis, it is possible to see a dorsal break line but there is less comminution of the volar fragment. Accessing the CT scan, the fracture presents less comminution, bigger fragments and less impaction than compared to the left side fracture.

Management and Outcome

On May 16th the patient was admitted in the hospital by the morning and was operated under general anesthesia and bilateral regional block with Marcaine and Mesocaine for pain relief after surgery. Both forearms were prepared and sterilized with the patient in supine positioning, Dr. Radek began the surgery from the left side, with the modified Henry's approach for the distal radius to access the fracture. The open reduction maneuvers were focused on the elevation of the central fragment, regaining the articular surface anatomy and the radial height. It's a common error to keep the dorsal rim fragment in flexion after the reduction of the volar rim, resulting in malunion and impossibility to achieve the proper reconstruction of the articular surface, so, care was taken intraoperatively to achieve extension of both the volar and dorsal rim fragments and the reduction was confirmed by fluoroscopy. Also, with the aid of fluoroscopy, a Medartis pre-contoured volar plate for the distal radius was used for fixation of the fragments. We proceeded with the closure of the wound with intradermal sutures and to the surgery of her right wrist, with the modified Henry's volar approach. As soon as we reached the radius, we identified the volar rim fragments and performed the reconstruction of the articular surface. It was clearly easier on the right radius because of the bigger fragments and less comminution. A volar pre-contoured Medartis plate was used for fixation after the reduction under fluoroscopy, the implant and screws positioning and length were checked with fluoroscopy and the wound closed with intradermal sutures. We also performed sterile bandage and splinting of her wrists. There was no need to supplement the fixation method with any other hardware.

The patient stayed in the hospital until the next morning for pain control and recovery of the anesthesia, and faced no complications during her stay in the infirmary. X-rays were performed

in the next morning (figures 5 and 6) and she was able to go home as planned, with the prescription of painkillers and information about bandage and wound care and instructions to return for consultation in one week.

(Figure 5. Postoperative left wrist radiograph front and lateral views)

(Figure 6. Postoperative right wrist radiograph front and lateral views)

One week after surgery, the patient came to the hospital to change dressings, remove the splinting and to begin hand therapy of the fingers and MP joints. The next week she came to remove the stiches and to improve the hand therapy, beginning to work on the range of motion of her wrists. No complications were identified until that moment and the pain control was effective with medication.

Discussion of case

The case presented in this study comprehends a young woman with a bilateral distal radius fracture with volar and proximal dislocation of the fragments and the carpi, a rare condition that lacks literature to assure a treatment protocol. The appropriate assessment of the fracture in the emergency room (splinting, pain control, instructions to the patient to rest, correct identification of the severity of the fracture) is of major importance to diminish swelling, provide local conditions for early open reduction and internal fixation of both sides and have low chances of complications during the whole treatment. The surgical indication in this case was both because of the described instability of volar Barton's/Smith type II fractures and because she had a bilateral fracture. A well performed surgery provides the proper reduction of the articular surface, internal fixation and immediate hand therapy after the procedure, aiming for a fast recovery and return to work.

It is not yet complete, but until the time of the end of my fellowship, in my opinion, it represents a case of success, considering the severity of the fractures and the possibility to treat both sides in one single step surgery, with adequate reduction, can provide healing and a good outcome

for the patient. It was possible to be achieved only because of the details and attention to avoid pitfalls during the pre-operative, intra operative and postoperative periods.

It would be of great importance to have more research and larger series about both bilateral DRF treatment outcomes, volar shearing dislocation fractures of the distal radius and the importance of the dorsal break line in this type of injury, to provide literature to support timing, strategies for surgery and assure better results.

Acknowledgement

I thank Klinika Dr. Pirka, the hand department team, Drs. Radek Kebrle and Martin Czinner, IBRA's educational committees for the opportunity to improve my clinical practice and to be able to share it with my country colleagues and IBRA's international community.

References

1. Rundgren, J., Bojan, A., Mellstrand Navarro, C. et al. Epidemiology, classification, treatment and mortality of distal radius fractures in adults: an observational study of 23,394 fractures from the national Swedish fracture register. BMC Musculoskelet Disord 21, 88 (2020).
2. Tägil, M. Distal Radius Fractures. in: Wolfe SW, Pederson WC, Kozin SH, Cohen MS, eds. *Green's Operative Hand Surgery.* 8th Ed. Philadelphia: Elsevier; 2021:601-676
3. Ehsan A, Stevanovic M. Skeletally mature patients with bilateral distal radius fractures have more associated injuries. Clin Orthop Relat Res. 2010 Jan;468(1):238-42.
4. Dağtaş MZ, Ünal ÖK. The external fixation can be a good alternative to plate-screw treatment in the surgical treatment of bilateral distal radius fractures: A retrospective cohort study. Jt Dis Relat Surg. 2021;32(2):406-413.
5. Daly MC, Horst TA, Mudgal CS. Dorsal Cortical Breaks in Volar Barton Distal Radius Fractures. Hand (N Y). 2021 May;16(3):303-309. Epub 2019 Jul 18.
6. Harness N, Ring D, Jupiter JB. Volar Barton's fractures with concomitant dorsal fracture in older patients. J Hand Surg Am. 2004 May;29(3):439-45.
7. Tang JB. Carpal instability associated with fracture of the distal radius. Incidence, influencing factors and pathomechanics. Chin Med J (Engl). 1992 Sep;105(9):758-65.
8. Souer JS, Ring D, Jupiter JB, Matschke S, Audige L, Marent-Huber M; AOCID Prospective ORIF Distal Radius Study Group. Comparison of AO Type-B and Type-C volar shearing fractures of the distal part of the radius. J Bone Joint Surg Am. 2009 Nov;91(11):2605-11.