Lunate Custom Prosthesis for stage IIIc Kienböck's Disease

Mariamar San Roque[1] MD, Filippo Zanotti[2] MD, Massimo Corain[3] MD

Azienda Ospedaliera Universitaria Integrata Verona
Unitá di Chirurgia della Mano

Summary

Case: A of 33 years old male presented at our consultation because of wrist pain for more than 1 year. Radiographs and MRI showed uneven lunate density with collapsed height and width of the lunate compared with the contralateral wrist. In advance Kienböck's disease, hyaline cartilage delimitation or bone fragmentation render the lunate unsalvageable. The purpose of this study was present a new treatment method and evaluate the clinical and radiographic outcomes of the lunate arthroplasty with a custom prosthesis combined with reconstruction of the scapholunate and lunotriquetral interosseous ligaments using the flexor carpi radials tendon.

Conclusions: We believe that arthroplasty of the lunate bone with a custom prosthesis for advanced stages of the disease represents a valid option. Compared with the previous report about lunate implantation this prosthesis shows the preservation of adjacent congruity.

Key Words: Lunate, Arthroplasty, Kienböck's, Ligament, Reconstruction

(1) Upper Limb Surgeon. CLIMBA (Clínica de la Mano Buenos Aires), Buenos Aires, Argentina.
(2) Upper Limb Surgeon of Hand and Microsurgery Department. Integrated University Hospital Company Verona, Italy.
(3) Director of Hand and Microsurgery Department. Integrated University Hospital Company Verona, Italy.

Introduction

Kienböck's disease is caused by avascular necrosis of the lunate bone[1]. It can ultimately progress to complete collapse and fragmentation, rendering the lunate unsalvageable[2].
According to the modified Lichtman radiologic classification, the disease is divided into four stages[3,10] (Fig.1) . Once collapse has begun (Lichtman stages IIIA/IIIB), progression to further collapse and eventual fragmentation is expected[4]. The lunate bone cannot be salvaged if the hyaline cartilage has delaminated from the underlying subchondral bone, or if the lunate has already fragmented into multiple pieces[5]. For an unsalvageable lunate, patients are usually informed of the standard surgical options are proximal row carpectomy (PRC), scaphotrapeziotrapezoid (STT) fusion, scaphocapitate (SC) fusion, or total wrist fusion (TWF)[6,7,8].

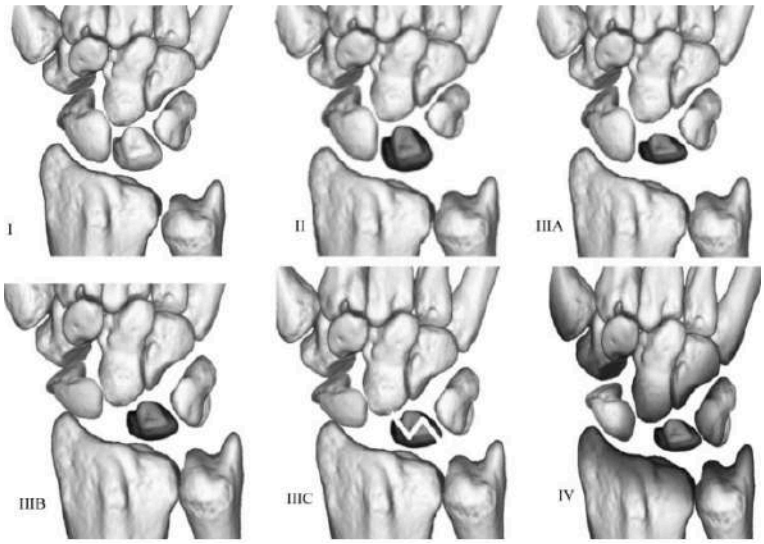

Fig. 1 The stages of the Lichtman osseous classification of Kienbock disease.

Stage IIIc Kienböck's disease is a clinical challenge to treat collapse of the lunate bone[9]. The development of an anatomical prothesis of the lunate with reconstruction of the scapholunate (SLIL) and lunotriquetal (LTIL) interosseous ligaments is an alternative. The purpose of this case report was to present the new treatment method and clinical outcome.

Case Report

A 33 years old man presented with pain in the right wrist for more than a year of evolution. The patient complained of wrist swelling, chronic pain, fatigue, unable to perform to heavy manual jobs. The lunate region presented tenderness with palpation. Wrist mobility was limited in each direction, especially in wrist dorsal extension. Plain radiographs (Fig. 2), computed tomography (CT) (Fig. 3) and magnetic resonance imaging (MRI) (Fig. 4) showed uneven lunate density with collapsed height and width of this bone compared with the contralateral wrist. Both studies were consistent with a Kienböck disease stage III C.

Fig. 2 Preoperative radiographs PA and Lateral views showed stage IIIC Kiembock's disease.

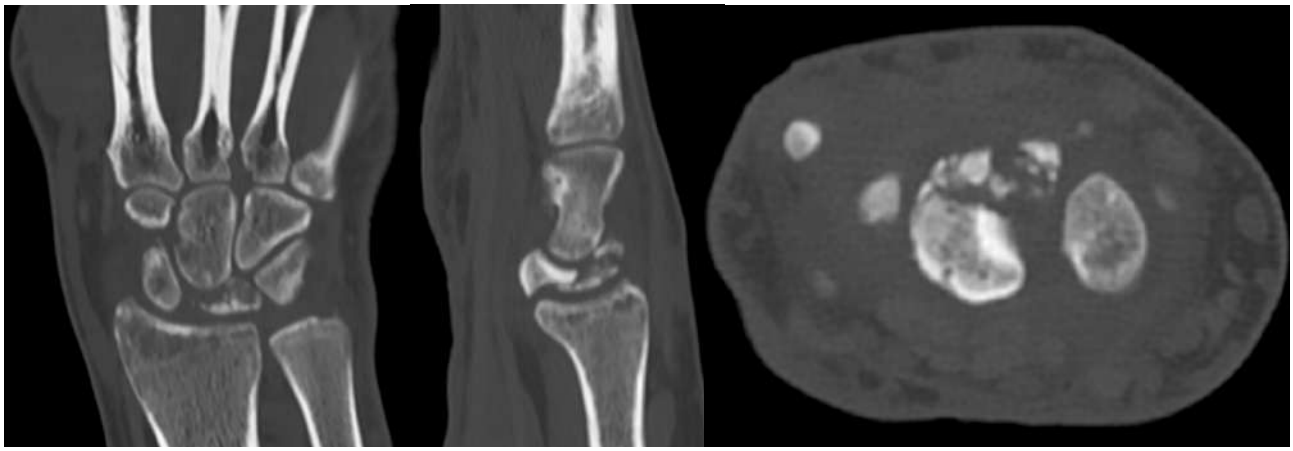

Fig. 3 Preoperative CT showed collapse and fragmentation of the lunate.

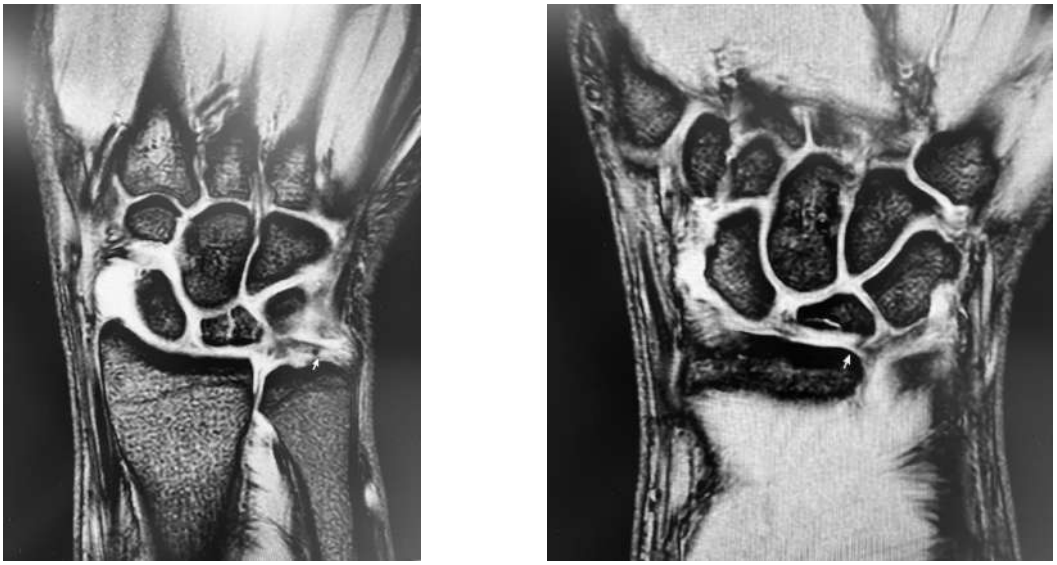

Fig. 4 Preoperative MRI showed that the lunate density was uneven and the height and width of lunate were collapsed.

The prosthesis shape was designed by tomographic image processing and segmentation using technology compared with the intact side and 3D postprocessing technologies (Fig. 5). We used the Electron Beam Melting (EBM) process which allows to obtain devices with excellent mechanical properties and osteointegrating. The custom medical device is made in Titanium.

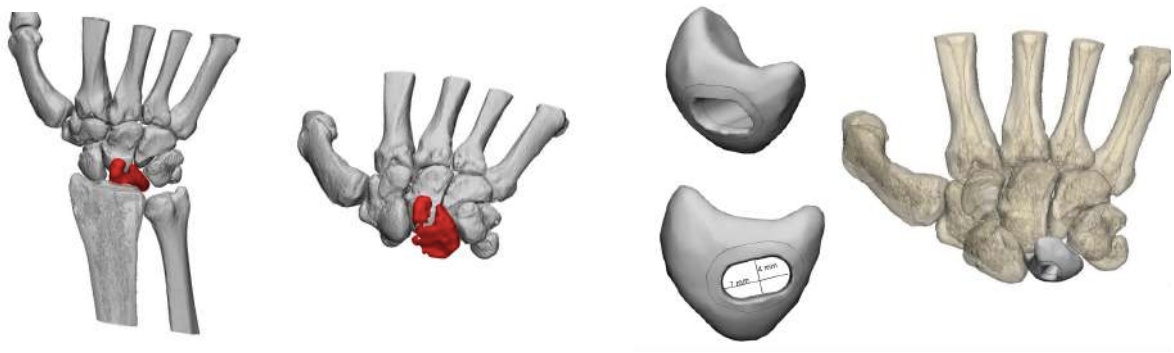

Fig. 5 Custom lunate reconstruction

Surgical Procedure

The surgery was performed in a supine position under a brachial plexus block. We perform a dorsal approach. The extensor retinaculum incision is made centered on Lister's tubercle to expose the extensor tendons from the second to fourth dorsal compartments. The radoiocarpal capsular flap is harvested according to description of Berger-Bishop (Berger and Bishop, 1995) to expose the carpal bones. Next the lunate bone was resected. The cartilages of capitate and radius showed no signs of osteoarthritis (Fig. 4) . Necrotic or inflammatory tissues were removed.

Fig. 4 The necrotic lunate
was resected.

Two small transverse incisions allowed access to harvest one-third of the flexor carpi radialis tendon (FCR) from its musculotendinous junction to the tuberosity of the scaphoid.

A drill hole is created in the scaphoid by passing a K-wire from dorsal to palmar. The K-wire is started in the distal dorsal base of the scaphoid and then drilled in an oblique fashion to exit the bone palmarly just proximal to the proximal pole. The position of the K-wire is confirmed with X-rays. The K-wire tract is then enlarged with a 2.2 mm cannulated drill to allow for tendon passage. A similar procedure is performed at the triquetrum. Here the K-wire is passed from the dorsal ulnar margin to the central aspect of radial surface of the triquetrium. The K-wire tract is then enlarged with a cannulated drill.

The tendon is passed sequentially through the scaphoid, the hole in the Lunate prosthesis and throught the triquetrum. Tendon passage is facilitated by using an 18 gauge spinal needle and a tendon passer, or a simple wire loop.

The remaining tendon is sutured on itself joining both ends tendon (Fig. 5). The tension and the position of the lunate is now examined under X-ray. The radiological stability of the prosthesis was checked in dorsal extension, palmar flexion, radial deviation and ulnar deviation of the wrist (Fig. 6).

Fig. 5 The tendon was passed through the scaphoid and the triquetrum, and the remaining was sutures in itself.

Fig. 7 Capsular flap repaired.

Non-resorbable sutures were used. The capsular flap is repaired with suture and the extensor retinaculum is repaired with 3-0 Vicryl suture (Fig. 7). The skin incisions are now closed with 4-0 nylon suture.

Fig. 6 The prosthesis was check to be not dislocated during dorsal extension, palmar flexion, radial and ulnar deviation of the wrist.

Fig. 7 Postoperative X-rays showed the prosthesis was placed in the original anatomic position

Postoperative Mangement

The wrist was fixed with a cast in the functional position for 4 weeks, then started functional exercises of dorsiflexion and flexion to improve the range of wrist motion. From the tenth week can be initiated a progressive strengthening exercise program.

Discussion

Kienböck's disease is an unfortunate diagnosis at any stage but particularly problematic when the lunate is unsalvageable. None of the options available at this point are ideal, including the method described in this case[11,12].
For advanced stages (greater than IIIA), as in the case of our patient, salvage procedures are carried out, such as resection or arthroplasty of the lunate, intracarpal arthrodesis, and resection of the first row of the carpus[8]. Total wrist fusion has the obvious detriment of sacrificing all motion but with the advantage of a reliable and consistent result. Limited

wrist fusions, STT and SC, create an incongruent articulation with load concentration between the scaphoid and radius which limits motion and wears out over time[13]. Proximal row carpectomy also creates an incongruent articulation with load concentration between the capitate and radius which wears out over time[6].
If the cartilage of the radius and capitate were intact in stage IIIc and the surgeon maximum reserve articular cartilage and joint activity, the lunate prosthesis was an alternative.The theoretical benefits of lunate prosthetic replacement are more normal joint kinematics and the creation of a more congruent articulation with wider load distribution compared to STT/SC fusion or PRC, albeit with a foreign material[14]. Secondly prosthetic replacement can be revised to any of the other traditional approaches, but the same is not true in the opposite direction. However, lunate replacement have not been popular because of the congruity and inherent instability. In relation to this, we consider that custom prosthesis provide a series of benefits with respect to the old standard prosthesis found on the market. First this type of technology achieves a tight match between the three carpal bones, avoiding any type of impairment and posterior osteoarthritis. On the other hand, the stability of these implants represents a problem, because even with an anatomically normal lunate, loss of the scapholunate (SLIL) and lunotriquetral (LTIL) interosseous ligaments integrity poses a major challenge for hand and wrist surgeons[15]. With this custom lunate prosthesis we achieve an implant whose stability was certified by creating a tunnel in it, taking into account the rotation of the wrist, through which the tendon graft passes.

We believe that arthroplasty of the lunate bone with a custom prosthesis for advanced stages of the disease represents a valid option. Compared with the previous report about lunate implantation this prosthesis shows the preservation of adjacent congruity. However, like any surgical procedure, it is not exempt from complications.

References

1- Wagner JP, Chung KC (2005) A historical report on Robert Kienbock (1871–1953) and Kienbock's disease. J Hand Surg Am 30:1117–1121
2- Innes L, Strauch RJ. Systematic review of the treatment of Kienböck's disease in its early and late stages. J Hand Surg [Am]. 2010;35:713–7.
3- Lichtman DM, Lesley NE, Simmons SP (2010) The classification and treatment of Kienbock's disease: the state of the art and a look at the future. J Hand Surg Eur Vol 35:549–554
4- Tatebe M, Hirata H, Iwata Y, et al. Limited wrist arthrodesis versus radial osteotomy for advanced Kienböck's disease—for a fragmented lunate. Hand Surg. 2006;11:9–14.
5- Arora R, Lutz M, Deml C, et al. Long-term subjective and radiological outcome after reconstruction of Kienböck's disease stage 3 treated by a free vascularized iliac bone graft. J Hand Surg [Am]. 2008;33:175–81.
6- Croog AS, Stern PJ. Proximal row carpectomy for advanced Kienböck's disease: average 10-year follow-up. J Hand Surg [Am]. 2008;33:1122–30.
7- De Smet L, Robijns PH, Degreef I. Proximal row carpectomy in advanced Kienböck's disease. J Hand Surg (Br). 2005;30: 585–7.
8- Sauerbier M, Trankle M, Erdmann D, et al. Functional outcome with scaphotrapeziotrapezoid arthrodesis in the treatment of Kienböck's disease stage III. Ann Plast Surg. 2000;44:618–25.
9- Bain GI, Yeo CJ, Morse LP (2015) Kienbock disease: recent advances in the basic science, assessment and treatment. Hand Surg 20:352–365

10- Lichtman D.M., Pientka W.F., II, Bain G.I. The future of Kienböck's disease: a new algorithm. In: Lichtman D.M., Bain G.I., editors. Kienbock's Disease: Advances in Diagnosis and Treatment. Springer; New York: 2016. pp. 307–320.
11- Mir X, Barrera-Ochoa S, Lluch A, et al. New surgical approach to advanced Kienböck disease: lunate replacement with pedicled vascularized scaphoid graft and radioscaphoidal partial arthrodesis. Tech Hand Upper Extrem Surg. 2013;17:72–9.
12- Nakamura R, Horii E, Watanabe K, et al. Proximal row carpectomy versus limited wrist arthrodesis for advanced Kienböck's disease. J Hand Surg (Br). 1998;23:741–5.
13- Yasuda M, Masada K, Takeuchi E, et al. Scaphotrapeziotrapezoid arthrodesis for the treatment of Lichtman stage 3B Kienböck disease. Scand J Plast Reconstr Surg Hand Surg. 2005;39:242–6.
14- Parker WL, Rizzo M, Moran SL, et al. Preliminary results of nonconstrained pyrolytic carbon arthroplasty for metacarpophalangeal joint arthritis. J Hand Surg [Am]. 2007;32: 1496–505.
15- Henry M (2014) Outcomes assessment of lunate replacement arthroplasty with intrinsic carpal ligament reconstruction in Kienbock's disease. Hand(NY)9:364–369.