Arthroscopic Management of Scaphoid Non-union. A Case Report.

Julieta Fioriello[1] MD, Joaquim Casañas[2] MD, Pablo Lopez-Osornio[3] MD,

Teknon Center, Traumaunit, Barcelona, Spain

May, 2021

Summary

Case: A 26-year-old man presented with left wrist pain. He remembered a 2-year history of trauma to the right wrist, which required immobilization. Radiographs and computed tomography (CT scan) showed an unstable scaphoid waist non-union. Bone reconstruction was performed with cancellous graft of the distal radius by arthroscopy, and fixed with a percutaneous headless compression cannulated screw. The patient was found asymptomatic with full range of motion in the last clinical control at 6 months of follow-up.

Conclusions: This case shows that reconstruction of scaphoid waist non-union with collapse and bone loss can be successfully treated using only cancellous bone graft with arthroscopic assistance. Advantages include marked simplification of surgical carpentry, the use of local autograft, rapid incorporation of cancellous bone without compromise of scaphoid reduction and carpal alignment, and a short period of consolidation and recovery. On the other side, open procedures could impair the limited blood supply to the scaphoid and could damage the palmar radiocarpal wrist ligaments, which may then result in carpal malalignment and loss of proprioception of the wrist.

Keywords: wrist arthroscopy, scaphoid non-union, pseudoartrosis, cancellous graft.

(1) Upper Limb Surgery, CLIMBA Center (Clínica de la Mano de Buenos Aires), Buenos Aires, Argentina.
(2) Director of Traumaunit and Peripheral nerve, Teknon Center, Traumaunit, Barcelona, Spain.
(3) Upper Limb Surgery, Teknon Center, Traumaunit, Barcelona , Spain

Email Address: juli_fioriello@hotmail.com

Introduction

The non-union rate after scaphoid fracture is relatively high. Even when scaphoid fractures are adequately treated using casts, the reported non-union rate has been as high as approximately 10%.[1]

Scaphoid non-union results in abnormal wrist kinematics and typically leads to carpal collapse, and a subsequent degenerative arthritis of the wrist.[2]The natural history of scaphoid non-union may vary because of the fracture location.[2, 3]

Nakamura et al have reported two different patterns of displacement, namely, volar and dorsal, in scaphoid non-union. Distal scaphoid waist fractures usually develop in a volar-type pattern and are accompanied by DISI and humpback deformity of the scaphoid. In contrast, proximal scaphoid waist and pole fractures frequently develop in a dorsal-type pattern and are accompanied by a minor displacement of the scaphoid and carpal bones.[3] Moritomo et al revealed that the fracture line of scaphoid nonunion in volar-type displacement is distal to the scaphoid apex (distal type) and that of scaphoid nonunion in dorsal-type displacement is proximal to the scaphoid apex (proximal type).[4] (Fig.1)

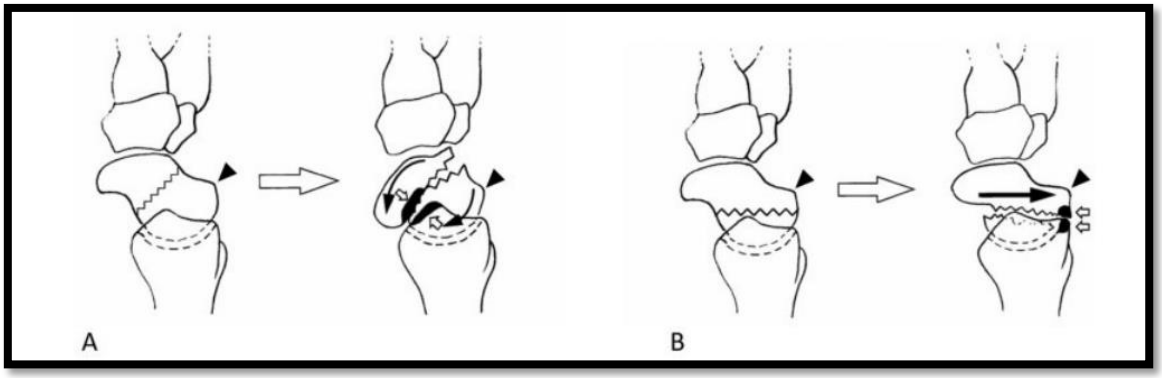

Fig. 1 Black triangles indicate the apex of the dorsal scaphoid ridge. **(A)** The volar type of scaphoid nonunion, as seen from the lateral view, showing the direction of fracture displacement (solid arrows) and the inferred contact area between the distal fragment of the scaphoid and the radius (open arrows). **(B)** The dorsal type of scaphoid nonunion. *From Moritomo et al (2000)*

Slade and Dodds described a classification of scaphoid non-union into six grades.[5] They proposed that in fractures where there is delayed presentation, fibrous nonunion and minimal sclerosis (grades I, II and III), rigid fixation alone is sufficient to achieve union. However, if there is bone loss without significant flexion deformity (grades IV and V), bone grafting is then required to achieve union. They also felt that non-unions with more advanced resorption (grade VI) require open debridement and interpositional cortico-cancellous structural bone grafting to provide structural support with viable bone matrix. (Table 1)

Table 1 TREATMENT CLASSIFICATION SYSTEM OF SCAPHOID NONUNIONS		
Grade	**Category**	**Characteristics**
I	Delayed presentation	Scaphoid fractures with delayed presentation (4–8 weeks)
II	Fibrous nonunion	Intact cartilaginous envelope, minimal fracture line at no-nunion interface, no cyst or sclerosis
III	Minimal sclerosis	Bone resorption at no-nunion interface < 1 mm with minimal sclerosis
IV	Cyst formation and sclerosis	Bone resorption at nonunion interface < 5 mm, cyst formation, and maintained scaphoid alignment
V	Cyst formation and sclerosis	Bone resorption at nonunion interface > 5 mm and < 10 mm, cyst formation, and maintained scaphoid alignment
VI	Pseudoartrosis	Separate bone fracture fragments with profound bone resorption at nonunion interface. Gross fragment motion and deformity is often present
Subtypes	**Category**	**Associated Characteristics**
A	Proximal pole nonunion	The proximal pole has a tenuous blood supply and a mechanical disadvantage that places it at greater risk of delayed or failed union
B	Avascular necrosis	Scaphoid nonunion with avascular necrosis confirmed by MRI or intraoperative lack of punctate bleeding. The fracture must heal and Revitalize
C	Ligamentous injury	Injury suggested by static and dynamic imaging of the carpal bones or arthroscopic, direct observation
D	Deformity	Scaphoid deformity must be corrected. This requires a bicortical structural bone graft and rigid fixation

From Slade and Dodds (2006)

More recent evidence has shown percutaneous fixation alone can be successful for treating stable scaphoid non-unions connected with fibrous tissue or intact cartilaginous cap, and demonstrated that extensive bone resorption at the fracture site is not an absolute indication for bone grafting.[6] However, fracture stability can be difficult to assess using closed means and most surgeons may be reluctant to proceed with percutaneous fixation alone when faced with substantial bone resorption and cyst formation seen on CT- scan. The advent of wrist arthroscopy has provided a minimally invasive means of assessing scaphoid pathology. It allows direct assessment of fracture stability without causing significant surgical trauma to the ligamentous architecture and vascularity.[7]

The choice of this case was motivated by the alternative in using the arthroscopic assistance for reconstruction of the unstable scaphoid non-union. I have had the opportunity to evaluate this patient six months after surgery, with excellent functional results. In addition, I have seen the surgical technique on another similar case during my fellowship at Teknon Center.

I believe that, based on current evidence and the good results obtained, the treatment of unstable scaphoid nonunion with arthroscopy is a technique that every Hand Surgeon should offer to their patients as it provides great advantages over open surgery.

Case Report

A 26-year-old man presented with pain in the left wrist for 1 week. The pain started after lifting a weight. He remembered a 2-year history of trauma to the right wrist, which required immobilization.

On physical examination, he had full and symmetric passive and active range of motion. On palpation, he had tenderness on the snuff box.

An anterior-posterior x-ray revealed the presence of non-union fracture of scaphoid waist, without significant flexion deformity (Figure 2). CT-scan images showed a gap greater than 1 mm, with sclerosis and cysts formations (Figure 3). X-ray and CT were

both consistent with a scaphoid non-union fracture grade IV according to Slade and Dodds Classification.[5]

Fig 2. X- Ray showing scaphoid waist non-union fracture with sclerosis, without significant flexion deformity (**A**: AP view; **B**: Lateral view; **C**: AP with ulnar deviation)

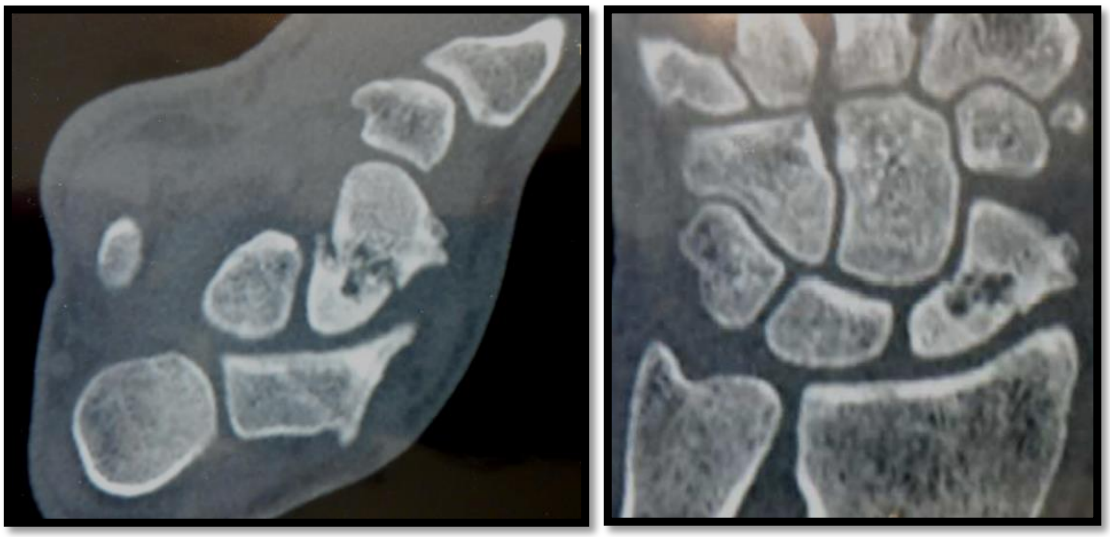

Fig 3. Coronal CT showing scaphoid non-union fracture grade IV with sclerosis and cysts formatios.

Percutaneous fixation of the fracture with a cancellous graft using wrist arthroscopy was proposed, because we consider that arthroscopic management of wrist provide a minimally invasive way of checking scaphoid pathology. It allows direct assessment of fracture stability without causing significant surgical trauma to the ligamentous architecture and vascularity.[7]

Surgical Procedure (Video)

Wrist arthroscopy was performed under a brachial plexus block with the forearm on a traction tower.

First, an inspection of the radio and midcarpal joints was performed to assess the state of the articular cartilage, the intrinsic ligaments, and the triangular fibrocartilage complex. The scapholunate ligament was assessed using the classification described by Geissler et al.[8] (Table 2)

Table 2
ARTHROSCOPIC CLASSIFICATION OF TEARS OF THE INTRACARPAL LIGAMENTS

Grade	**Description**
I	Attenuation or hemorrhage of interosseous ligament as seen from radiocarpal space. No incongruency of carpal alignment in mid-carpal space.
II	Attentuation or hemorrhage of interosseous ligament as seen from radiocarpal space. Incongruency or step-off of carpal space. There may be slight gap (less than width of probe) between carpal bones.
III	Incongruency or step-off of carpal alignment as seen from both radiocarpal and mid-carpal space. Probe may be passed through gap between carpal bones.
IV	Incongruency or step-off of carpal alignment as seen from both radiocarpal and mid-carpal space. There is gross instability with manipulation. 2.7-millimeter arthroscope may be passed through gap between carpal bones.

From Geissler et al (1996)

The midcarpal portals were used for assessment of the scaphoid. Using either the radial or ulnar midcarpal portal as the viewing portal, a probe was introduced through the other midcarpal portal to assess stability of the fracture. There was visible mobility of the scaphoid fragments on ballottement test, for which the fracture was considered unstable, and we performed arthroscopic bone grafting and percutaneous fixation with a screw.

Through an appropriate working portal opposing the fracture, the non-union site was thoroughly debrided using a combination of shaver, burr and curette until vascularised cancellous bone was exposed. The vascularity of the fragment was examined by observing punctate bleeding.

We made a temporary fixation with a guide wire, properly placed along the central axis of the scaphoid, to maintain the reduction. Then, we harvested autologous bone graft from the distal radius, using a mini-approach on the Lister's tubercle, and introduced by cannula through the accessory portal opposite the fracture under dry arthroscopy.

The traction arm was then removed, and complete filling of the defect and satisfactory alignment of the scaphoid was confirmed fluoroscopically.

Fracture fixation with a cannulated headless compression screw was performed percutaneously through a dorsal approach, using the K-wire as guide.

We finished checking the procedure, by fluoroscopic and direct arthroscopic view.

Postoperative management

The patient had a cast immobilization extending up to the metacarpophalangeal joints of the hand, excluding the thumb metacarpophalangeal joint. The cast was removed at 3 weeks regardless of radiological findings, and then active wrist motion was allowed.

He was reviewed at regular intervals until consolidation was confirmed radiologically by CT, which was achieved at 7 weeks. At the final control, 6 month after surgery, the mean flexion–extension arc of the operated wrist was approximately 90% of the contra lateral normal wrist, and without pain. (Fig. 4 and 5)

The patient returned to his pre-injury activity level. There were not intraoperative nor post-operative complications.

Fig. 4 X-ray and TC control at 6 month of follow up showing fracture consolidation.

Fig. 5 The patient at 6 month of follow up with good motion of his wrist and without pain**.**

Discussion

The non-union rate after scaphoid fracture is relatively high. The natural history of this pathology results in abnormal wrist kinematics, and typically leads to carpal collapse and a subsequent degenerative arthritis of the wrist.

This case shows that reconstruction of scaphoid waist non-union, with collapse and bone loss, can be successfully treated using only cancellous bone graft with arthroscopic assessment.

The advantages include being a minimally invasive procedure, allowing direct access to the fracture without damage to capsular and ligament structures, preserving

vascularization and proprioception of the carpus. In addition, it allows the use of a local cancellous bone graft, providing a biological contribution.

I have had the possibility to observe the surgical technique in one patient and the final follow-up in another patient. It has allowed me to take a complete notion of the arthroscopic treatment of the scaphoid non-union, its post-surgical management and the good results obtained with this technique.

I believe that every Hand Surgeon should handle this tool, as it offers advantages over open surgery. On the other hand, the learning curve is slow and requires a lot of training. I consider appropriate that Upper Limb Fellowships should have adequate practice in wrist arthroscopy, because is no longer the tool of the future, being now part of our present.

Acknowledgement

I thank Joaquim Casañas MD, Director of Traumanit and Peripherical nerve, Teknon Center of Barcelona, for inspiring me to adopt wrist arthroscopy in the treatment of scaphoid pathology, and for transmit to me his deep knowledge of the pathology related with brachial plexus and peripherical nerves injuries.

References

1- Garala K, Taub NA, Dias JJ. The epidemiology of fractures of the scaphoid: impact of age, gender, deprivation and seasonality. Bone Joint J 2016, 98-B (05):654–659.

2- Mack GR, Bosse MJ, Gelberman RH, Yu E. The natural history of scaphoid non-union. J Bone Joint Surg Am 1984, 66(04):504–509.

3- Nakamura R, Imaeda T, Horii E, Miura T, Hayakawa N. Analysis of scaphoid fracture displacement by three-dimensional computed tomography. J Hand Surg Am 1991, 16(03):485–492

4- Moritomo H, Murase T, Oka K, Tanaka H, Yoshikawa H, Sugamoto K. Relationship between the fracture location and the kinematic pattern in scaphoid nonunion. J Hand Surg Am 2008, 33(09):1459–1468.

5- Slade JF 3rd, Dodds SD. Minimally invasive management of scaphoid nonunions. Clin Orthop Relat Res. 2006, 445: 108-19.

6- Mahmoud M, Koptan W. Percutaneous screw fixation without bone grafting for established scaphoid nonunion with substantial bone loss. J Bone Joint Surg Br. 2011, 93: 932–6

7- Wong WYC, Ho PC. Minimal invasive management of scaphoid fractures: from fresh to nonunion. Hand Clin. 2011, 27: 291–307.

8- Geissler WB, Freeland AE, Savoie FH, McIntyre LW, Whipple TL. Intracarpal soft-tissues lesions associated with an intraarticular fracture of the distal end of the radius. J Bone Joint Surg Am. 1996, 78:357-65.