CLINICAL CHANGES IN PATIENTS WITH PLANTAR FASCIITIS TREATED WITH EXTRACORPOREAL SHOCKWAVE THERAPY

Marianyi P. Martinez

Marcio Freitas

Luis Marchi

Mauro Dinato

Instituto Vita, São Paulo, Brazil

ABSTRACT

Extracorporeal shock wave therapy (ESWT) is an option of conservative care for patient that experience plantar fasciitis. The aim of this study was to study the clinical and radiological baseline parameters of a case series and describe the clinical outcomes after the ESWT. Thirty-two (32) patients were included (56% female, mean age 50.7 y.o., mean duration of the symptoms 16.4 months). The outcomes were analyzed in a mean follow-up time was 4.8 months. The MRI images evidenced signs of soft tissue edema in 56% of the patients, signs of bone edema in 78%, instrasubstance lesion in 53%, and fascia ticker than usual with a mean dimension of 4.6mm. After the treatment it was possible to observe that less patients referred limitation to walk (19% vs 97%, $p<0.001$), limitation to run (47% vs 100%, $p<0.001$), and pain after waking up (22% vs 100%, $p<0.001$). Any patient complained about ESWT-related adverse events, and up to the final FUP there was no need for surgical treatment. In this study we could observe good clinical outcomes after the ESWT for patients with plantar fasciitis.

Keywords: foot; plantar fasciitis; extracorporeal shockwave therapy

INTRODUCTION

Plantar fasciitis is a common chronic musculoskeletal disorder characterized by pain in the plantar fascia region; the most affected area of pain is the origin of the fascia, in the medial-plantar region of the heel near the medial tubercle of the calcaneus (1,2).

Approximately 10% of the population has suffered or will suffer foot pain throughout their lives, specifically, pain in the plantar fascia, which we call plantar fasciitis. According to the World Health Organization (WHO), plantar fasciitis is one of the most frequent reasons for consultation in rehabilitation and trauma services. It is a problem that, day by day, affects a significant percentage of the world's population (1,9).

Plantar fasciitis (PF) is the most common cause of heel pain and accounts for up to 15% of 33-foot symptoms requiring medical attention. It is associated with significant morbidity, resulting in activity limitations for affected patients. PF is believed to be caused by biomechanical overloading of the plantar fascia insertion at the calcaneal tuberosity. Mechanical overload, whether because of biomechanical deviations, obesity, or prolonged standing work habits, may contribute to symptoms (1,5,7).

There is a strong tendency towards spontaneous resolution, but in the proportion of patients a chronic syndrome may develop, and further treatment may be required, a variety of conservative treatments have been proposed for this condition, stretching exercises, heel lifts, non-steroidal anti-inflammatory drugs (NSAIDs) and steroid injection into the painful area, among others. A small percentage of patients finally had an open release of the plantar fascia, but the results were not always predictable or satisfactory (1,4,5,6,7).

Surgical treatments such as plantar fasciotomy have been recommended when non-surgical treatments fail. Recently, the development of extracorporeal shock wave therapy (ESWT) for the plantar surface of the heel has added a new dimension to the treatment of plantar fasciitis, the success rate of ESWT, which is based on subjective symptomatic relief of heel pain, remains variable (8)

Magnetic resonance imaging (MRI) is used for the diagnosis of plantar fasciitis, Objective evaluation can be done using magnetic resonance imaging (MRI) findings, which include increased thickness of the plantar fascia, bone marrow edema, and formation of a calcaneal spur (osteophyte) (7).

The hypothesis was that the patients with plantar fasciitis would experience a positive change in clinical outcomes after the treatment with shockwave method.

METHODS

This was an observational, retrospective, prospective, case series, single center study with data medical charts study.

Inclusion criteria: Adult individuals diagnosed with more than six (6) months of plantar fasciitis; Individuals with previous MRI study; Failed treatment with NSAIDs, steroids, and insoles; Prescribed and performed treatment with ESWT. Exclusion criteria: Chronic systemic disease, such as neuropathies, rheumatologic diseases, tumors, and local infection; patients who did not comply with the indicated sessions.

After being included in the study, the medical records will be studied so that the data pertinent to this study can be extracted. The researchers contacted the patient by telephone if to complete the data as needed for the study.

Baseline data collected were: sex, age, duration of the symptoms (months), limitation to walk (yes/ no), limitation to run (yes/ no), pain after waking up (yes/ no). Pre-treatment MRI images were analyzed, and the following parameters were extracted: sings of soft tissue edema (yes/ no), signs of bone edema (yes/ no), thickness of the fascia (in millimeters, measured as shown in Figure 1), fascia rupture (yes/ no), sings of intrasubstance lesion (yes/ no), osteophytes (yes/ no). The clinical outcomes collected before the treatment and at the final follow-up were: limitation to walk (yes/ no), limitation to run (yes/ no), pain after waking up (yes/ no). ESWT-related adverse events were collected.

A descriptive analysis of the data collected was performed. Qualitative parameters pre- and post-ESWT were compared using Fisher test. The significance level adopted will be $p<0.05$ (SPSS®).

RESULTS

Thirty-two (32) patients were included and analyzed in this work. The mean follow-up time was 4.8 months (2.5, standard deviation). Table 1 shows demographic and baseline data of the study group.

Table 1. Demographic and baseline data

Patients (n)	32
Female	56%
Age	50.7 ± 9.5
Duration of the symptoms (months)	16.4 ± 22.9

Data are shown as mean ± standard deviation

Table 2 shows the radiological description of the patients from this study. As sing of the inflammatory process, the fascia was swollen, as the thickness values demonstrates. Bone edema was very prevalent, and an example can be found in Figure 2. Few cases had a fascia rupture (Figure 3), but most patients had inflammatory signs with instrasubstance lesion (Figure 4) and almost half presented osteophytes (Figure 5).

Table 2. Baseline radiological data

Signs of soft tissue edema	56%
Signs of bone edema	78%
Fascia tickness (mm)	4.6 ± 0.8
Signs of fascia rupture	12%
Instrasubstance lesion	53%
Osteophytes	47%

Data are shown the percentage of the patients that presents such criterium and as mean ± standard deviation

Before the treatment, all patients had limitation to run and pain after waking up (Table 3). At the final follow-up visit, the prevalence of patients referring pain at the morning was 22%. Moreover, it was possible to evidence that more than half of the group could run without pain again and the limitation to walk decreased from 97 to 19% of the patients (all differences with statistical significance).

Table 3. Clinical baseline data and outcomes

	Pre	Post	*P* value
Limitation to walk	97%	19%	<0.001
Limitation to run	100%	47%	<0.001
Pain after waking up	100%	22%	<0.001

Data are shown the percentage of the patients that presents such criterium

ESWT-related adverse events were not observed in this group. In addition, no patient evolved with the need for surgery

DISCUSSION

The present observational study evaluated the efficacy of shockwaves in the treatment of chronic plantar fasciitis. It was observed that shockwaves achieved significant decreases in clinical outcomes evaluated as limitation in walking, running, and pain after waking, without obtaining any reported adverse effects related to the procedure, nor need for surgery. MRI findings usually show increased signal intensity on T2-weighted sequences in the fascia region reflecting a thickening that occurs most commonly in the heel, intrasubstantial areas of intermedial signal on T1-weighted and increased signal intensity on fluid-sensitive sequences, edema in adjacent tissues around the fascia and medullary edema in the heel (10). Similarly Zhu et al. referenced that imaging assessment of somatic changes after treatment would allow us to better understand ESWT and could prove valuable in the evaluation and selection of patients and the treatment planning process, objective measures such as MRI imaging would clarify some of the controversies regarding the efficacy and mechanism of action of ESWT (8)

Shockwave therapy was approved for the treatment of plantar fasciitis in 2000 by the US. Food And Drug Administration. It is considered an easy, effective and safe therapy, and additionally can be an alternative to surgical treatment with a low complication rate and treatment cost.

Another study discusses the effectiveness of shock waves in other pathologies such as Peyronie's disease and complex regional pain syndrome (RSD to reflex sympathetic dystrophy), knee osteoarthritis, spinal fusion, malignant cells and gene therapy. In addition, the application of ESWT has been extended to non-musculoskeletal diseases. (11)

Bicer et al. in their study with 30 patients, after treatment with shock waves, 70% were able to stand for more than 5 hours, the activity in the morning and the pain improved significantly, in addition there was a significant improvement in pain after walking (12)

Similarly, another retrospective study of 225 patients with plantar fasciitis observed an improvement on the AOSFAS scale with a success rate of 70.7% at 3 months and 77.2% at 12 months of shockwave treatment. Previous steroid use, body mass index and duration of symptoms do not seem to have shown an influence on the results (13)

When comparing 5 sessions of shockwave treatment with steroid use in a single intrafascia injection in a randomized design study, there was a significant improvement in symptoms assessed by the VAS (visual analog score) and the FFI (Foot Function Index) and patient satisfaction assessed by the 4-point Likert scale with both treatments, the main treatment effect showed no significant differences between the arms, but more than half of the patients (55-60%) in the group allocated to shockwave treatment achieved therapeutic success in the VAS and FFI score at 8 weeks compared to steroid treatment (35-40%) at the end of the study (14)

Elsewhere. A prospective study of 44 patients randomized to standard treatment (insole and exercise program) versus standard treatment but shockwave therapy with diagnosed plantar fasciitis concluded that both treatment arms improved the patients' functional performance after three months of treatment, findings seen mainly due to no significant difference in AOFAS-F score (American othopedic foot and ankle society Score) and walking speed (15).

Thus, even though there was no significant difference in the benefit observed with shockwave treatment versus placebo in a double-blind randomized trial at 6 and 12 months of treatment, the authors of this study conclude that there is no evidence to support beneficial effects on pain, function, and quality of life with shockwave treatment (16).

The limitations of the present were the following: it was a retrospective study, - not comparative, In addition, the number of patients was low and no long-term radiological follow-up was performed after treatment with shock wave therapy.

The results of this confirm the clinical efficacy of ESWT for chronic plantar fasciitis, shock wave therapy is an effective and simple treatment for those long-standing plantar fasciitis that do not respond to conventional treatment, because they have been shown to produce positive results. regarding pain and function in patients. Magnetic resonance imaging is useful not only for diagnosis, but can also be used to assess the response to treatment of plantar fasciitis. Further studies are recommended to investigate and explore these findings.

FIGURES

Figure 1. A 64-year-old Male patient thickening and elevation of signal in the proximal portion of the fascia (green line), predominantly in the central band.

Figure 2. Sagittal T2-weighted images with fat saturation of the hindfoot, soft tissue and perifascial edema associated with subcortical calcaneal bone edema (arrow).

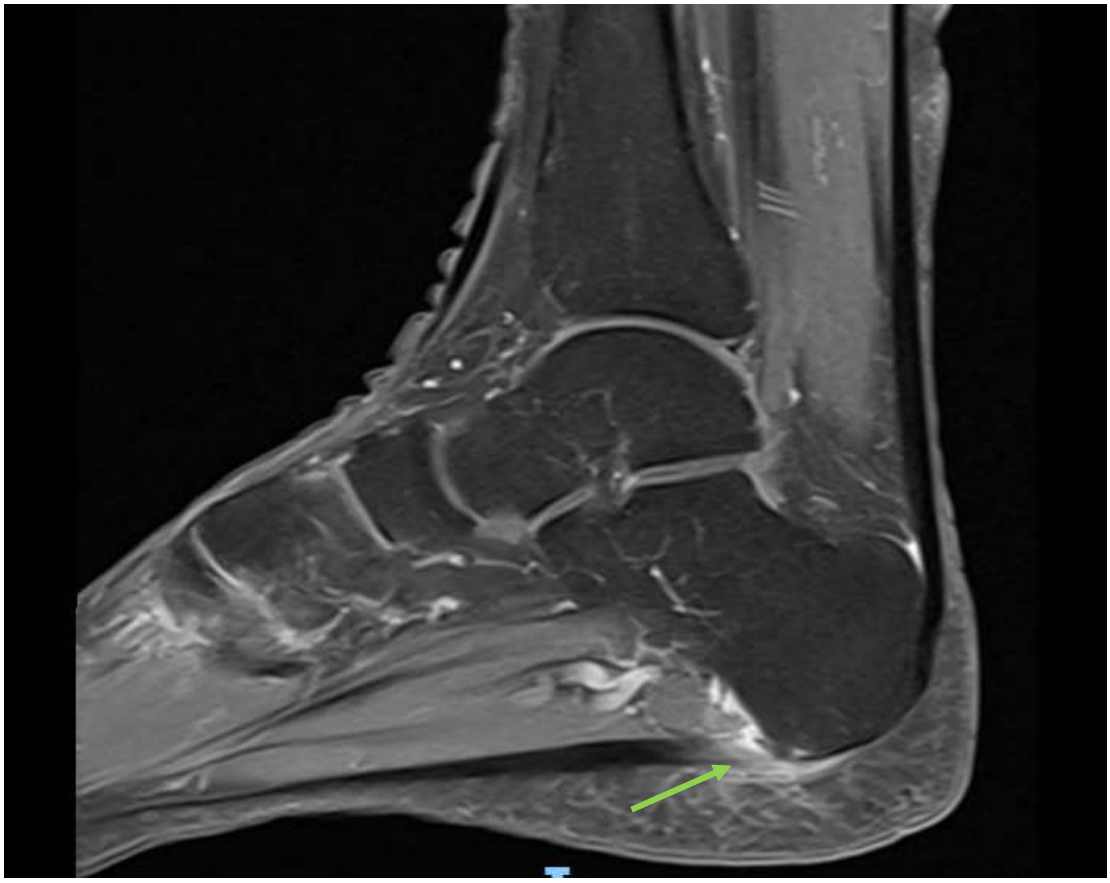

Figure 3. Plantar fasciitis with intrinsic clefts, associated with inflammatory changes in adjacent soft tissues (arrow).

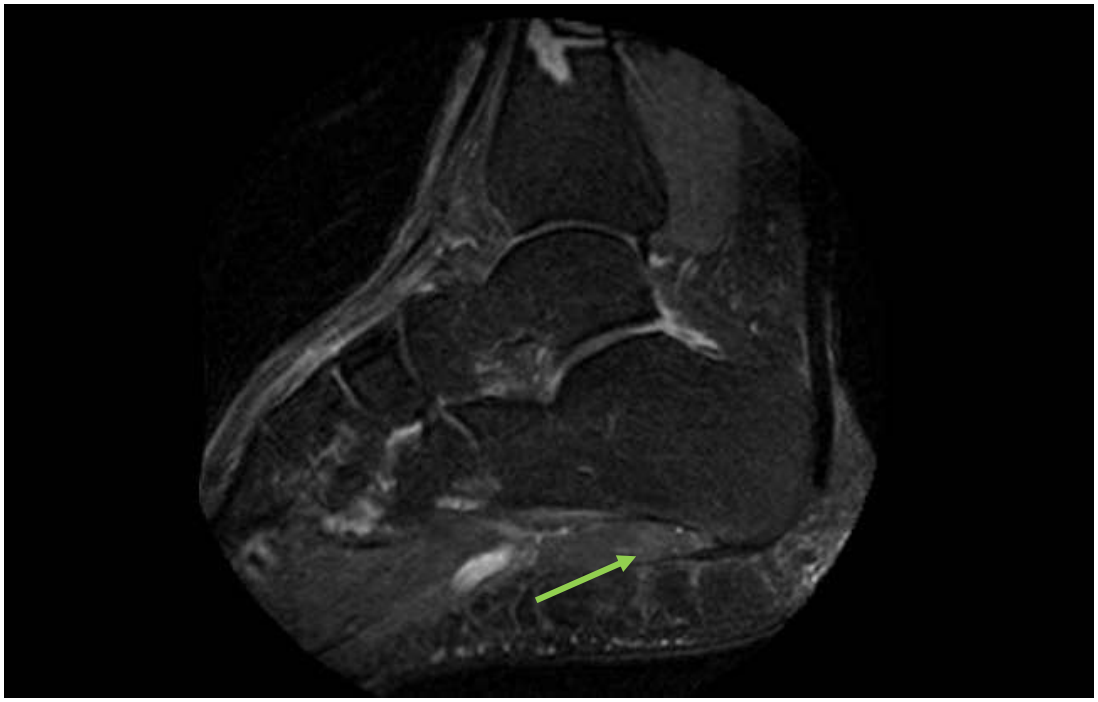

Figure 4. Perifascial edema and intrasubstantial fissures in the proximal segment of the central band, without transfixion (arrow).

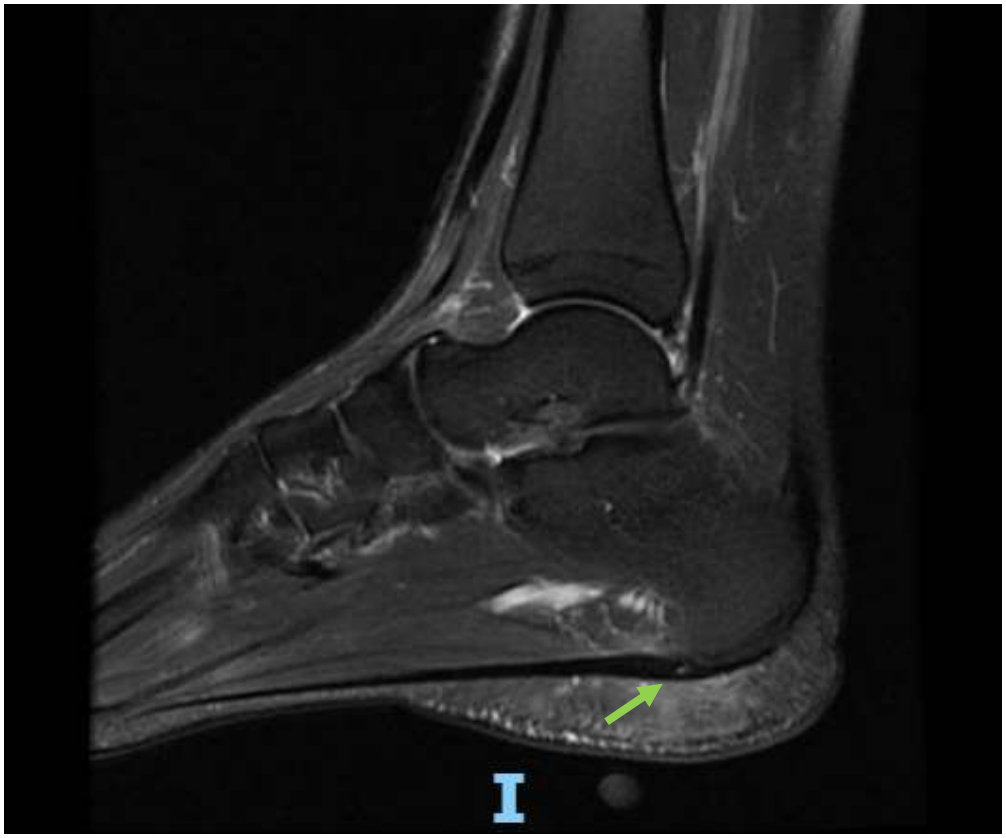

Figure 5. Plantar fasciitis, associated with a small enthesophyte of the calcaneus (arrow).

ACKNOWLEDGMENTS

The radiology department of Fleury Dr. Alipio Ormond for help with the MRI scans at the imaging center. To the fellowship director Dr. Mauro Dinato, thanks for the infinite support that, together with his team (Dr. Freitas, Dr. Tatiana, Dr. Miguel and Dr. Sato), provided me with knowledge and excellent training during my stay. To Luis Marchi, scientific director of the Vita Institute for his unconditional support and finally to The International Bone Research Association (IBRA) for always supporting continuing education, thank you!

REFERENCES

1. Federico G, Andrea B, Müller-Ehrenberg H, Carla S, Stefano M. A global approach for plantar fasciitis with extracorporeal shockwaves treatment. Eur J Transl Myol 2019. 29(3): 171-177.

2. Wearing SC, Smeathers JE, Urry SR, et al. The Pathomechanics of Plantar Fasciitis. Sport Med 2006. 36:585–611.

3. Gerdesmeyer L, Frey C, Vester J, Maier M, Weil L Jr, Weil L Sr, et al. Radial extracorporeal shockwave therapy is safe and effective in the treatment of chronic recalcitrant plantar fasciitis. Am J Sports Med 2008.; 36: 2100-9.

4. Nabeel Dastgir. Extracorporeal shock wave therapy for treatment of plantar fasciitis. J Pak Med Asoc. 2014. 64 (6): 675-8.

5. Roerdink R, Dietvorst M, Van der Zwaard, Van der Worp, Zwerver J. Complications of extracorporeal shockwave therapy in plantar fasciitis: Systematic review. Int J Surg. 2017.46: 133-145.

6. Zwerver J, Waugh C, van der Worp H, Scott A., Can Shockwave Therapy Improve Tendon 384 Metabolism? Adv. Exp. Med. Biol. 2016. 960; 275–281.

7. Bicer M, Hocaoglu E, Aksoy S, İnci E, Aktaş İ. Assessment of the Efficacy of Extracorporeal Shockwave Therapy for Plantar Fasciitis with Magnetic Resonance Imaging Findings. J Am Podiatr Med Assoc. 2018. 108(2):100-105.

8. Zhu F, Johnson JE, Hirose CB, Bae KT. Chronic Plantar Fasciitis: Acute Changes in the Heel after Extracorporeal High-Energy Shock Wave Therapy—Observations at MR Imaging. Radiology, 2005. 234(1), 206–210.

9. García J, Baño A, Piedad M, Sánchez M, Belmonte A, Albaladejo, Martín R. Relación entre el sexo, edad e índice de masa corporal y el Foot Function Index en pacientes con fascitis plantar. Rev. int. cienc. podol. 2018. 13(1): 33-40.

10. Maki M, Ikoma K, Kido M, Hara Y, Sawada K, Ohashi S, et al. Magnetic resonance imaging findings of chronic plantar fasciitis before and after extracorporeal shock wave therapy. Foot [Internet]. 2017;33(October):25–8. Available from: http://dx.doi.org/10.1016/j.foot.2017.10.002

11. Ching-Jen Wang. Extracorporeal shockwave therapy in musculoskeletal disorders. Wang Journal of Orthopaedic Surgery and Research 2012, 7:11

12. Bicer M, Hocaoglu E, Aksoy S, İnci E, Aktasx İ. Assessment of the efficacy of extracorporeal shockwave therapy for plantar fasciitis with magnetic resonance imaging findings. J Am Podiatr Med Assoc. 2018;108(2):100–5.

13. Chuckpaiwong B, Berkson EM, Theodore GH. Extracorporeal Shock Wave for Chronic Proximal Plantar Fasciitis: 225 Patients with Results and Outcome Predictors. J Foot Ankle Surg [Internet]. 2009;48(2):148–55. Available from: http://dx.doi.org/10.1053/j.jfas.2008.11.001

14. Eslamian F, Shakouri SK, Jahanjoo F, Hajialiloo M, Notghi F. Extra corporeal shock wave therapy versus local corticosteroid injection in the treatment of chronic plantar fasciitis, a single blinded randomized clinical trial. Pain Med (United States). 2016;17(9):1722–31.

15. Rachelle Buchbinder, Ronnie Ptasznik, FRANZCR; Jeanine Gordon, BAppSci; et al. Ultrasound-Guided Extracorporeal Shock Wave Therapy for Plantar Fasciitis. A Randomized Controlled Trial. JAMA. 2002;288(11):1364-1372. doi:10.1001/jama.288.11.1364

16. Cinar E, Saxena S, Akkurt HE, Uygur F. Extracorporeal shockwave therapy in the management of plantar fasciitis: A randomized controlled trial. Foot [Internet]. 2020;44(March):101679. Available from: https://doi.org/10.1016/j.foot.2020.101679