Surgical treatment of distal forearm fractures using an external fixator Multifix

Author

Martin Vlček, Dr. Med., Ph.D., Orthopaedic Clinic of First Medical Faculty of Charles University at the University Hospital in Motol in Prague

Introduction

Distal radius fractures are the most common of all fractures. Optimal treatment is still debated. The extensive European studies show, that the most common patient was an eldery woman who sustained a distal radius fracture through a simple fall in her own residence [Rundgren 2020]. Many of these fractures are treated conservatively, but it is preferable to use an external fixator as well [Rosa 2020]. Biomechanical study even revealed superior biomechanical properties of non-bridging external fixation compared to volar locked plating in an unstable intra-articular fracture [Windolf 2010].

Method

The external fixator Mutifix [Fig. 1] is ordinarily used on Unit of Hand Surgery and Microsurgery of Policlinico of Modena for the treatment of distal radius fractures.

The Mutifix bar can be shaped to adapt to the ergonomic needs of the user, without compromising the rigidity characteristics sufficient to guarantee the correct placement of the fixator. The Mutifix bar can be shortened to better adapt to different application conditions. The holes present along the Mutifix bar allow the insertion of K wires in the desired positions, this feature allows the device to adapt to multiple configurations. The advantage is low weight: about 45 grams.

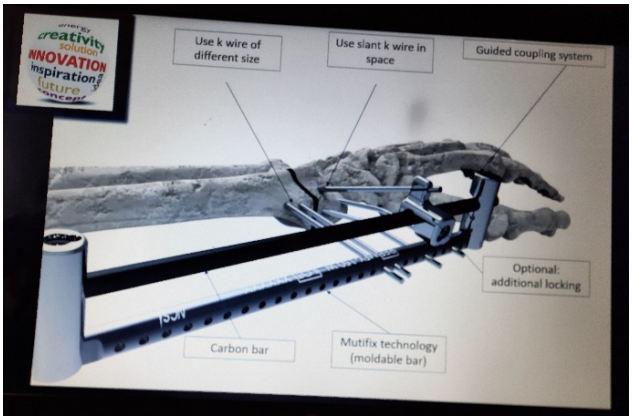

Fig. 1. Mutifix external fixator for distal forearm fracture

Case

Woman, 95 years old, fracture od distal part of radius et ulna on tle left side after a fall while walking:
a) clinical finding after injury
b) posttraumatic X-rays
c) X-rays after attaching the external fixator
d) clinical finding with external fixator
e) X-ray finding with healed fractures in one year after surgery [Fig. 1]

Fig. 2. Distal forearm fracture treated using external fixator Multifix

Discussion

In the elderly patient, conservative therapy using cast fixation was not indicated for soft tissue condition. Stabilization of fractures of distal ends of both bones of forearm using an external fixator allowed to use the limb immediately after its application. Although the method did not provide healing in the anatomical position, a very good functional result was achieved.

Conclusion

Using non-bridging external fixation for treating distal forearm fracture allows some level of wrist movement during the early stage of fixation, effectively maintains the radial length, radial inclination, and palmar tilt, and achieves better outcomes than bridging external fixation [Liu 2020].

Literature

Della Rosa N, Bertozzi N, Adani R. Biomechanics of external fixator of distal radius fracture, a new approach: Mutifix Wrist. Musculoskelet Surg. 2020 Aug 12. doi: 10.1007/s12306-020-00677-5.

Liu Y, Bai YM. Efficacy of non-bridging external fixation in treating distal radius fractures. Orthop Surg. 2020 Jun;12(3):776-783. doi: 10.1111/os.12677.

Rundgren J, Bojan A, Mellstrand Navarro C, Enocson A. Epidemiology, classification, treatment and mortality of distal radius fractures in adults: an observational study of 23,394 fractures from the national Swedish fracture register. BMC Musculoskelet Disord. 2020 Feb 8;21(1):88. doi: 10.1186/s12891-020-3097-8.

Windolf M, Schwieger K, Ockert B, Jupiter JB, Gradl G. A novel non-bridging external fixator construct versus volar angular stable plating for the fixation of intra-articular fractures of the distal radius--a biomechanical study. Injury. 2010 Feb;41(2):204-9. doi: 10.1016/j.injury.2009.09.025.