Postsurgical Volumetric Airway Changes In Class Three Patients Receiving Bimaxillary Orthognathic Surgery

Abstract

Introduction: The purpose of the present study was to investigate the PAS changes in Class III patients receiving bimaxillary orthognathic surgery and correlate the PAS and minimum axial section (MAS) changes with the amount of surgical movement.

Methods: This research involved a retrospective sample composed of 24 patients with occlusal pattern and facial profile of III skeletal occlusions who had CBCT images before and at least 6 months after bimaxillary orthognathic surgery. CBCT data were imported to a virtual planning software and 3D measurements of the PAS and MAS were conducted. Total airway space was subdivided into nasopharyngeal airway space, oropharyngeal airway space. In addition, oropharyngeal airway space further subdivided into lower and upper oropharyngeal airway space. The posterior limit was the posterior pharyngeal wall, and the anterior boundary was created by the soft palate and base of the tongue. Four craniometric points were used in the sagittal reconstruction to verify the extent of mandibular and maxillary movement: (1) PNS, (2) point A, (3) point B, and (4) menton.

Results: There is not significant differences was found between pre and post operative PAS ($p=0.083$) and MAS ($p=0.287$). Horizontal movement of point A and PNS were significantly associated with increase in upper oropharynx airway volume, lower oropharynx airway volume and total oropharynx airway volume ($p>0.05$). Furthermore, horizontal movements of PNS were significantly associated with increase in both total PAS and MAS ($p>0.05$).

Conclusions: The results of the present study indicated that PAS and MAS are not negatively affected by bimaxillary surgery in Class III patients. Horizontal movement of maxillary bone has the strongest influence on PAS whereas movement of mandible has no effect.

Keywords: posterior airway space, orthognathic surgery, dentofacial deformity

Introduction

Decrease in the nasopharynx volume and oropharynx volume observed in previous researched after bimaxillary surgery for the correction of the skeletal class III malocclusion, especially when patients are predisposed to the development of breathing problems[1]. On the other hand, some studies concluded that bimaxillary orthognathic surgery for the correction of Class III malocclusion resulted in decreased total PAS[2]. Therefore, changes in the PAS resulting from different types of orthognathic surgery still remain controversial. PAS narrowing has been implicated in the development of obstructive sleep apnea (OSA)[3].

OSA is considered to be a risk factor for systemic and pulmonary hypertension, cor pulmonale, polycythemia, and cardiac arrhythmias, and might increase morbidity and mortality. Thus, the movements generated by the surgeon can greatly influence people's health and quality of life[4]. Surgeons should assess preoperative and postoperative changes in the airway so as to prevent excessive airway stenosis and avoid the development of iatrogenic OSA. Although advancements in the maxillomandibular complex seem to have measurable effects on the dimensions of the posterior pharyngeal airway space, and some studies already state the extent to which 2D advancement dimensions affect cephalometric measurements [5] and soft tissue projections[6], the prediction of 3D changes to the posterior airway space after a planned advancement or setback of the mandible has not been established mathematically. That kind of prediction about correlation of jaw movements and PAS change may help surgeons to estimate if their surgery planning is going to affect patient's PAS and related life quality badly before the bimaxillary surgery.

This two-dimensional exam has several limitations to study three-dimensional structures, such as the airways. That is why, nowadays, computed tomography is the exam of choice. It allows to evaluate the shape and contour of the upper airways in the three dimensions (height, depth and width), as well as to calculate the volume and area in each airway regions[7]

The null hypothesis of the study are these; (1) there is a significant difference between preoperative and postoperative PAS measurements for skeletally class III orthognatic surgery patients, (2) there is a negative correlation between the amount of setback and the PAS measurements.

The aims of the study are the evaluation of three-dimensional changes of the pharyngeal airways and hyoid bone position after bimaxillary correction of Class III patients; evaluations of correlations between PAS and jaw movements after bimaxillary surgeries with segmentation.

Methods and Materials

Patient selection:

This research is going to involve a retrospective sample composed of at least 37 patients with occlusal pattern and facial profile of class III skeletal occlusions. The patients between age of 18-35 is going to be included in the study. To standardize the sample selection, the study included adult patients of both sexes, and patients with classes III skeletal malocclusions with bimaxillary surgical correction or mandible setback orthognathic surgery. The following characteristics was adopted as exclusion criteria: dental loss or agenesis of a large number of teeth (six or more); severe facial asymmetry; presence of syndromes; respiratory diseases; obstructive sleep apnea; and disorder or degeneration of the temporomandibular joint.

Data collection method:

All of the CBCT images were acquired with the CBCT machine in the UNESP faculty of dentistry with the same exposure parameters. An experienced radiology technician performed the acquisition process according to the manufacturer's recommended protocol with the minimum exposure required for adequate image quality. The scan was maintained in maximum intercuspidation and tongue and lips were at rest and the patient was breathing lightly and avoiding swallowing. CBCT data was converted to Digital Imaging and Communications in Medicine (DICOM) format, and 2D and 3D measurements of the airway area and volume were conducted with the Nemoceph 3D software. Prior to analysis, all scans were reoriented in the coronal plane, the right and left inferior orbital borders were levelled. Sagittaly, the best fit of the zygomatic arch was levelled. Axially, the lateral walls of the orbits were aligned.

Measurements:

1. Maxillary and mandibular movement:[8]

Four craniometric points were used in the sagittal reconstruction to verify the extent of mandibular and maxillary movement: (1) Point PNS (posterior nasal spine), (2) Point A (maxilla), (3) Point B (mandible), and (4) Point Me (menton). With the reference lines defined, four horizontal and four vertical measurements were performed. Vertical measurements were conducted from the HRL to points PNS, A, B, and Me and are going to be identified as V-PNS, V-A, Ve-B, and Ve-Me. Horizontal measurements to these same points were conducted from the VRL and identified as H-PNS, H-A, He-B, and He-Me.

2. Airway Volume:[9]

The airway volume was bounded superiorly by the line extending from posterior nasal spine (PNS) to the pterogomaxillary junction and inferiorly by a parallel line from the anterior-inferior border of C3 to the hyoid bone. The posterior limit was the posterior pharyngeal wall, and the anterior boundary was created by the soft palate and base of the tongue. The nasopharyx was defined as the airway space between a plane parallel to FH passing through PNS and a plane passing through the right and left PT points, and the PNS. The oropharynx was defined as the airway space between a plane parallel to FH passing through PNS and a plane between C3 and the hyoid bone. Oropharynx was divided into the retroglossal and retropalatal airway spaces by a plane parallel to FH passing through the top of the epiglottis. The total PAS was defined as the sum of the nasopharynx and the oropharynx minimum axial airway was determined for entire airway as well as the retropalatal (anterior-inferior border of C1), retroglossal (anterior- inferior of C2) and retropharyngeal (anterior-inferior C3) regions.

Statistical Analysis:

The paired t-test was performed for comparisons of the difference between preoperative and postoperative variables. A p-value less than 0.05 was considered significant. Pearson's correlation was used to determine if a relationship existed among the pharyngeal and the hyoid bone, soft palate, and head posture observed between the time points. Statistical tests were performed using IBM SPSS 19.0 (IBM Corp., Armonk, NY, USA). Dahlberg coefficients was determined to verify measurement reliability for volume, area and distance measurements of 10 randomly selected datasets. To analyse the correlation between PAS changes and the amount and direction of jaw displacement, the Spearman bivariate correlation analysis was applied. Priori power analyse was performed with the result of the previous study[10] and according to the result, pre and post-operative records of 37 patient provided at least %90 power for the present study.

Results

The preoperative total airway of the patients was 23.01±8.46 and postoperative total airway was 25.07±9.25. There was no statistically difference between pre-operative and post-operative total airway (p=0.853) (Figure 1). The preoperative minimum axial section of the patients was 176.20±108.16 and postoperative minimum axial section was 188.42±97.96. There was no statistically difference between pre-operative and post-operative total airway (p=0.531) (Figure 2). The preoperative nasopharyngeal airway of the patients was 5.08±1.89 and postoperative nasopharyngeal airway was 5.36±2.01 There was no statistically difference between pre-

operative and post-operative nasopharyngeal airway (p=0.554) (Figure 3). The preoperative oropharyngeal airway of the patients was 17.06±7.35 and postoperative oropharyngeal airway was 18.61±8.16. There was no statistically difference between pre-operative and post-operative oropharyngeal airway (p=0.849) (Figure 4). The linear regression model showed a statistically significant influence of horizontal movement of point A on the difference in total airway (p=0.032, r=0.374) (Figure 5) and oropharyngeal airway (p=0.020, r=0.403) (Figure 6) dimension pre- and postoperatively. The linear regression model showed a statistically significant influence of horizontal movement of PNS on the difference in oropharyngeal airway (p=0.029, r=0.380) (Figure 7) dimension pre- and postoperatively. The linear regression model showed a statistically significant influence of vertical movement of point B on the difference in total airway (p=0.030, r= -0.379) (Figure 8) and oropharyngeal airway (p=0.043, r= -0.355) (Figure 9) dimension pre- and postoperatively.

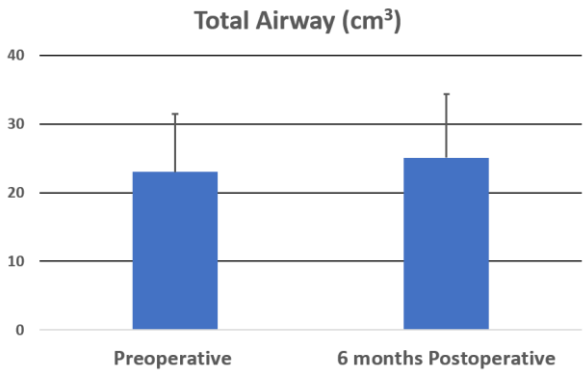

Figure 1: *Preoperative and postoperative total airway results*

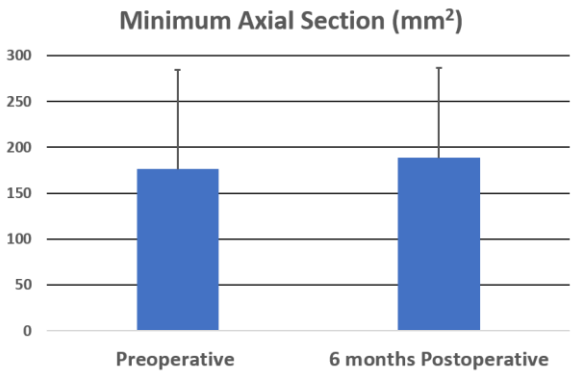

Figure 2: *Preoperative and postoperative min. axial section results*

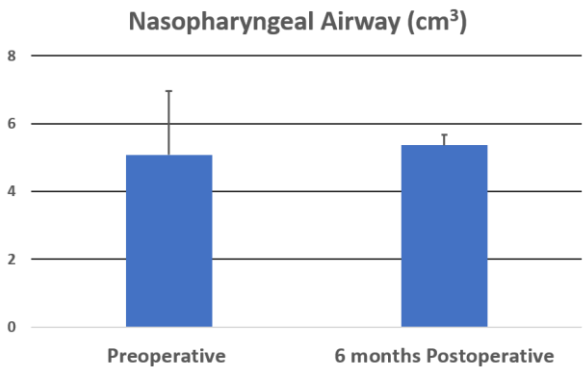

Figure 3: *Preoperative and postoperative nasopharyngeal airway results*

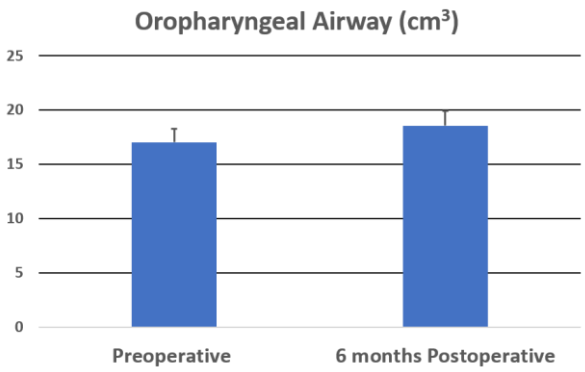

Figure 4: *Preoperative and postoperative nasopharyngeal airway results*

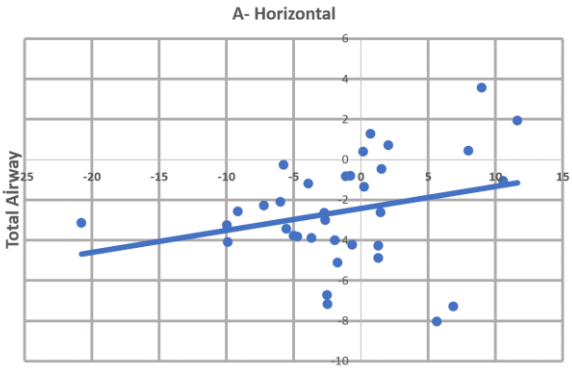

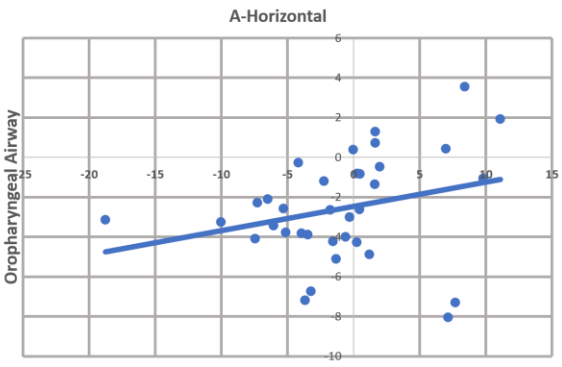

Figure 5: *Correlation between total airway and horizontal movement of point A*

Figure 6: *Correlation between oropharyngeal airway and horizontal movement of point A*

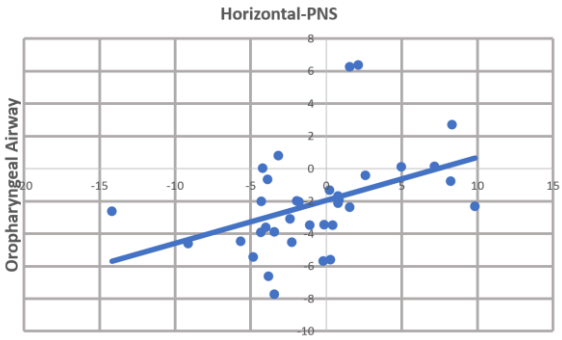

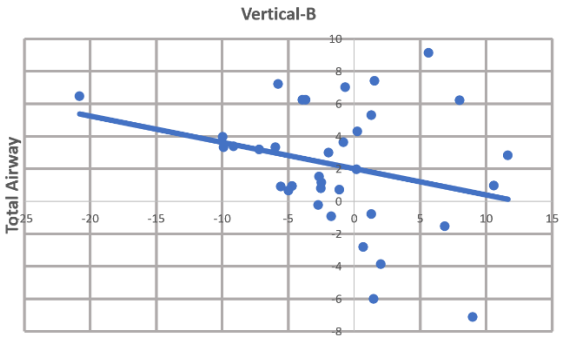

Figure 7: *Correlation between oropharyngeal airway and horizontal movement of PNS*

Figure 8: *Correlation between oropharyngeal airway and vertical movement of point B*

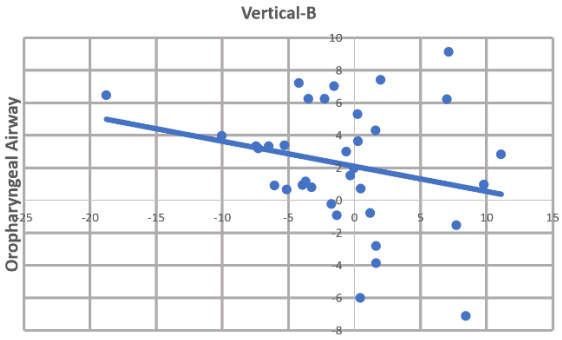

Figure 9: *Correlation between oropharyngeal airway and vertical movement of point B*

Discussion

In some studies, with maxillary advancement and mandibular setback surgery, decrease in the airways between preoperative tomography (T0) and T1 in all regions was noted[11,12]. In the study by Shin et al.[12] at one year postoperative there was a slight increase in all the airway volume

regions, such as An et al.[11] with the exception of the hypopharynx region which slightly decreased. In addition, according to Jakobsone et al.[13], maxillary advancement of more than 2 mm would increase the dimensions of the nasopharynx area and can compensate for a decrease in the airway space caused by the mandibular setback. Only the studies of Park et al.[14] and Shin et al.[12] had a maxillary advancement of more than 2 mm. Between the preoperative and the immediate postoperative tomography, patients of Park et al.[14] had the cross-sectional area on CV1 (corresponding to the end of the nasopharynx region) and the nasopharynx volume increased but was not statistically significant. While the volume of the nasopharynx, in the study of Shin et al.[12], decreased, but this decrease was not statistically significant and then one year after the surgery the volume of this region had a significant increase. However, other studies[11,14] that did not have a maxillary advancement more than 2 mm, all had a significant decrease in the nasopharyngeal region. In the present study, results indicated that total airway, nasopharyngeal airway, oropharyngeal airway and minimum axial section increased but not statistically significant, after maxillary advancement and mandibular setback surgeries. It can be explained with that the increase in total airway may due to advancement of velopharyngeal tissues with Le Fort I osteotomy which compensates the potential effects of the mandibular setback.

The correlation between jaw movements and morphometric airway measurements were evaluated by Tan et al[9]. The superior movement of the hyoid bone was found to correlate significantly with a decreased oropharyngeal length (r=0.445; P=0.003). The superior movement of the PNS has correlated with a decreased nasopharyngeal length (r=0.718; P<0.001), area (r=0.631; P<0.001) and volume (r=0.502; P<0.001), while an anterior movement of the PNS has been associated with a decreased nasopharyngeal length (r=0.295; P=0.049) and an increased minimum cross-sectional area at retro-palatal sub-region (r=0.352; P=0.020). On the other hand, a superior movement of the B-point has been detected to correlate with a decrease in nasopharyngeal volume (r=0.349; P=0.016). Furthermore, an anticlockwise rotation of the palatal plane has been found to be associated with an min increased minimum cross-sectional area antero-posterior length at the level of the oropharynx (r=0.33; P=0.026). The results of the present study indicated that anterior movement of point A correlated with the increase in total airway and oropharyngeal airway which is also valid for PNS and oropharyngeal airway. These results support the idea that maxillary anterior movement tended to elevate the soft palate and dilate the velopharynx which expected to increase airway volumes. Another correlation was observed between vertical movement of point B with total airway and

oropharyngeal airway. The mandible, base of the tongue, hyoid bone, and the pharyngeal walls are intimately related by muscles and ligaments and counter-clockwise rotations may provide more space for tongue and move pharynx related muscles superio-anteriorly.

All these correlations are moderate to weak so the results should be evaluated with caution. It is difficult to evaluate isolated jaw movements on the airway changes however, complex movements of the jaws are done during bimaxillary surgeries which may have negative and positive effects on the airway at the sametime.

Conclusion

In conclusion, correction of class III malocclusion did not significantly change any airway parameters pre- and postoperatively. Advancement of the maxilla seems to increase the airway volume in the oropharyngeal region by pulling the related musculature forward. Counter clockwise rotation of the mandible potentially maximizes the forward movement of the hyoid bone, the base of the tongue, and other associated soft tissues. Anterior movement of the hyoid is correlated with the changes in the airway dimensions rather than anterior movement of the mandible.

Acknowledgements

None

References:

1. Uesugi T, Kobayashi T, Hasebe D, Tanaka R, Ike M, Saito C: Effects of orthognathic surgery on pharyngeal airway and respiratory function during sleep in patients with mandibular prognathism. Int J Oral Maxillofac Surg 43: 1082, 2014.
2. Burkhard JPM, Dietrich AD, Jacobsen C, Roos M, Lübbers HT, Obwegeser JA: Cephalometric and three-dimensional assessment of the posterior airway space and imaging software reliability analysis before and after orthognathic surgery. J Cranio-Maxillofacial Surg 42: 1428, 2014.
3. Riley RW, Powell NB, Guilleminault C, Ware W: Obstructive sleep apnea syndrome following surgery for mandibular prognathism. J Oral Maxillofac Surg 45: 450, 1987.
4. Faber J, Faber C, Faber AP: Obstructive sleep apnea in adults. Dental Press J Orthod 24: 99, 2019.
5. Proffit WR, Fields HW, Sarver DM: Contemporary orthodontics. St. Louis, Mo. : Mosby Elsevier, 2007.
6. Suh HY, Lee HJ, Lee YS, Eo SH, Donatelli RE, Lee SJ: Predicting soft tissue changes after orthognathic surgery: The sparse partial least squares method. Angle Orthod 89: 910, 2019.
7. Daluz ADJ, Silva TVS da, Tôrres BO, Costa DFN, Santos LA de M: Long-term airway evolution after orthognathic surgery: Systematic Review. J Stomatol Oral Maxillofac Surg, 2021.
8. Yamashita AL, Iwaki Filho L, Leite PCC, Navarro R de L, Ramos AL, Previdelli ITS,

Ribeiro MHDM, Iwaki LCV: Three-dimensional analysis of the pharyngeal airway space and hyoid bone position after orthognathic surgery. J Cranio-Maxillofacial Surg 45: 1408, 2017.
9. Tan SK, Tang ATH, Leung WK, Zwahlen RA: Three-dimensional pharyngeal airway changes after 2-jaw orthognathic surgery with segmentation in dento-skeletal Class III patients. J Craniofac Surg 30: 1533, 2019.
10. Tepecik T, Ertaş Ü, Akgün M: Effects of bimaxillary orthognathic surgery on pharyngeal airway and respiratory function at sleep in patients with class III skeletal relationship. J Cranio-Maxillofacial Surg 46: 645, 2018.
11. An JH, Park SB, Choi YK, Lee SH, Kim KB, Kim Y Il: Cone-Beam Computed Tomography Evaluation of Pharyngeal Airway Space Changes After Bimaxillary Orthognathic Surgery in Patients With Class III Skeletal Deformities: A 6-Year Follow-Up Study. J Oral Maxillofac Surg 77: 2534, 2019.
12. Shin JH, Kim MA, Park IY, Park YH: A 2-year follow-up of changes after bimaxillary surgery in patients with mandibular prognathism: 3-dimensional analysis of pharyngeal airway volume and hyoid bone position. J Oral Maxillofac Surg 73: 340.e1, 2015.
13. Jakobsone G, Stenvik A, Espeland L: The effect of maxillary advancement and impaction on the upper airway after bimaxillary surgery to correct Class III malocclusion. Am J Orthod Dentofac Orthop 139: e369, 2011.
14. Park SB, Kim YI, Son WS, Hwang DS, Cho BH: Cone-beam computed tomography evaluation of short- and long-term airway change and stability after orthognathic surgery in patients with Class III skeletal deformities: Bimaxillary surgery and mandibular setback surgery. Int J Oral Maxillofac Surg 41: 87, 2012.
15. Auvenshine RC, Pettit NJ: The hyoid bone: an overview. Cranio - J Craniomandib Pract 38: 6, 2020.