# CT ANALYSIS OF HALLUX VALGUS BEFORE AND AFTER LAPIDUS PROCEDURE: A LAKETOWN ORTHOPAEDIC HOSPITAL EXPERIENCE

**Sotero Ramos, III, MD, Prof Satoru Ozeki**

## Introduction

Hallux valgus is a complex deformity involving the first ray of the foot and is frequently accompanied by deformity and symptoms of the lesser toes.[1] It involves not only the 2-dimensional deformity of medial deviation of the 1st metatarsal and lateral deviation of the proximal phalanx but also involves an axial rotation component. If the valgus angle of the 1st metatarsophalangeal joint (MTPJ) exceeds 30 to 35 degrees, pronation of the great toe results.[1] Metatarsus primus varus is the main pathology in hallux valgus. As the 1st metatarsal goes into medial deviation, most soft tissues would lie lateral to it and thus further contributes to the deforming forces, e.g. adductor hallucis and abductor hallucis. One predisposing factor to hallux valgus is the hypermobility of the first ray, which occurs when the subtalar joint remains pronated during the midstance and propulsion during gait.[2] Hypermobility may have an effect in the stability of the arch of the foot, which in turn, may cause symptoms such as transfer metatarsalgia, callosities and stress fracture of a lesser metatarsal. In 1934, Paul Lapidus developed a technique that addresses the hypermobility of the first ray and it involved the first metatarso-cuneiform fusion that can correct hallux valgus deformity in 3 planes.[3] A study done by Dayton, et al., involved correction of the three planes of deformity in hallux valgus and gave emphasis on supinating the first ray prior to doing the tarsometatarsal joint (TMTJ) fusion to address the pronation component.[4] There are various factors that may affect the functional outcome of the patients after hallux valgus correction such as the distance of the 1st metatarsal to the second metatarsal, 1st metatarsal length in relation to the second metatarsal, sesamoid reduction, 1st metatarsal pronation, and 1st metatarsal inclination angle. Most of these have a corresponding measurement either by xray or by CT scan. There was a study done by Tanaka, et.al, where they analyzed hallux valgus using an xray of the foot and made the second metatarsal ray as the reference point, however,

negating the rotational and sesamoid reduction components of the pathology. Aside from measuring the usual parameters such as hallux valgus angle (HVA), intermetatarsal angle (IMA), Meary's angle, 1st and 2nd metatarsal length, the goal of this study is to correlate alternative ways of analyzing the hallux valgus deformity to the standard measurements using a weight bearing 3D CT scan. The study also aims to open new possibilities for future management as well as understanding further the pathology of hallux valgus.

**Objectives**

1. To determine the measurements of the pronation angle, degree of sesamoid displacement, 1st metatarsal length, 2nd metatarsal length, 1st-2nd metatarsal distance, 1st MT-calcaneus, 2nd MT-calcaneus distance, 1st metatarsal inclination angle, and 3rd metatarsal to lateral sesamoid distance preoperatively and postoperatively using Synapse Vincent software.
2. To correlate the following findings: IMA with the 1st-2nd MT distance, 1st MT length with the 1st MT-calcaneus distance, 2nd MT length with the 2nd MT-calcaneus distance and Meary's angle with the 1st MT inclination angle, pronation angle with IMA, HVA, 1st-2nd MT distance and 1st MT-calcaneus distance.

**Methodology**

This was a retrospective study done in Laketown Orthopaedic Hospital in Koshigaya, Japan. Only those with moderate and severe hallux valgus were included in the study. In order to avoid interobserver error, all measurements were done by a single observer and were recorded. Weight bearing foot CT scans of subjects without hallux valgus were obtained and were assigned to the control group. Preoperative and postoperative weight bearing foot CT scans were retrieved from the database of Laketown Orthopaedic Hospital. Using Synapse Vincent software, the measurements of the following were obtained: pronation angle, degree of sesamoid displacement, 1st metatarsal length, 2nd metatarsal length, 1st-2nd metatarsal distance, 1st MT-calcaneus, 2nd

MT-calcaneus distance, 1st metatarsal inclination angle, and 3rd metatarsal to lateral sesamoid distance.

To determine the severity of the condition, a preoperative weight bearing radiograph data of the foot was obtained and measurement of the hallux valgus angle (HVA) and intermetatarsal angle (IMA) were done. Using lateral radiographs, Meary's angle was measured by subtending between the lines to be drawn though the long axes of the talus and first metatarsal.[5]

First ray pronation was measured using the alpha angle as described by Kim, et al. Using the coronal view of the forefoot, two parallel lines were drawn along the 1st MT head: an inferior line joining the far points of the medial and lateral sesamoid sulcus; and a superior line between the far points of the MT head.[7] An alpha angle was measured between a line connecting the midpoints of the first two lines described and a line drawn perpendicular to the floor (Fig 1). Pronation was labeled as a positive measurement and supination was labeled as a negative measurement. The degree of sesamoid reduction was graded using the technique described by Smith, et al (Fig 2). The grading was based on the relationship of the tibial sesamoid to the sesamoid crista. Grade 0 indicates that tibial sesamoid is medial to the crista; grade 1 indicates that half of the tibial sesamoid crosses the crista; grade 2 indicates that more than half of the tibial sesamoid crosses the crista; and grade 3 indicates that the entire tibial sesamoid lies lateral to the crista.[10]

Using the sagittal view of the 1st and 2nd MT, the length was measured by drawing a line across the axis of each metatarsal. The limit of the measurement is from the tip of the head to the point of intersection between the tip dorsal and plantar base of the metatarsals (Fig 3, Fig 4). The difference of the lengths of the 1st and 2nd MT were obtained and recorded. First MT length was also measured as a percentage of the length of the 2nd MT.

First-2nd MT distance was measured using the axial and coronal views. Center of the 1st and 2nd MT heads were marked in both the coronal view and axial views to ensure that the point is really at the center of the head. Line was drawn connecting the 2 points to obtain the measurement for the 1st-2nd metatarsal distance (Fig 5).

First and 2nd MT-calcaneus distance was measured using axial view of the weight bearing CT scan. A fixed point was determined at the center of the widest portion of the

calcaneal tuberosity. A Line was drawn from the calcaneal origin connecting it to a point at the center of the 1st metatarsal head. Another line was drawn in the same manner for the 2nd MT (Fig 6). The difference between the 2 measurements were obtained and recorded.

First MT inclination angle was measured in sagittal cut by drawing a line from the plantar aspect of the calcaneus to the 1st MT head and another line along the axis of the 1st MT. This is based on the measurement done by Pauli, et al in their paper about the proximal metatarsal crescentic osteotomy.[11]

A novel technique was done to measure the 3rd MT-lateral sesamoid distance. This was done by drawing a line connecting the center of the 3rd MT head to the lateral cortex of the lateral sesamoid on coronal view (Fig 8). This was under the premise that the adductor hallucis acts as a deforming force for the hallux valgus that might affect sesamoid reduction and that it originates from the base of the 3rd MT inserting to the lateral-plantar aspect base of the great toe proximal phalanx becoming a part of the plantar plate-sesamoid complex.

**Statistics**

A paired T-test was used to compare the weight bearing CT scan measurements of the control group to the preoperative; the control group to the postoperative study group; and preoperative study group to the postoperative study group. Pearson correlation was used for the following correlations: IMA with the 1st-2nd MT distance, 1st MT length with the 1st MT-calcaneus distance, 2nd MT length with the 2nd MT-calcaneus distance and Meary's angle with the 1st MT inclination angle. Pearson correlation was likewise done for the following measurements: pronation angle and IMA, pronation angle and HVA, pronation angle and 1st-2nd MT distance and pronation angle and 1st MT-calcaneus distance.

**Results**

Upon reviewing the database from Laketown Orthopaedic Hospital, we had a total of 36 patients. We have found 18 patients diagnosed with hallux valgus that have a complete preoperative and postoperative weight bearing foot CT scan and were assigned

to the study group. Twelve of these patients were diagnosed with moderate hallux valgus (HVA of 20-40 deg)[1] and 6 were diagnosed with severe hallux valgus (HVA >40).[1] All of these patients underwent Lapidus procedure. The study group was further divided into the preoperative group and postoperative group. The follow up period ranged from 4 months-15 years with a mean of 5 years. There were no cases of recurrence among the study group, however there was one case of hallux varus. We have 18 patients that have a normal weight bearing foot CT scan and were assigned to the control group. There were 5 males and 13 females in the control group and 1 male and 17 females in the study group. Majority of the control group has a left foot involvement and majority of the study group has a right foot involvement. Age range was 18-78 years from the control group and 40-87 years from the study group (Table 1).

The control group and the preoperative and postoperative groups were analyzed separately. Measurements from the control, preoperative and postoperative groups are tabulated in table 2, 3 and 4 respectively. Both preoperative and postoperative groups were compared to the control group. There was a significant difference between the control and preoperative groups (table 5) in terms of the HVA with a mean difference of 25.3 deg (sig= 0.00001; $p < 0.05$), IMA with a mean difference of 9.6 deg (sig= 0.00001; $p < 0.05$), Meary's angle with a mean difference of 8.1 deg (sig= 0.001; $p < 0.05$), pronation angle with a mean difference of 11.3 deg (sig= 0.00003; $p < 0.05$), sesamoid reduction grade (sig= 0.00001; $p < 0.05$), 1$^{st}$-2$^{nd}$ MT distance with a mean difference of 0.7 cm (sig= 0.00001; $p < 0.05$), 1$^{st}$ MT length with a mean difference of 0.3 cm (sig= 0.032; $p < 0.05$), 2$^{nd}$ MT length with a mean difference of 0.4 cm (sig= 0.022; $p < 0.05$), 2$^{nd}$ MT-calcaneus distance with a mean difference of 0.7 cm (sig= 0.049; $p < 0.05$), and 1$^{st}$ MT inclination angle with a mean difference of 3.7 deg (sig= 0.00026; $p < 0.05$). Of particular importance is that here is no significant difference between the 3$^{rd}$ MT-lateral sesamoid distance with a mean difference of 0.1 cm (sig= 0.055; $p < 0.05$). There was a significant difference between the control and postoperative groups (table 6) in terms of pronation angle with a mean difference of 5.6 degrees (sig= 0.02; $p < 0.05$), 1$^{st}$ MT length with a mean difference of 0.7 cm (sig= 0.00005; $p < 0.05$), 2$^{nd}$ MT length with a mean difference of 0.5 cm (sig= 0.0014; $p < 0.05$), 1$^{st}$ MT-calcaneus distance with a mean difference of 0.9 cm (sig= 0.015; $p < 0.05$), and 2$^{nd}$ MT-calcaneus distance with a mean

difference of 0.6 cm (sig= 0.075; $p < 0.05$). Of note is that there was no significant difference in terms of the 3rd MT head-lateral sesamoid distance with a mean difference of 2.05 (sig= 0.31; $p < 0.05$) and sesamoid reduction grade (sig= 0.054; $p < 0.05$).

A paired t-test was used to compare the preoperative and postoperative groups (table 7). Of particular note is the 3rd MT-lateral sesamoid distance which was not statistically significant between the groups (sig= 0.14; $p < 0.05$). Another is the significant difference between the 1st metatarsal length (sig= 0.00001; $p < 0.05$) as the lapidus procedure entailed a thin wedge resection of the base of the 1st MT to correct the deformity. Likewise the 2nd MT length having a significant difference (sig= 0.42; $p < 0.05$) as there were patients that required shortening of the 2nd MT to correct the corresponding hammer toe deformity.

A pearson correlation was made for the IMA and 1st-2nd MT distance, 1st MT length and 1st MT-calcaneus distance, 2nd MT length and 2nd MT-calcaneus distance, and Meary's angle and 1st MT inclination angle. For data consistency, correlation for the control, preoperative and postoperative groups were done (Fig 9 – Fig 20). There was a moderate-strong correlation of IMA and 1st-2nd MT distance, 1st MT length and 1st MT-calcaneus distance, and 2nd MT length and 2nd MT-calcaneus distance in all groups. However, there is a weak correlation between the Meary's angle and 1st MT inclination angle in all groups (table 8, 9, 10).

A Pearson correlation was also made to correlate the pronation angle of the control group to the HVA (R= 0.3) , IMA, (R= -0.0008), 1st-2nd MT distance (R= 0.22) and 1st MT-calcaneus distance (R= 0.17) which showed a poor correlation of the pronation angle to the said parameters. To have data consistency, pronation angle of the preoperative and postopverative groups was also correlated to the said parameters and also had weak correlation (table 11, 12, 13).

**Discussion**

Hallux valgus is a complex condition of the 1st metatarsal that involves 3-dimensional deformity of the 1st metatarsal. However, the condition does not only involve the forefoot, but it might also involve the longitudinal arch of the foot. The pathology behind it involves the ligamentous laxity as well as instability of the 1st TMT joint, hence,

the development of the Lapidus procedure.[3] In order to achieve good outcomes, correction of hallux valgus also entailed soft tissue releases, in particular, the lateral capsule as well as the adductor hallucis tendon. This study aimed to analyze the parameters involved in this condition before and after the Lapidus procedure. Aside from the well known measuring parameters that are being used, other parameters such as the pronation angle, 1st-2nd MT distance, 1st MT inclination angle, 1st MT-calcaneus distance, 2nd MT-calcaneus distance and 3rd MT-lateral sesamoid distance.

It is established in literature that as the severity of the hallux valgus increases, so is the pronation of the proximal phalanx of the great toe.[1] There were studies stating that the 1st MT likewise pronates as the severity increases, however they concluded that the pronation angle of the 1st MT is an independent factor that may coexist with other parameters of the hallux valgus and that abnormal pronation of the 1st MT also existed in normal feet.[5] A study done by Campbel, et.al, analyzing the 3-dimensional measures of the pronation of the 1st MT in relation to the 2nd MT also concluded that pronation is greater in hallux valgus patients but is poorly correlated with the IMA.[11] This study confirmed the finding of Mahmoud, K., et.al as pronation angle measured in this study was weakly correlated with the IMA, HVA, 1st-2nd MT distance, and 1st MT-calcaneus distance in both the control and study groups (tables 11, 12, 13). However, in this study, it was found that the pronation angle of the 1st MT is greater by 11.3 deg in average in patients who have hallux valgus compared to the controls. In this study, the correction of the deformity included supinating the 1st MT in order to attain sesamoid reduction. The mean correction was 5.6 deg. Sesamoid reduction was also taken into consideration as we think, that this is an important aspect to correct in hallux valgus. In this study, we noted that patients with hallux valgus had an average of grade 3 sesamoid displacement compared to the control, which had grade 0 (Fig 2). However, we also took into account the deforming force of the sesamoid subluxation, which is the adductor hallucis. This muscle originates at the base of the 3rd MT and has an oblique and transverse heads. The main reason of its subluxation was because of the translation of the 1st MT, and not because of the soft tissue contracture itself. We expressed this measurement as the 3rd MT-lateral sesamoid distance. The results show that there is no significant difference of this parameter in both the control and study groups. This finding might obviate the soft

tissue releases when doing the Lapidus procedure as it entails a bit of shortening of the 1st MT which will make the soft tissues lax, and that the soft tissue length remains constant, however, this needs further study.

IMA is a common parameter measured in the severity of hallux valgus however, in our observation, it is also important to note the distance of the 1st and 2nd MT heads. To our knowledge, no study was made yet to determine the 1st-2nd MT distance. In this study, the control group had a mean 1st-2nd MT distance of 2.3 cm (1.9-2.9 cm). There is a significant difference of the 1st-2nd MT distance between the control group and the preoperative group with a mean difference of 0.7 cm (sig= 0.00001; $p < 0.05$). A significant difference was found after correction of the hallux valgus with a mean of 0.6 cm correction (sig= 0.00003; $p < 0.05$) between the preoperative and postoperative groups. And no significant difference was found upon comparing the postoperative group with the control with a mean difference of 0.07 cm (sig= 0.41; $p < 0.05$). The 1st-2nd MT distance is highly correlated with IMA meaning we can use this as an alternative way of measuring the degree of correction. However, it is still difficult to establish standard way with regards to the amount of correction of the 1st-2nd MT distance as basing the correction solely on this parameter might lead to undercorrection or overcorrection of the pathology. There is one case in the study that had hallux varus morbidity probably due to overcorrection. Hallux varus usually occurs if the lateral sesamoid was removed or if there is over resection of the medial eminence, which were both not done for this patient.[1] The preoperative 1st-2nd MT distance was 3.5 cm and the postoperative 1st-2nd MT distance was 1.9 cm with a correction difference of 1.6 cm.

The length of the 1st and 2nd metatarsals is an important parameter to take into consideration when correcting hallux valgus. Too much shortening of the 1st MT might lead to further complications. However, there is still no fixed amount of shortening that might lead to complications. The exact value of the length of the 1st and 2nd MT varies on each individual, so in this study, we expressed the difference in length of the 1st MT in relation to the 2nd MT as percentage. Comparing the control group and the preoperative group (Table 14), the means were 83.7 cm and 84.1 cm respectively (sig= 0.77; $p < 0.05$). There is a significant difference when the postoperative group (Table 14 and 15) was compared to the preoperative group (sig= 0.0006; $p < 0.05$) and the control group (sig=

0.033; $p < 0.05$). The mean 1st MT length percentage of the postoperative group was 80.0%, which was lower than the mean percentages of the preoperative group (83.7%) and control group (84.1%). In this study, the range of the postoperative 1st MT length percentage was 67-92%. Further study is needed to establish the range of amount of shortening of the 1st MT in relation to the 2nd MT in order to have a good outcome. However, this finding might be able to contribute to the planning of correction as to performing an opening wedge, or a closing wedge to maintain the length of the 1st MT to a certain percentage. In order to assess hallux valgus in reference to the foot being a tripod, we measured the 1st MT-calcaneus distance and 2nd MT-calcaneus distance. Both measurements were correlated to the length of the 1st and 2nd MT and have moderate-strong correlation in all groups. It can also be used as an alternative in assessing the length of both the 1st and 2nd MT especially in those patients whose joint line is unidentifiable because of arthritis or auto-fusion.

Meary's angle is an important parameter to take into account as hallux valgus, being a 3-dimensional deformity, can also affect the longitudinal arch of the foot. The study done by Pauli, et.al entailed measuring the calcaneal pitch, 1st MT inclination angle and Meary's angle but no correlation was done and the procedure involved was the proximal MT osteotomy and concluded to have good outcomes with the procedure.[11] In this study, Meary's angle and 1st MT inclination angle was measured. We assumed that if the Meary's angle increases, the 1st MT inclination decreases. But upon correlating the two parameters, the results show a weak correlation between the Meary's angle and 1st MT inclination angle in both control and study groups (table 8, 9, 10), indicating that these two parameters contribute to the arch of the foot but cannot be used interchangeably.

**Conclusion**

In conclusion, hallux valgus is a very complex condition that required a complex procedure for correction. Important points that can be concluded in this study based on the results are the sesamoids remain in a constant position and, we think, is the most important landmark for the correction of the hallux valgus, i.e. sesamoids should be at the center of the 1st MT head; pronation component is independent, however consideration

must me given for its correction; 1st-2nd MT distance is an alternative to IMA measurement and could be a basis of correction however, a specific range of measurement is yet to be established; based on the 3rd MT-lateral sesamoid distance, performing the adductor tenotomy is not necessary instead, a capsular release might be able to help in correcting the hallux valgus; length of the 1st MT is better to be measured in relation to the 2nd MT length and expressed in percentage as the lengths vary in each individual, and that further study to determine the amount of shortening that is required to have a good outcome; although Meary's angle and 1st MT plantar flexion are important in assessment of the arch of the foot, the two parameters cannot be used interchangeably due to a weak correlation. Lastly, correction of hallux valgus depends on multiple factors and one should never depend solely on one parameter, as it is a complex deformity. In this study, the results showed no recurrence of the deformity when it was corrected within the above parameters.

The weakness of this study is the low number of study samples and the lack of functional outcome measures. The aim of this study however, is the CT analysis of hallux valgus. As a future direction of this study and to contribute further in its management, functional outcomes could be correlated in order to establish parameters in which the hallux valgus must be corrected and standardized.

**Tables**

Table 1: Demographics

| | Control | Study |
|---|---|---|
| Age | 18-71 | 40-87 |
| Gender | | |
| • Male | 5 | 1 |
| • Female | 13 | 17 |
| Diagnosis | | |
| • Moderate Hallux Valgus | | 12 |
| • Severe Hallux Valgus | | 6 |

| | | |
|---|---|---|
| Laterality | | |
| • Left | 6 | 11 |
| • Right | 12 | 7 |
| Follow up Period | | 4months - 15 years |
| Morbidity | | |
| • Hallux varus | | 1 |

Table 2: Control group measurements

| | Mean | Range |
|---|---|---|
| HVA | 13.1 deg | 4.5-19.3 deg |
| IMA | 8.6 deg | 2.7-18.2 deg |
| Meary's Angle | 1.4 deg | 0-2.6 deg |
| Pronation Angle | 2.7 deg | -9.5-15.8 deg |
| Sesamoid reduction Grade | 0 | 0 |
| 1-2 MT distance | 2.3 cm | 1.9-2.9 cm |
| 1st MT length | 5.9 cm | 5.3-6.5 cm |
| 2nd MT length | 7.1 cm | 6.5-8.1 cm |
| 1st MT-Calcaneus | 14.7 cm | 13.4-17.2 cm |
| 2nd MT-Calcaneus | 14.8 cm | 13.2-16.8 cm |
| 1st MT inclincation angle | 24.7 cm | 21.1-30.3 cm |
| 3rd MT-lateral sesamoid distance | 2.4 cm | 2-2.6 cm |

Table 3: Preoperative group measurements

| | Mean | Range |
|---|---|---|
| HVA | 38.5 deg | 25.1-64.2 deg |
| IMA | 18.2 deg | 13.3-25.1 deg |

| | | |
|---|---|---|
| Meary's Angle | 9.5 deg | 0.4-42.1 deg |
| Pronation Angle | 13.9 deg | -4.8-27.3 deg |
| Sesamoid reduction Grade | 0 | 0 |
| 1-2 MT distance | 3.0 cm | 2.3-3.7 cm |
| 1st MT length | 5.6 cm | 5-6.4 cm |
| 2nd MT length | 6.7 cm | 5.9-7.7 cm |
| 1st MT-Calcaneus | 14.1 cm | 13-16.9 cm |
| 2nd MT-Calcaneus | 14.2 cm | 13-16.3 cm |
| 1st MT inclincation angle | 21 deg | 14.7-36.1 deg |
| 3rd MT-lateral sesamoid distance | 2.5 cm | 2.2-2.8 cm |

Table 4: Postoperative group measurements

| | Mean | Range |
|---|---|---|
| HVA | 10.2 deg | -16.5-23.2 deg |
| IMA | 7.2 deg | 2-16.8 deg |
| Meary's Angle | 2.1 deg | 0-5.3 deg |
| Pronation Angle | 8.3 deg | -9-25.1 deg |
| Sesamoid reduction Grade | 0 | 0 |
| 1-2 MT distance | 2.4 cm | 1.9-2.9 cm |
| 1st MT length | 5.2 cm | 4.2-5.8 cm |
| 2nd MT length | 6.5 cm | 5.5-7.3 cm |
| 1st MT-Calcaneus | 13.8 cm | 13-15.9 cm |
| 2nd MT-Calcaneus | 14.2 cm | 13-16.3 cm |
| 1st MT inclincation angle | 26.5 deg | 20.6-36.6 deg |
| 3rd MT-lateral sesamoid distance | 2.4 cm | 2.2-2.7 cm |

Table 5: Paired T-test for control vs preop

| | Mean | | Mean Difference | p-value |
|---|---|---|---|---|
| | Control | Preop | | |
| HVA | 13.1 deg | 38.5 deg | 25.3 deg | 0.00001 |
| IMA | 8.6 deg | 18.2 deg | 9.6 deg | 0.00001 |
| Meary's Angle | 1.4 deg | 9.5 deg | 8.1 deg | 0.001 |
| Pronation Angle | 2.7 deg | 13.9 deg | 11.3 deg | 0.00003 |
| Sesamoid reduction | 0 | 3 | N/A | 0.00001 |
| 1-2 MT distance | 2.3 cm | 3.0 cm | 0.7 cm | 0.00001 |
| 1st MT length | 5.9 cm | 5.6 cm | 0.3 cm | 0.032 |
| 2nd MT length | 7.1 cm | 6.7 cm | 0.4 cm | 0.022 |
| 1st MT-Calcaneus | 14.7 cm | 14.1 cm | 0.6 cm | 0.11 |
| 2nd MT-Calcaneus | 14.8 cm | 14.2 cm | 0.7 cm | 0.049 |
| 1st MT inclincation angle | 24.7 deg | 21 deg | 3.7 deg | 0.00026 |
| 3rd MT-lateral sesamoid distance | 2.4 cm | 2.5 cm | 0.1 cm | 0.055 |

Table 6: Paired T-test for control vs postop

| | Mean | | Mean Difference | p-value |
|---|---|---|---|---|
| | Control | Postop | | |
| HVA | 13.1 deg | 10.2 deg | 2.9 deg | 0.23 |
| IMA | 8.6 deg | 7.2 deg | 1.4 deg | 0.31 |
| Meary's Angle | 1.4 deg | 2.1 deg | 0.7 deg | 0.13 |
| Pronation Angle | 2.7 deg | 8.3 deg | 5.6 deg | 0.02 |
| Sesamoid reduction | 0 | 0 | N/A | 0.054 |
| 1-2 MT distance | 2.3 cm | 2.4 cm | 0.1 cm | 0.41 |
| 1st MT length | 5.9 cm | 5.2 cm | 0.7 cm | 0.00005 |
| 2nd MT length | 7.1 cm | 6.5 cm | 0.5 cm | 0.0014 |
| 1st MT-Calcaneus | 14.7 cm | 13.8 cm | 0.9 cm | 0.015 |

| | | | | |
|---|---|---|---|---|
| 2nd MT-Calcaneus | 14.8 cm | 14.2 cm | 0.6 cm | 0.073 |
| 1st MT inclincation angle | 24.7 deg | 26.5 deg | 1.8 deg | 0.16 |
| 3rd MT-lateral sesamoid distance | 2.4 cm | 2.4 cm | 2.1 cm | 0.31 |

Table 7: Paired T-test for preop vs postop

| | Mean | | Mean Difference | p-value |
|---|---|---|---|---|
| | Preop | Postop | | |
| HVA | 38.5 deg | 10.2 deg | 28.3 deg | 0.00001 |
| IMA | 18.2 deg | 7.2 deg | 11.0 deg | 0.00001 |
| Meary's Angle | 9.5 deg | 2.1 deg | 7.4 deg | 0.19 |
| Pronation Angle | 13.9 deg | 8.3 deg | 5.6 deg | 0.0046 |
| Sesamoid reduction | 3 | 0 | N/A | 0.00001 |
| 1-2 MT distance | 3.0 cm | 2.4 cm | 0.6 cm | 0.00003 |
| 1st MT length | 5.6 cm | 5.2 cm | 0.4 cm | 0.00001 |
| 2nd MT length | 6.7 cm | 6.5 cm | 0.2 cm | 0.018 |
| 1st MT-Calcaneus | 14.1 cm | 13.8 cm | 0.3 cm | 0.00062 |
| 2nd MT-Calcaneus | 14.2 cm | 14.2 cm | 0.1 cm | 0.42 |
| 1st MT inclincation angle | 21 deg | 26.5 deg | 5.6 deg | 0.00036 |
| 3rd MT-lateral sesamoid distance | 2.5 cm | 2.4 cm | 0.1 cm | 0.14 |

Table 8: Correlation of control IMA and 1st-2nd MT distance, 1st MT length and 1st MT-calcaneus distance, 2nd MT length and 2nd MT-calcaneus distance, and Meary's angle and 1st MT inclination angle

| IMA | 1st-2nd MT distance | R | Strength |
|---|---|---|---|
| 8.6 deg | 2.3 cm | 0.7 | Moderate |

| | | | |
|---|---|---|---|
| 1st MT length | 1st MT-calcaneus distance | R | |
| 5.9 cm | 14.7 cm | 0.73 | Moderate |
| 2nd MT length | 2nd MT-calcaneus distance | R | |
| 7.1 cm | 14.8 cm | 0.79 | Moderate |
| Meary's angle | 1st MT inclination angle | R | |
| 1.4 deg | 24.7 cm | 0.1 | Weak |

Table 9: Correlation of preop IMA and 1st-2nd MT distance, 1st MT length and 1st MT-calcaneus distance, 2nd MT length and 2nd MT-calcaneus distance, and Meary's angle and 1st MT inclination angle

| | | | |
|---|---|---|---|
| IMA | 1st-2nd MT distance | R | Strength |
| 18.2 deg | 3.0 cm | 0.73 | Moderate |
| 1st MT length | 1st MT-calcaneus distance | R | |
| 5.6 cm | 14.1 cm | 0.72 | Moderate |
| 2nd MT length | 2nd MT-calcaneus distance | R | |
| 6.7 cm | 14.2 cm | 0.84 | Strong |
| Meary's angle | 1st MT inclination angle | R | |
| 9.5 deg | 24.7 cm | -0.39 | Weak |

Table 10: Correlation of postop IMA and 1st-2nd MT distance, 1st MT length and 1st MT-calcaneus distance, 2nd MT length and 2nd MT-calcaneus distance, and Meary's angle and 1st MT inclination angle

| | | | |
|---|---|---|---|
| IMA | 1st-2nd MT distance | R | Strength |
| 7.2 deg | 2.4 cm | 0.87 | Strong |
| 1st MT length | 1st MT-calcaneus distance | R | |
| 5.2 cm | 13.8 cm | 0.65 | Moderate |
| 2nd MT length | 2nd MT-calcaneus distance | R | |
| 6.5 cm | 14.2 cm | 0.73 | Moderate |

| Meary's angle | 1st MT inclination angle | R | |
|---|---|---|---|
| 2.1 deg | 26.5 deg | -0.13 | Weak |

Table 11: Correlation of control pronation angle

| | Control | Control PA | R | Strength |
|---|---|---|---|---|
| | | 2.7 deg (-9.5-15.8) | | |
| HVA | 13.2 deg | | -0.037 | Weak |
| IMA | 8.6 deg | | 0.35 | Weak |
| 1st-2nd MT distance | 2.3 deg | | 0.49 | Weak |
| 1st MT-calcaneus distance | 14.7 deg | | 0.09 | Weak |

*PA- Pronation angle

Table 12: Correlation of preoperative pronation angle

| | Preop | Preop PA | R | Strength |
|---|---|---|---|---|
| | | 13.92 deg (-4.8-27.3) | | |
| HVA | 38.5 deg | | 0.3 | Weak |
| IMA | 18.2 deg | | -0.0008 | Weak |
| 1st-2nd MT distance | 3.0 deg | | 0.22 | Weak |
| 1st MT-calcaneus distance | 14.1 deg | | 0.17 | Weak |

*PA- Pronation angle

Table 13: Correlation of postoperative pronation angle

| | Postop | Postop PA | R | Strength |
|---|---|---|---|---|
| | | 8.3 deg (-9-25.1) | | |
| HVA | 10.2 deg | | 0.18 | Weak |
| IMA | 7.2 deg | | 0.26 | Weak |
| 1st-2nd MT distance | 2.4 deg | | 0.19 | Weak |
| 1st MT-calcaneus distance | 13.8 deg | | 0.22 | Weak |

*PA- Pronation angle

Table 14: 1st MT length percentage control vs preop and postop

| | | Control 1st MT % | Mean Difference | p-value |
|---|---|---|---|---|
| | | 83.7% | | |
| Preop 1st MT % | 84.1% | | 0.4% | 0.77 |
| Postop 1st MT % | 80% | | 3.7% | 0.033 |

Table 15: 1st MT length percentage preop vs postop

| Preop 1st MT % | Postop 1st MT % | Mean Difference | p-value |
|---|---|---|---|
| 84.1% | 80% | 4.1% | 0.0006 |

**Sources**


1. Canale, T., Beaty, J. (2013). *Campbel's Operative Orthopaedics.* Elsevier Inc.
2. Ross, F. (1986). The relationship of abnormal foot pronation hallux abducto valgus – a pilot study. *Prosthetics and Orthotics International*, 1986, 10, 72-78.
3. Sangeorzan, B., et al. (1989). Modified Lapidus Procedure for Hallux Valgus. *Journal of Foot and Ankle*, 1989, 9, 262-266.
4. Dayton, P., et al. (2015). Quantitative Analysis of the Degree of Frontal Rotation Required to Anatomically Align the First Metatarsal Phalangeal Joint During Modified Tarsal-Metatarsal Arthrodesis Without Capsular Balancing. *The Journal of Foot and Ankle Surgery*, 2015, 1-6.
5. Mahmoud, K., et al. (2020). The Role of Weightbearing Computed Tomography Scan in Hallux Valgus. *Foot & Ankle International*, 2020, 00(0), 1-7.
6. Hisateru Niki, et al. (2005). Development and reliability of a standard rating system for outcome measurement of foot and ankle disorders I: development of standard rating system. *J Orthop Sci.* 2005 Sep; 10(5): 457-465.

7. Kim, Y. J., et al. (2015). A New Measure of Tibial Sesamoid Position in Hallux Valgus in Relation to the Coronal Rotation of the First Metatarsal in CT Scans. *Foot & Ankle International,* 2015, 1-9.
8. Conti, M, et al. (2021). Correlation of Different Methods of Measuring Pronation of the First Metatarsal on Weightbearing CT Scans . *Foot & Ankle International,* 2021, I-II.
9. Campbell B, et al. Pilot study of a 3-dimensional method for analysis of pronation of the first metatarsal of hallux valgus patients. *Foot & Ankle International*. 2018;39(12):1449-1456.
10. Smith RW, et al. Hallux valgus assessment: report of research committee of American Orthopaedic Foot and Ankle Society. *Foot & Ankle International*. 1984;5(2):92-103.
11. Pauli, W et al. (2015). Fixation of the Proximal Metatarsal Crescentic Osteotomy Using a Head Locking X-Plate. *Foot & Ankle International,* 2015, 1-9.
12. Tanaka, Y et al. (1995). Radiographic Analysis of Hallux Valgus. *Journal of Bone and Joint Surgery,* 1995; 77-A.

APPENDIX:

Fig 1. Alpha angle described by Kim, et al.

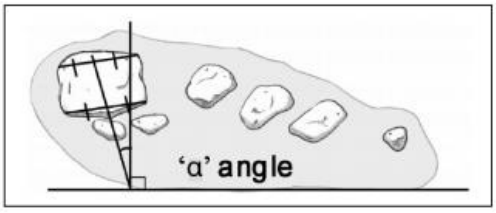

Fig 2. Sesamoid reduction grading by Smith, et al.

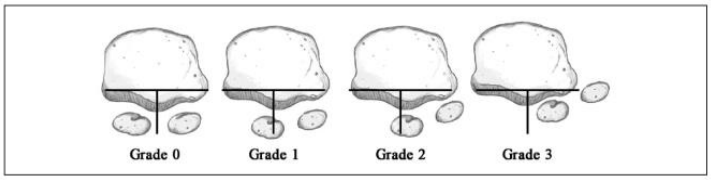

Fig 3. 1st metatarsal length




Fig 4. 2nd metatarsal length

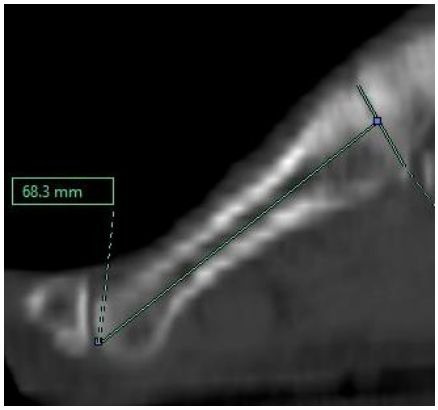


Fig 5. 1st-2nd metatarsal distance

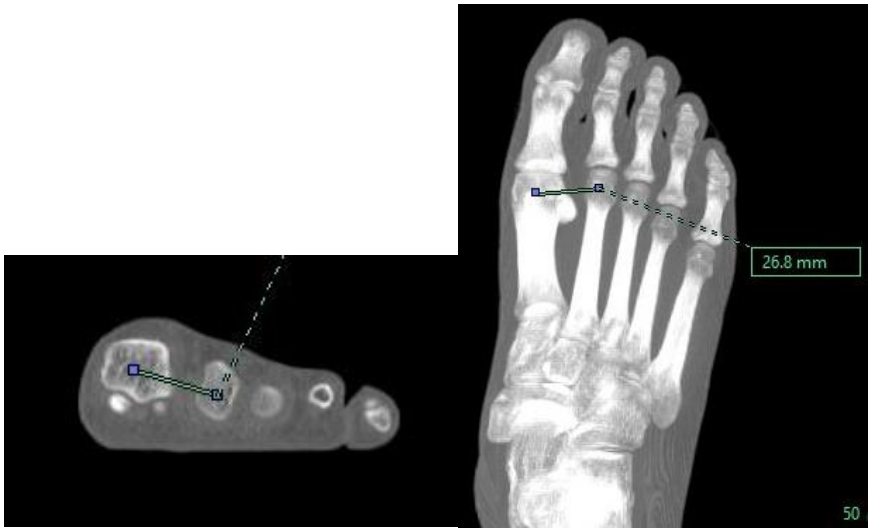

Fig 6. 1st and 2nd metatarsal distance from calcaneus

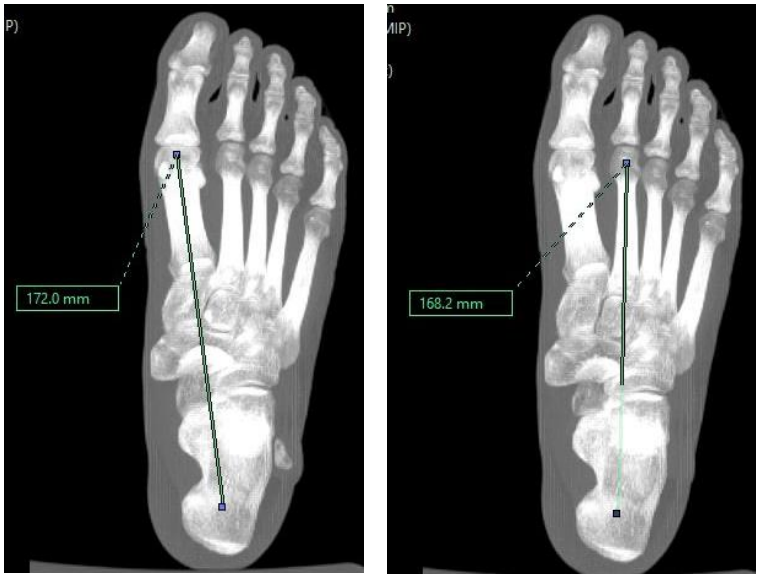


Fig 7. 1st metatarsal inclination angle relative to the floor

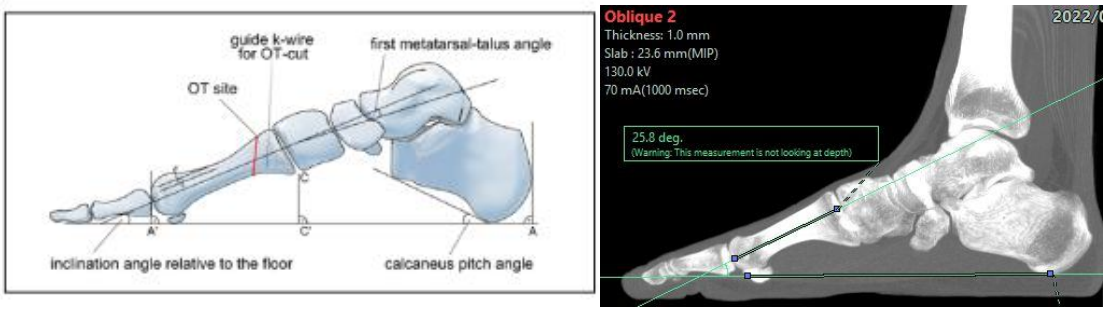


Fig 8. 3rd MT-lateral sesamoid distance

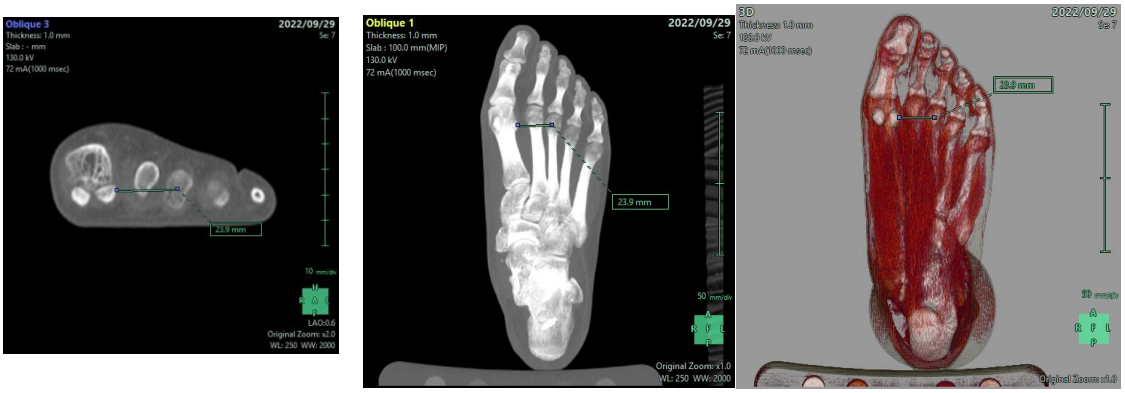

Fig 9. Scatter plot of control IMA and 1st-2nd MT distance

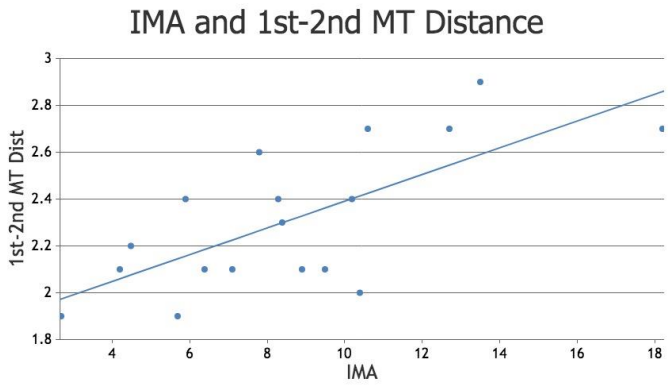


Fig 10. Scatter plot of control MT1 length and MT1-calcaneus distance

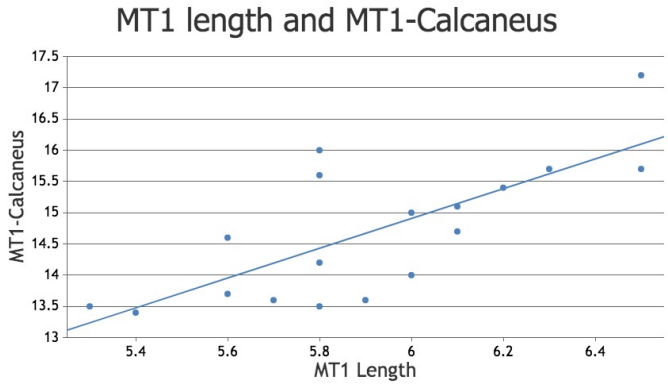


Fig 11. Scatter plot of control MT2length and MT2-calcaneus distance

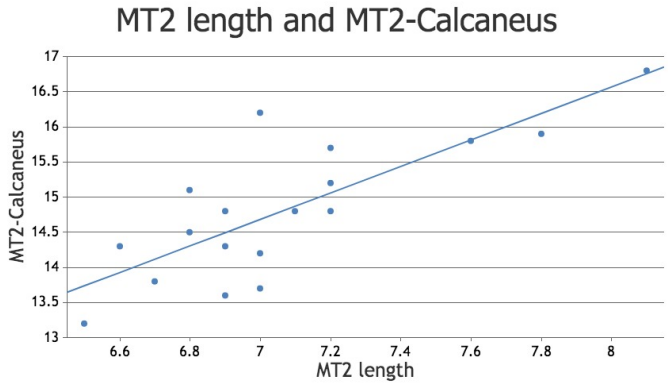


Fig 12. Scatter plot of control Meary's angle and 1st MT inclination angle

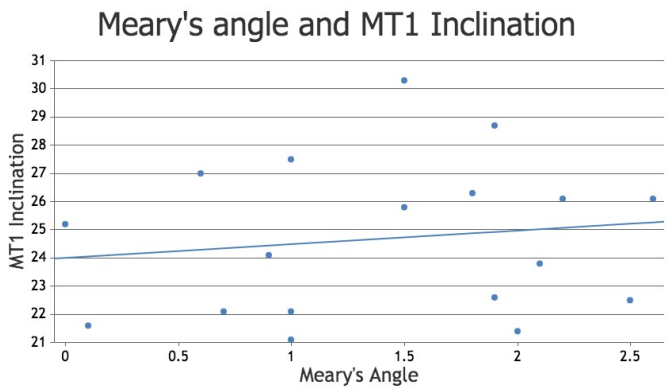


Fig 13. Scatter plot of preoperative IMA and 1st-2nd MT distance

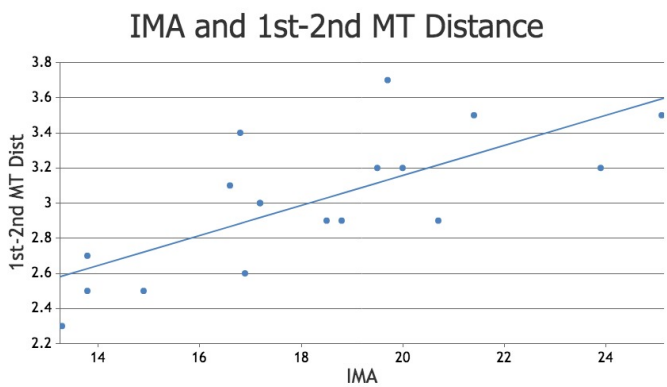


Fig 14: Scatter plot of preoperative MT1 length and MT1-calcaneus distance

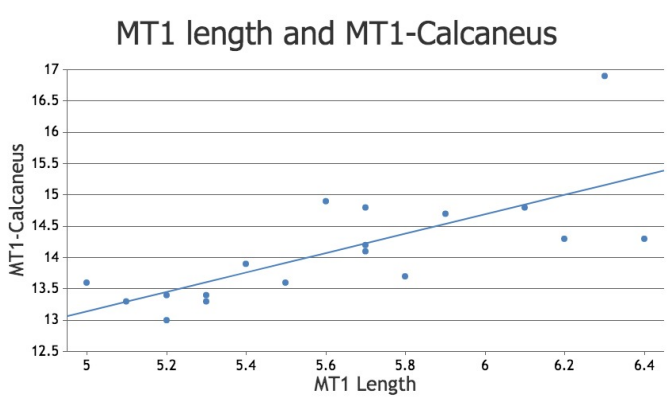


Fig 15: Scatter plot of preoperative MT2length and MT2-calcaneus distance

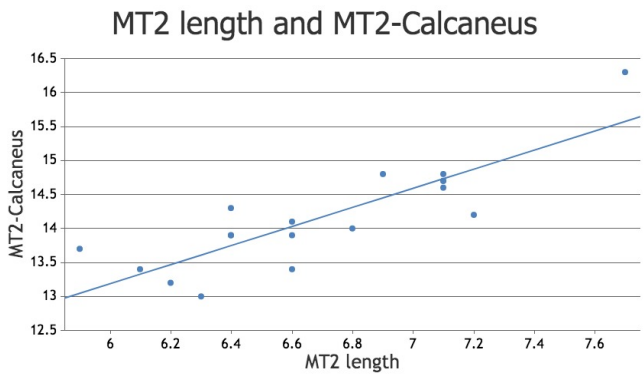


Figure 16: Scatter plot of preoperative Meary's angle and 1st MT inclination angle

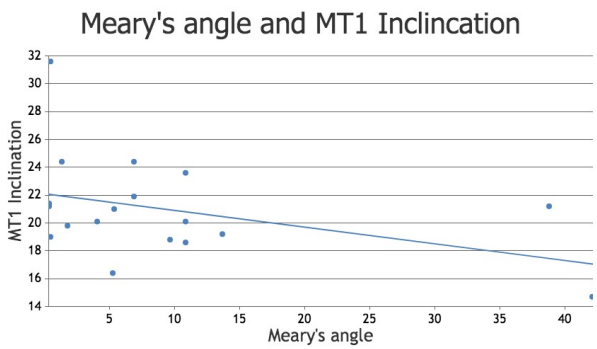


Fig 17: Scatter plot of postoperative IMA and 1st-2nd MT distance

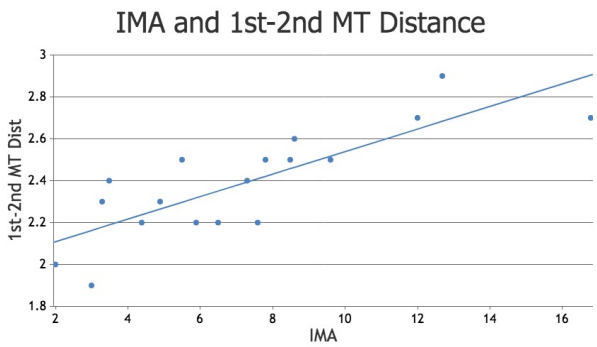


Fig 18: Scatter plot of postoperative MT1 length and MT1-calcaneus distance

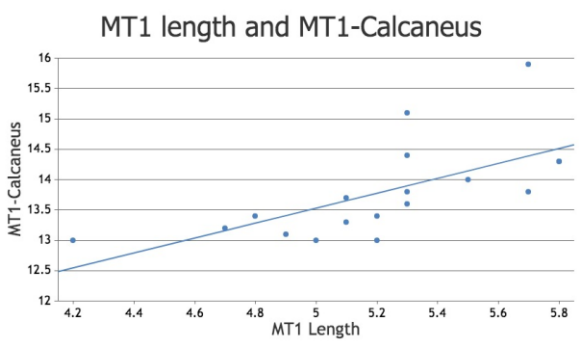


Fig 19: Scatter plot of postoperative MT2length and MT2-calcaneus distance

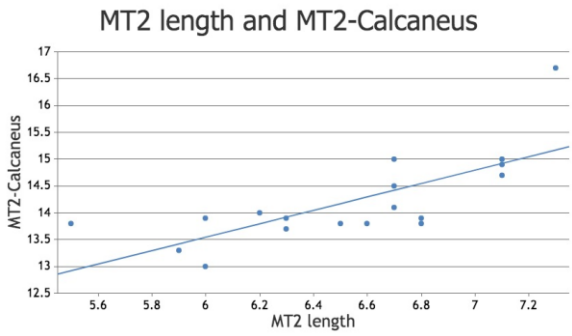

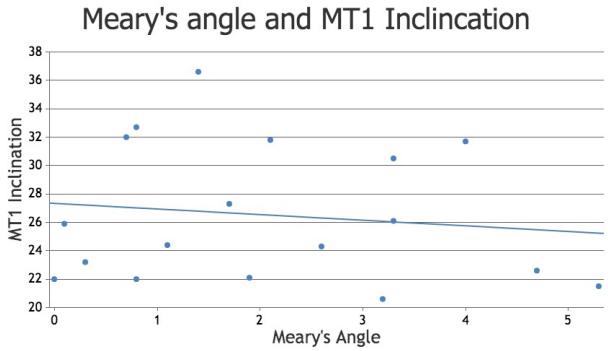
Fig 20: Scatter plot of preoperative Meary's angle and 1st MT inclination angle