Use of 3D printer in upper limb surgery service.
Case: Scafolunate ligament lesion, RASL procedure with 3D guide pin.

Irigoitia Nicolas; Mantovani Gustavo.

Key Words: upper limb, 3D printer, orthotics, 3D guide, minimally invasive surgery, percutaneous procedure.

Summary

There are numerous uses for the 3D printing technology in the field of medicine. The ability to create with high fidelity and accuracy 3D objects allows the physician several possibilities for the orthopaedic management of patients, like bone models for surgical planning, guides for osteotomies, percutaneous procedures and specific orthoses.
Currently the costs of a 3D printer equipment, supplies and software has dropped by more than 10 times from its initial cost, being nowadays affordable for the average orthopaedic surgeon.
The most common uses involves complex cases, where the bone deformities are tridimensionally difficult to understand intraoperatively, and impossible to provide the expected accuracy on the conventional surgical techniques, as like forearm deformities. Other frequent situations that requires precision such percutaneous fixation on the carpal bones also can be good indications.
The 3D printing process starts in the 3D digital planning of the surgery using 3D digital models from the patients CT scans, and can be based both on the bones and the soft tissues images. The 3D planning is the most time-consumption step of the process, and intends to provide a quicker and easier surgical procedure. It is mandatory for a good outcome and a successful planning that the physician involved on the process have a consistent surgical experience since this will be reflected on the virtual surgical procedure performed during the design step.
The main purpose of this work is to show the advantages by using this tool on a common hand injury and a classical hand procedure, that could bring a novel outcome and new perspective for its indications.

Introduction

Operative treatment of scapholunate (SL) ligament disruption is often recommended to decrease. pain and prevent a predictable degenerative progression to SL advanced collapse (SLAC) [1]. Multiple procedures have been described in the literature, including ligament reconstruction [2,3], dorsal ligament capsulodesis[4,5] and carpal arthrodesis[6,7]. In 1997, Rosenwasser et al described the reduction and association of the scaphoid and lunate (RASL) procedure, which aims to achieve a bon or fibrous link between the scaphoid and the lunate[8]. Initial reports demonstrated positive results at short and midterm follow-up[8,9]. An arthroscopically assisted technique was described by Aviles et al.[10] Subsequent outcome studies, however, have demonstrated poor results with an inability to maintain radiographic reduction of the scaphoid and a high reoperation rate[11-14].
Management of chronic SL instability presents a particular challenge to surgeons as outcomes of various techniques have been inconsistent[15]. Rosenwasser et al reported on 32 patients who underwent the RASL procedure and noted that only 2 patients required salvage procedures for progressive degenerative changes[8]. The authors noted maintenance of the radiographic reduction of the scaphoid and lunate. With the goal of

creating a pseudoarthrosis, there is preserved motion between the scaphoid and the lunate about the screw. As the wrist moves through planes of motion, there is rotation, translation, flexion–extension, and radioulnar deviation that occur, which could theoretically cause a high rate of loosening of the implant[16,17].
Koehler et al also attempted to describe the optimal technical considerations of the RASL procedure[14]. First, screw length and position was reviewed. They surmised that leaving one to two threads in the scaphoid cortex improved outcomes, thus requiring a longer screw. The authors further suggested that placement of the screw in the volar pole of the lunate along the proximal-ulnar corner provided the best fixation.
For these reasons, precision for screw placement is essential. Through 3D models and the manufacture of guides, it is possible to plan the best placement site for the screw, in its axis of rotation, thus trying to avoid complications that occur due to site failure. screw placement.

Case presentation

52 year old male patient, physician, skilled right hand. He refers to a traumatic injury to his right wrist that had developed 2 months after a fall from his own height.
Show no improvement with 1 month of physiotherapy. Presenting in the consultation dorsal scapholunate pain of 9/10 on the visual analog scale of pain (VAS), his motion were 40º flexion and 50º extension, both painful. His Mayo Wrist Score was 30 points.
In the imaging studies, a scapholunate gap of 4 mm can be observed, without signs of scaphoid flexion or extension of the lunate, without arthritic changes of the wrist. (Fig. 1)

Management and outcomes

It was decided to perform a RASL type procedure with arthroscopic assistance and 3D guides.
A CT was carried out to obtain images for the design of the guide. The program used for the preparation and edition was mimic 3D.(Fig. 2)
The time for editing it was 10 hours. The impression was on a XYZ printing pro 3d printer in PLA 2 material, which took 6 hours (Fig. 3).
For its sterilization, 80% alcohol was used for 1 hour, with the placement of sterile covers for handling, due to the impossibility of sterilization with heat.
For the surgical procedure, we proceeded in the usual way, with placement of a hemostatic cuff and 8kg traction. Performing an arthroscopic examination, using portals 3/4 and 6 R, the joint inventory was performed, noting a complete lesion of the SL ligament and complete rupture of dorsal intercarpal ligament (DIC) at its insertion of the Scaphoid.
We opted for debridement of the SL remnants and cleaning of the SL joint, reinsertion of the DIC in the scaphoid with a 1.7mm Arthrex Corkscrew anchor.
Once this was achieved, the use of the guide continued. It was placed and ensured for its correct alignment (Fig. 4). The passage of the 1.5 mm system k wire was made. With the subsequent withdrawal of the guide, its correct alignment was verified under fluoroscopy (Fig. 5).
The drill passage of the system was passed, with subsequent placement of the 3.5mm Arthrex screw of 28mm length to achieve the RASL technique.
After a second and final fluoroscopy check to verify the correct reduction. the skin portals were closed with nylon.
Subsequently, a plaster splint was placed for 2 weeks.

Total surgery time was 48 minutes and radioscopy time was less than one minute, only 47 seconds.
After the removal of stitches in the second week, her rehabilitation began with assisted passive mobility exercises.
In his control at 6 weeks, he presented a VAS of 1/10, a mobility of 60º flexion, 70º extension, his Mayo score was 90 points. The X rays verified the correct reduction was and show no sign of loosening (Fig. 7)

Discussion of the case

Advances in technology allow the improvement of existing procedures and the reception of new techniques. The incorporation of 3D guides to perform percutaneous procedures with greater ease and a more predictable prognosis is something not to be missed. In this particular case, it seems to be very favored by being able to allow trial and error in 3D models where the best place for the implant will be. In addition to not needing a dorsal or radial approach, arthrotomy or esthyloidectomy, which translates into less aggression and faster recovery. This type of technique is also reproducible for other pathologies and the placement of other types of systems. I think it is a great tool that should be taken into account for future procedures since the value it can provide is very great, being able to shorten surgery times and complications in different pathologies, both fractures and instabilities, and not being restricted only to the upper limb.

References

1- Watson HK, Ballet FL. The SLAC wrist: scapholunate advanced collapse pattern of degenerative arthritis. J Hand Surg Am 1984;9 (03):358.

2- Garcia-Elias M, Lluch AL, Stanley JK. Three-ligament tenodesis for the treatment of scapholunate dissociation: indications and surgical technique. J Hand Surg Am 2006;31(01):125–134.

3-Links AC, Chin SH, Waitayawinyu T, Trumble TE. Scapholunate interosseous ligament reconstruction: results with a modified Brunelli technique versus four-bone weave. J Hand Surg Am 2008; 33(06):850–856.

4- Szabo RM, Slater RR Jr, Palumbo CF, Gerlach T. Dorsal intercarpal ligament capsulodesis for chronic, static scapholunate dissociation: clinical results. J Hand Surg Am 2002;27(06):978–984.

5-Moran SL, Cooney WP, Berger RA, Strickland J. Capsulodesis for the treatment of chronic scapholunate instability. J Hand Surg Am. 2005;30(01):16–23.

6-Kleinman WB, Carroll C IV. Scapho-trapezio-trapezoid arthrodesis for treatment o chronic static and dynamic scapho-lunate instability: a 10-year perspective on pitfalls and complications. J Hand Surg Am 1990;15(03):408–414.

7-Watson HK, Ryu J, Akelman E. Limited triscaphoid intercarpal arthrodesis for rotatory subluxation of the scaphoid. J Bone Joint Surg Am 1986;68(03):345– 349.

8-Rosenwasser MP, Miyasajsa KC, Strauch RJ. The RASL procedure: reduction and association of the scaphoid and lunate using the Herbert screw. Tech Hand Up Extrem Surg 1997;1(04):263–272.

9-White NJ, Raskolnikov D, Swart E, Rosenwasser MP. Reduction and association of the scaphoid and lunate (RASL): long-term follow-up of a reconstruction technique for chronic scapholunate dissociation. J Hand Surg Am 2010;35(10):16–17.

10-Aviles AJ, Lee SK, Hausman MR. Arthroscopic reduction-association of the scapholunate. Arthroscopy 2007;23(01):105.e1–105.e5.

11-LarsonTB, Stern PJ. Reduction and association of the scaphoid and lunate procedure: short-term clinical and radiographic outcomes. J Hand Surg Am 2014;39(11):2168–2174.

12-Caloia M, Caloia H, Pereira E. Arthroscopic scapholunate joint reduction. Is an effective treatment for irreparable scapholunate ligament tears? Clin Orthop Relat Res 2012;470(04):972–978.

13-Cognet JM, Levadoux M, Martinache X. The use of screws in the treatment of scapholunate instability. J Hand Surg Eur Vol 2011; 36(08):690–693.

14-Koehler SM, GuerraSM, KimJM, Sakamoto S,Lovy AJ,Hausman MR. Outcome of arthroscopic reduction association of the scapholunate. joint. J Hand Surg Eur Vol 2016;41(01):48–55.

15-Manuel J, Moran SL. The diagnosis and treatment of scapholunate instability. Hand Clin 2010;26(01):129-144.

16-Kobayashi M, Berger RA, Nagy L, et al. Normal kinematics of carpal bones: a three dimensional analysis of carpal bone motion relative to the radius. J Biomech 1997;30(08):787–793.

17-Ruby LK, Cooney WP III, An KN, Linscheid RL, Chao EY. Relative motion of selected carpal bones: a kinematic analysis of the normal wrist. J Hand Surg Am 1988;13(01):1–10.

Figures

Fig.1

Scapholunate gap of 4 mm can be observed, without signs of scaphoid flexion or extension of the lunate, without arthritic changes of the wrist.

Fig 2

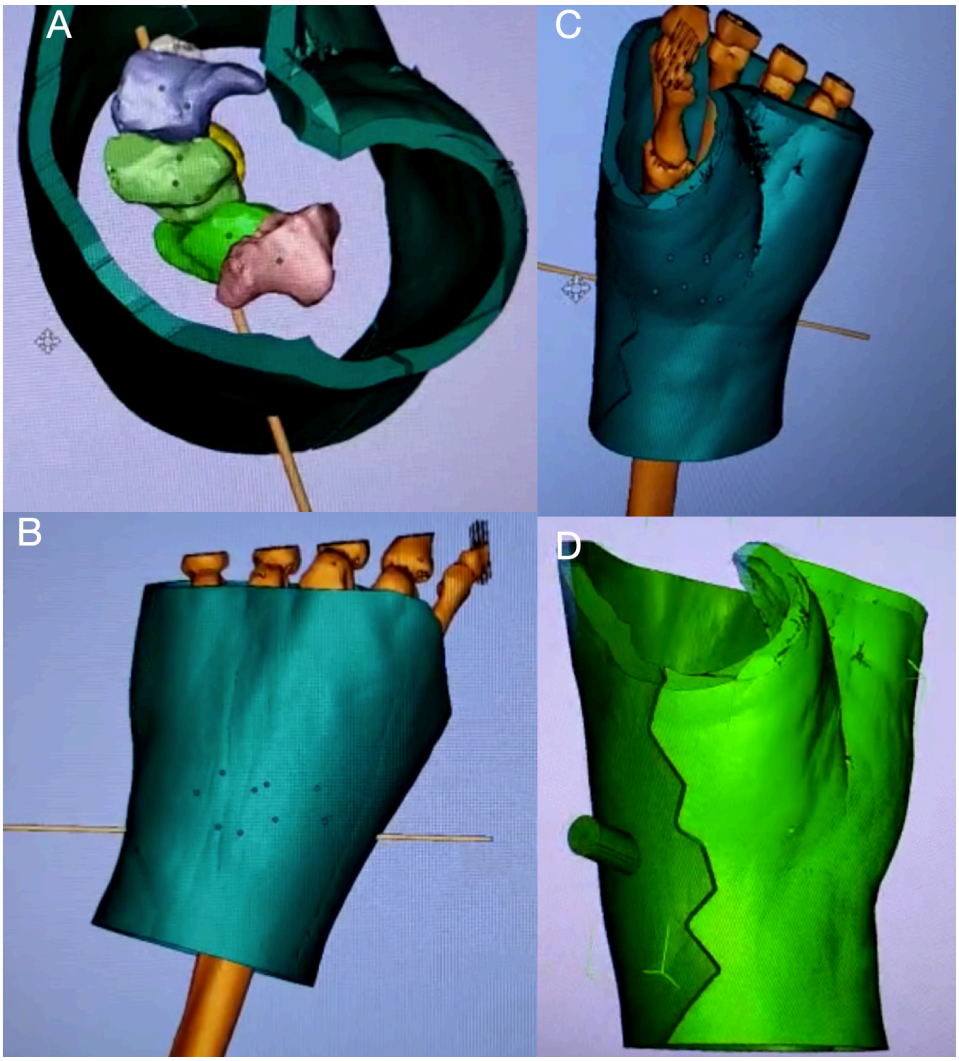

3D model design, with guide pin view.(A-C). Final 3D model pre print (D).

Fig 3.



Final 3D printed model.

Fig 4.

3d guide applied to the patient. After closure, it is firmly secured with a bandage.

Fig. 5

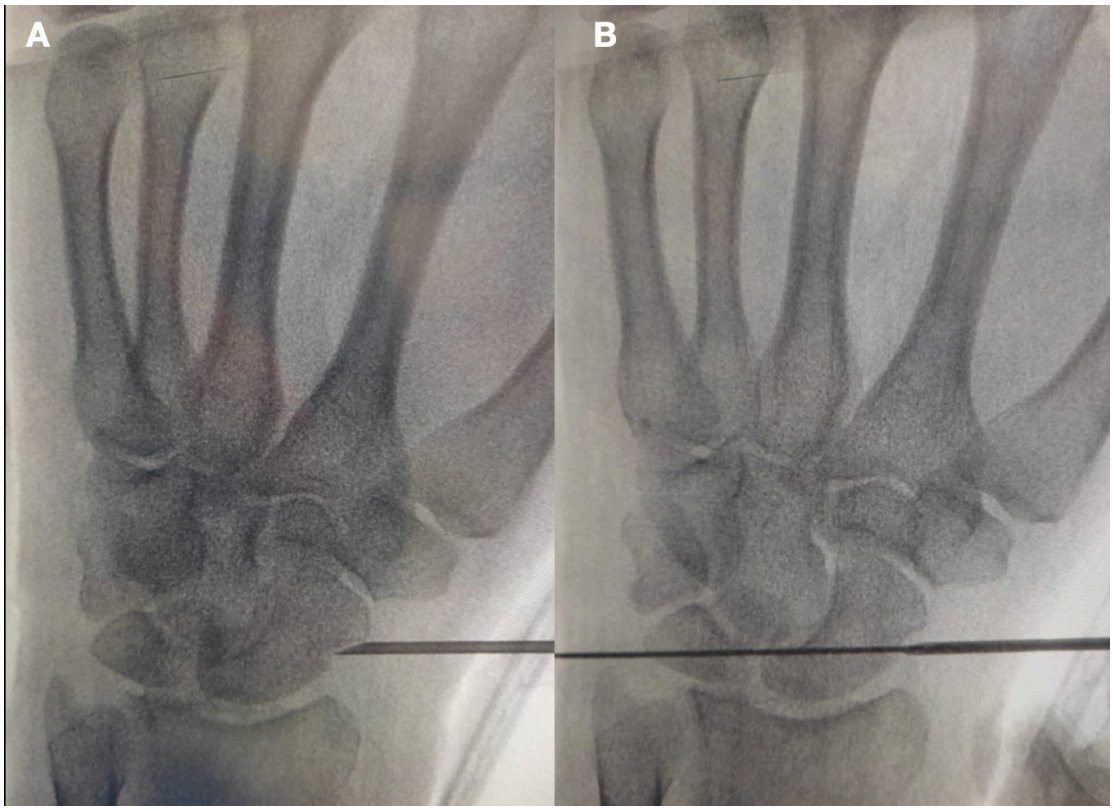

The correct location of the abocath was verified with fluoroscopy (A). Subsequently, the k-wire was passed through it from the scaphoid to the lunate at the isometric point of movement (B).

Fig. 6

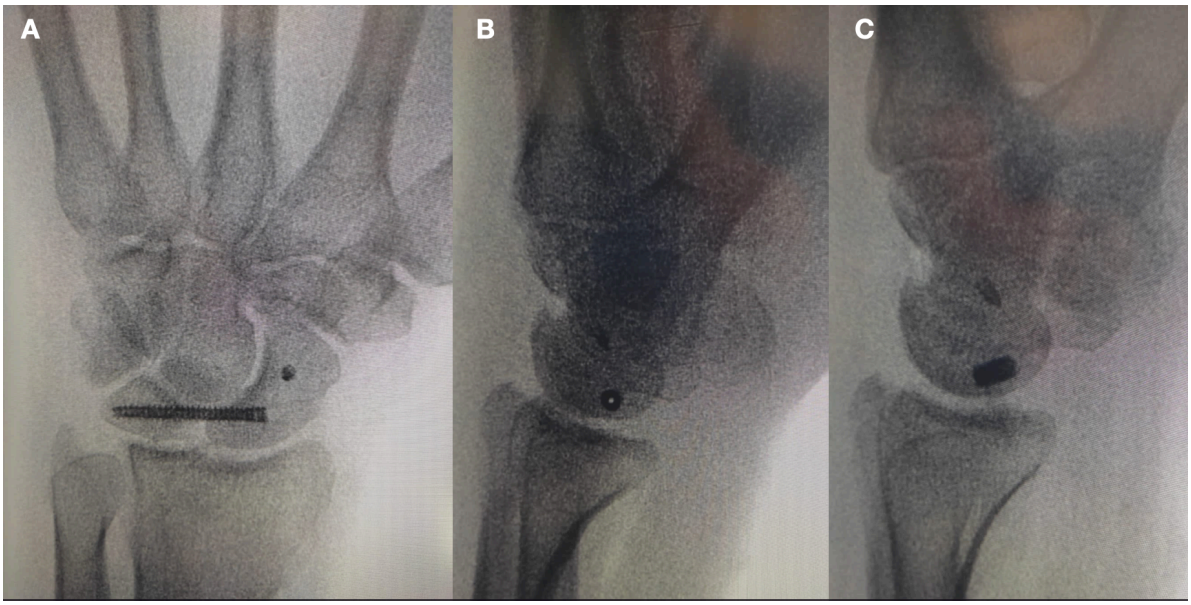

Final radioscopy, noting the closure of the scapholunate gap, correct isometric alignment of osteosynthesis.

Fig. 7

The X rays verified the correct reduction was and show no sign of loosening.