Dental School at Araraquara, SP,
São Paulo State University (UNESP).
Fellowship Director: Mario F. R. Gabrielli

Simultaneous surgical treatment of posttraumatic bilateral temporomandibular joint ankylosis by customized TMJ prosthesis

V A Pereira Filho, MFR Gabrielli, J C Santos, MD Salmen, C Mochizuki, R De Marco, A Jaxa-Kwiatkowski

Keywords: Posttraumatic TMJ Disorders, TMJ ankylosis, TMJ prosthesis.

Summary

TMJ ankylosis is the fusion of the mandibular condyle with the glenoid fossa, impairing the normal articulation and immobilizing the mandible. This can either be partial or complete inability to open the mouth, resulting in functional impairment or growth deformities of the mandible. Ankylosis can occur in a simple fibrous restriction of jaw movement or can progress to bone formation within the joint, restricting movement completely. Both fibrous or bony adhesions restrict condylar translation thus limiting jaw mobility and function.

In this article we present the case of a 63-year-old male patient with posttraumatic bilateral ankylosis of the temporomandibular joints. The patient suffered severe jaw injury being hit by a motorcyclist at the age of 12 in 1970. He first came to the hospital due to a significant restriction in the mobility of the temporomandibular joints in 2017. Surgery was performed in the Hospital São Paulo - Unimed in Araraquara, Brazil, in 2021.

Introduction

True ankylosis is caused by either fibrous or bony fusion of the structures contained within the TMJ capsule and, in its most severe state, is characterized by a bony union of the condyle to the glenoid fossa. True ankylosis can be subclassified depending on the anatomic positioning of the condyle and the extent of bridging bone. [1,4,7]

There is three-stage classification to grade complete ankylosis, as follows:

- stage I, ankylotic bone limited to the condylar process;
- stage II, ankylotic bone extending to the sigmoid notch;
- stage III, ankylotic bone extending to the coronoid process.[12]

Ankylosis may lead to chronic, persistent, and progressive inability to open the mouth, facial deformity, and obstructive sleep apnea–hypopnea syndrome[1]

At present, surgical excision of the bone mass by gap arthroplasty is the only effective treatment approach to release the fused TMJ and relieve the clinical symptoms of TMJA.[2] However, this surgery

is challenging and technically demanding because of the proximity to nerves, vessels, and skull base in this region.

The results of experimental studies suggest that cartilage injury of the glenoid fossa might lead to fibrous ankylosis and the bone injury of the glenoid fossa might lead to bony ankylosis under conditions of disc displacement.[1,3]

The etiology of TMJA is broadly categorized into traumatic injuries, infection and previous TMJ surgery, but the reason for the propensity to develop TMJA is not known. It affects the quality of life by interfering with mastication, speech, maintenance of oral hygiene and poor esthetics.[5-7] Facial trauma is the most frequent cause of ankylosis, common development of hematoma may eventually lead to its organization and ossification.[4]

The diagnosis of the TMJ ankylosis is determined by clinical examination and imaging tests such as CT-scans and magnetic resonance imaging (MRI). The ultimate goal in treatment of TMJ ankylosis is restoration of the function of the masticatory system with stable results, correction associated facial deformity, reduction of pain, and prevention of re-ankylosis. [9,11]

Recent studies show strong correlation of age at injury with prevalence and severity of TMJ ankylosis and potential coexistence of facial malformations. Children have greater growth and reparative potential. Pediatric mandible has a broad condyle and thin cortical bone, which predispose children to intra-capsular comminuted fractures. In contrast, the elongated condylar neck in adults usually limits fractures to the extracapsular space.[10]

Total joint reconstruction can be divided into autogenous replacement such as costochondral (CCG) and sternoclavicular grafts (SCG), or alloplastic reconstruction.[13]

Surgical treatment of ankylosis of the temporomandibular joints is an extremely difficult procedure with many perioperative risks and the risk of recurrence, therefore it seems to be advisable to be vigilant and to make early diagnosis and prevent evolution towards ankylosis.[8]

Case Presentation

A 63-year-old patient suffered a jaw injury after being hit by a motorcyclist at the age of 12 in 1970. From the patient's report after the accident, a radiograph was taken which showed a jaw fracture. Due to the lack of availability of the patient's medical history from this period, there is no precise data on the course of the fracture fissures. Based on the clinical picture, we can assume with high probability that it was a fracture of both condylar processes in the mandible. Due to the limited availability of specialized treatment in Brazil at that time, the patient did not receive adequate treatment and rehabilitation of the temporomandibular joints. The trauma was accompanied by chronic pain, and a few years after the injury the symptoms were joined by severe restriction of opening and closing the jaws. The patient first came to the Division of Oral and Maxillofacial Surgery of the Araraquara Dental School (UNESP), SP, Brazil due to a significant restriction in the mobility of the temporomandibular joints in 2017. He had no outstanding comorbidities, but was a smoker and heavy drinker. Jaw opening decreased up to 22mm as measured from the remaining left canine to the edentulous mandibular ridge. (Presurgery Pictures 1-6)

Pic. 1-3 Pre-operative appearance of the patient

Pic. 4 Intraoral view

Pic.5 Forced mouth opening

Pic 7. Intraoral jaw opening measurement

Management and Outcome

The patient was prepared for surgery to remove the ankylotic masses and reconstruct the joints bilaterally with custom temporomandibular joint prosthesis. Computed tomography scans were obtained. The right TMJ showed signs of complete ossification, in the left TMJ a component of fibrosis was expected. Detailed planning of the procedure was performed with use of 3D technology. The project and production of individualized titanium prostheses for the temporomandibular joints was commissioned to the company Traumec, Rio Claro, SP, Brazil. The procedure was performed on November 3, 2021 in the Hospital São Paulo - Unimed, at Araraquara, Brazil. During the operation, neuromonitoring was used to minimize the risk of paralysis of the facial nerve. The main principles were satisfactory resection of the ankylotic segment and proper fixation of both parts of the prosthesis. The ankylosed mass was carefully exposed in both sides. The osteoctomies and drilling were made after fixing the pre-planned rails and operating guides. A surgical splint was installed in the oral cavity to recreate correct mandibular positioning and interarch spacing, in order to allow subsequent prosthetic works. Intraoperative observation showed that the left disc was considerably intact, so it was reflected medially and used to protect the soft tissue structures medial to the mandible. Abdominal fat was collected from the suprapubic region for autogenous fat graft and packed around the prosthetic devices of both temporomandibular joints. All wounds were closed in layers and heavily dressed. The preoperative and postoperative course was uneventful. After the surgery the patient was admitted to the ICU for postoperative care. He was kept in the hospital for 7 days, mostly because he was not trustworthy regarding the correct use of postoperative antibiotics and was discharged in good general and local condition.

We present below images of the ankylosed joints, treatment planning, surgery and postoperative photos 15 days after the surgery. Partial paralysis of the marginal branch of the mandible of the right facial nerve was not avoided, but it is expected to be temporary due to the absence of severe damage displayed by the neuromonitoring. Postoperative view of the profile shows superficial soft tissue necrosis in the preauricular area on both sides, due to excessive manipulation and retraction, currently being treated.(Pictures 6-44)

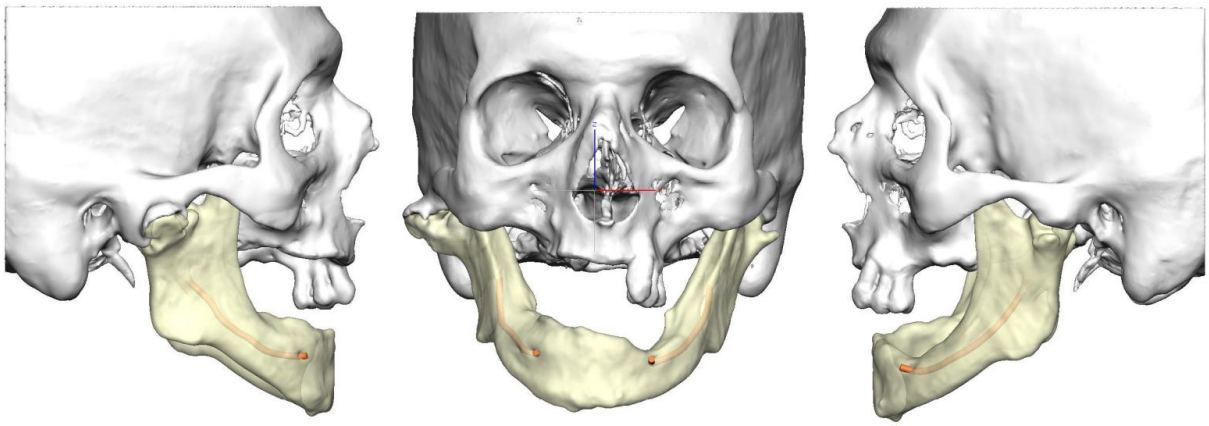

Pic. 6 Preoperative 3D reconstruction based on CT scan

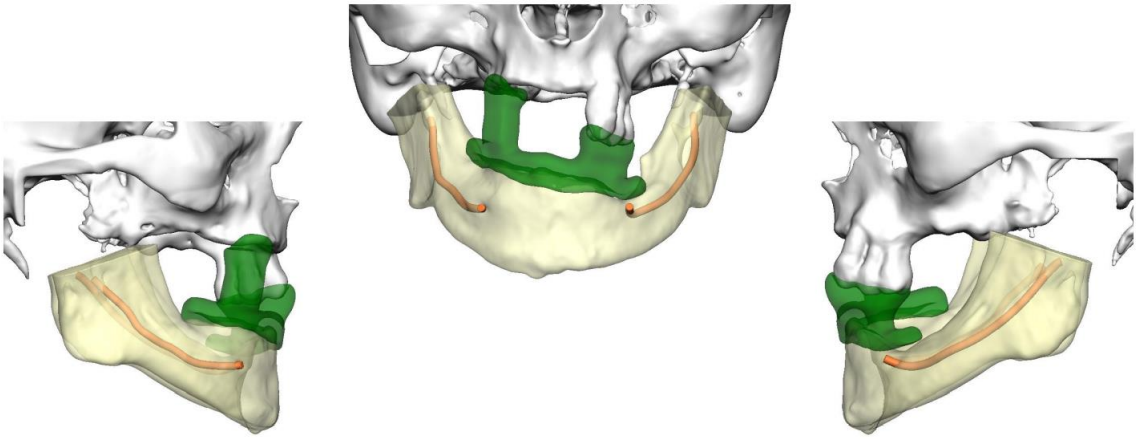

Pic.8 Project of the osteotomy along with occlusion guide splint.

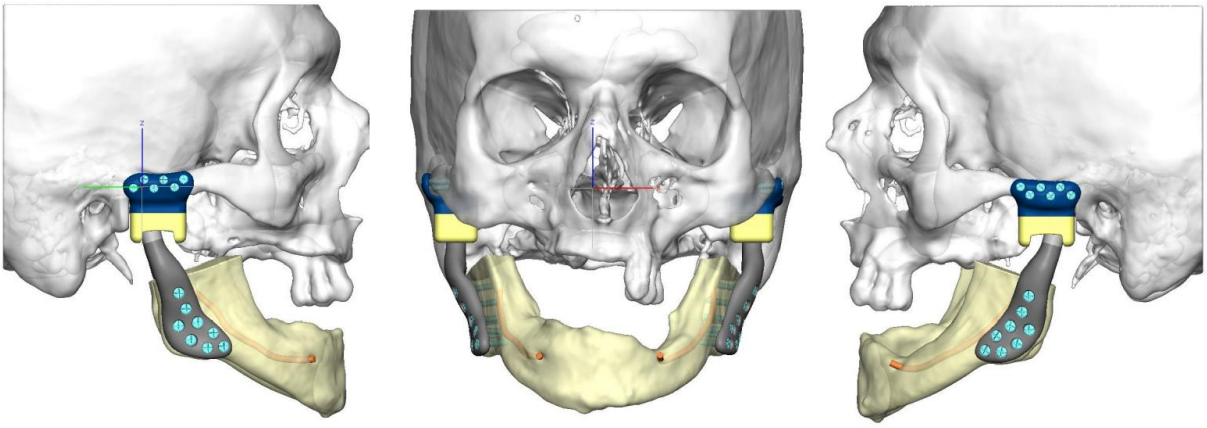

Pic. 9 Project of 3D planned prosthesis correct location.

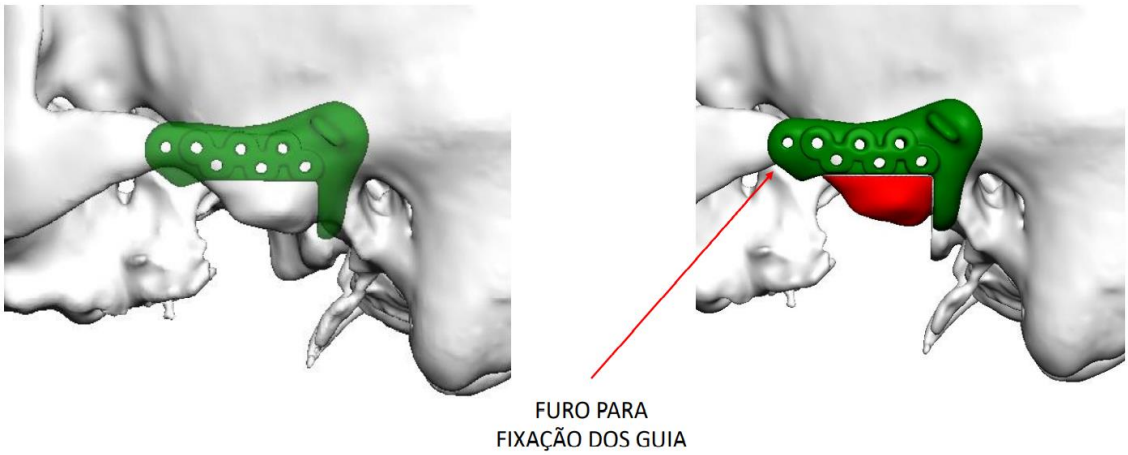

Pic 10. Project of osteotomy guide along with drilling guide at the zygomatic arch.

Pic 11. Project of osteotomy guide along with drilling guide at the ramus of the mandible.

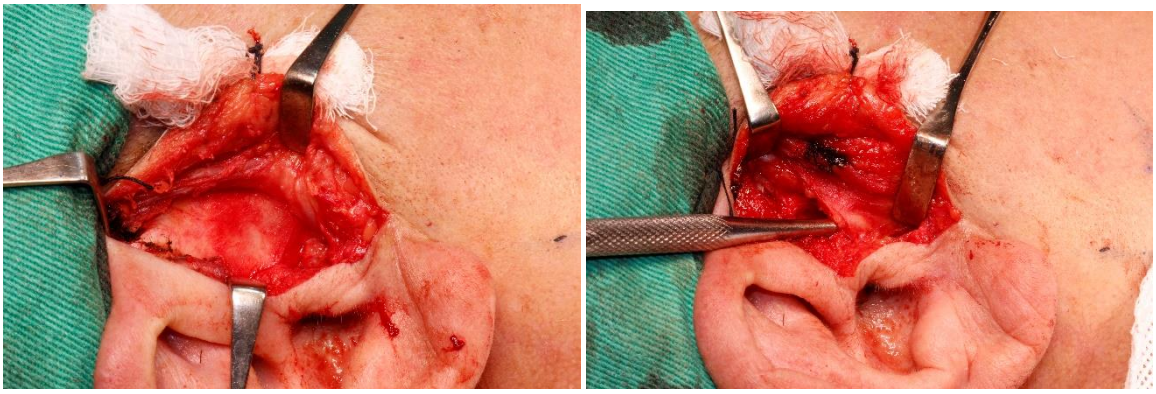

Pic. 12 and 13. Preauricular access to the ankylotic right TMJ

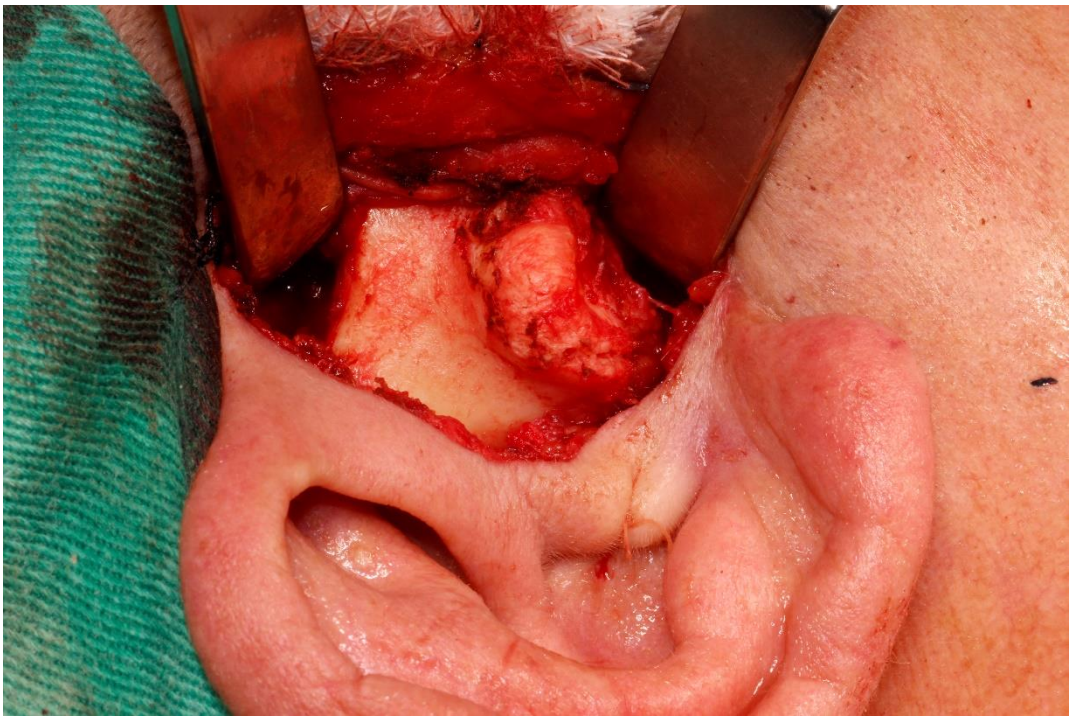

Pic. 14. Bony fusion of the structures contained within the right TMJ

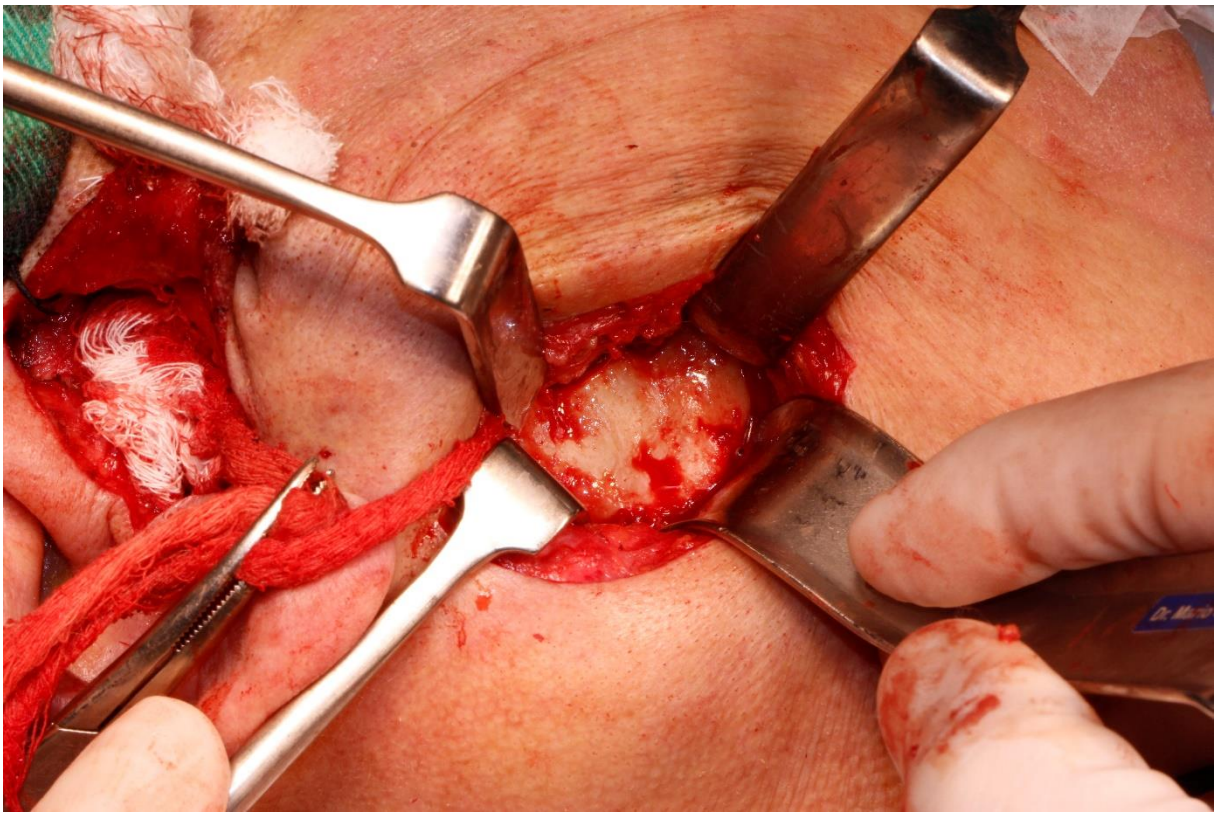

Pic. 15. Broad access to the right ramus of the mandible.

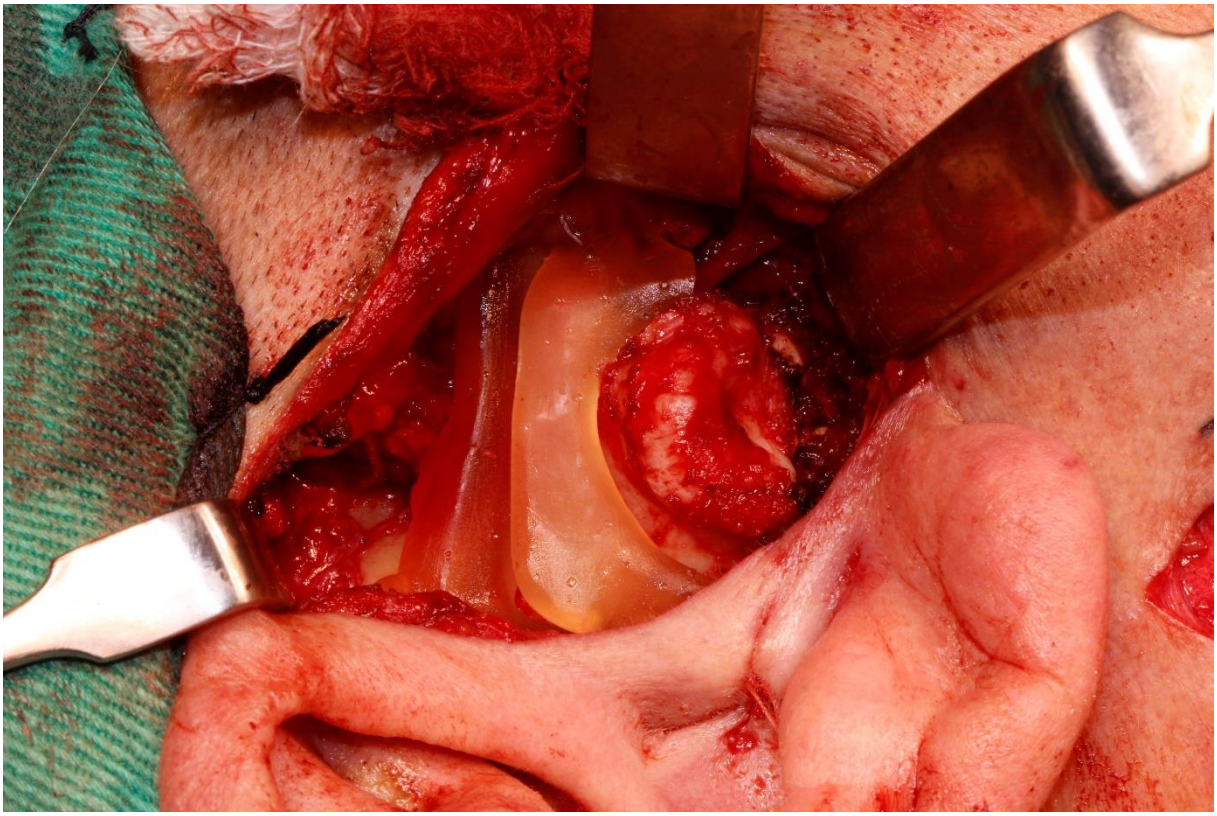

Pic. 16. Osteotomy guide installed correctly on the right zygomatic arch.

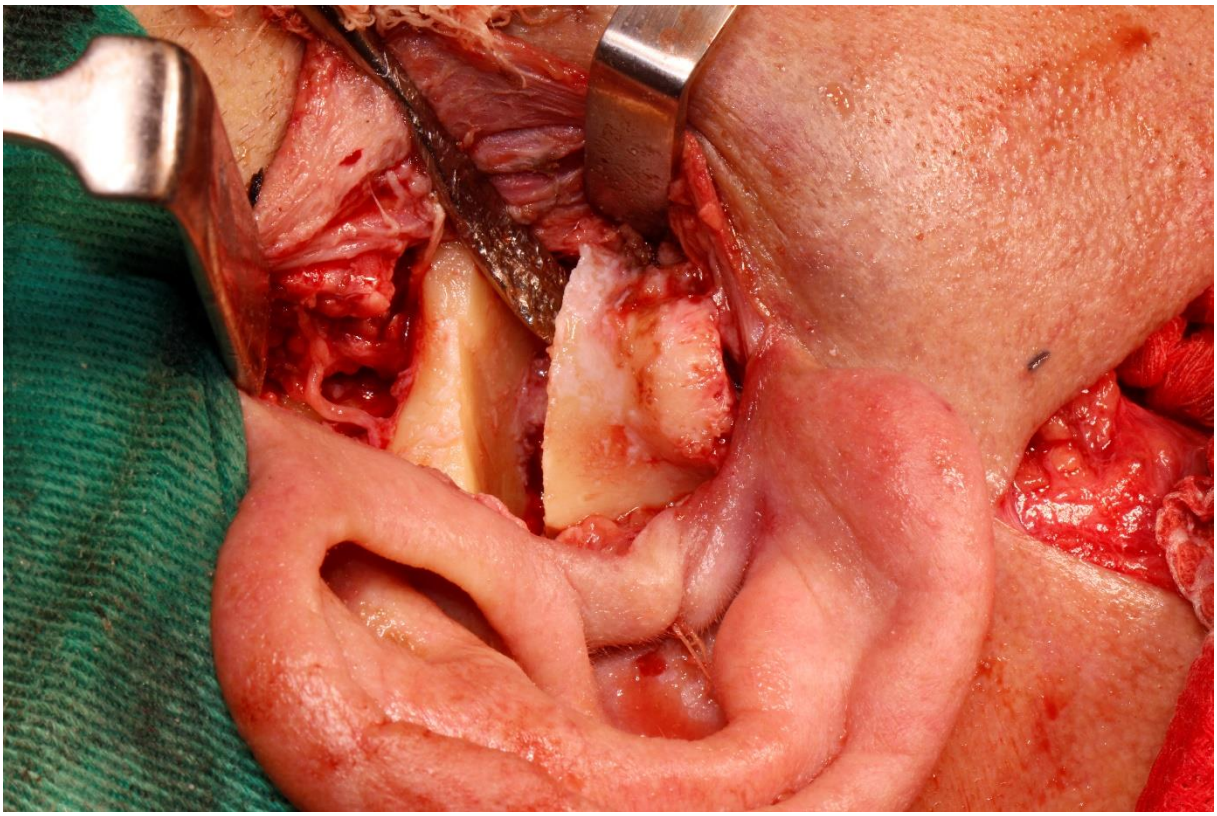

Pic. 17. Osteotomy of the ankylotic bone fragment.

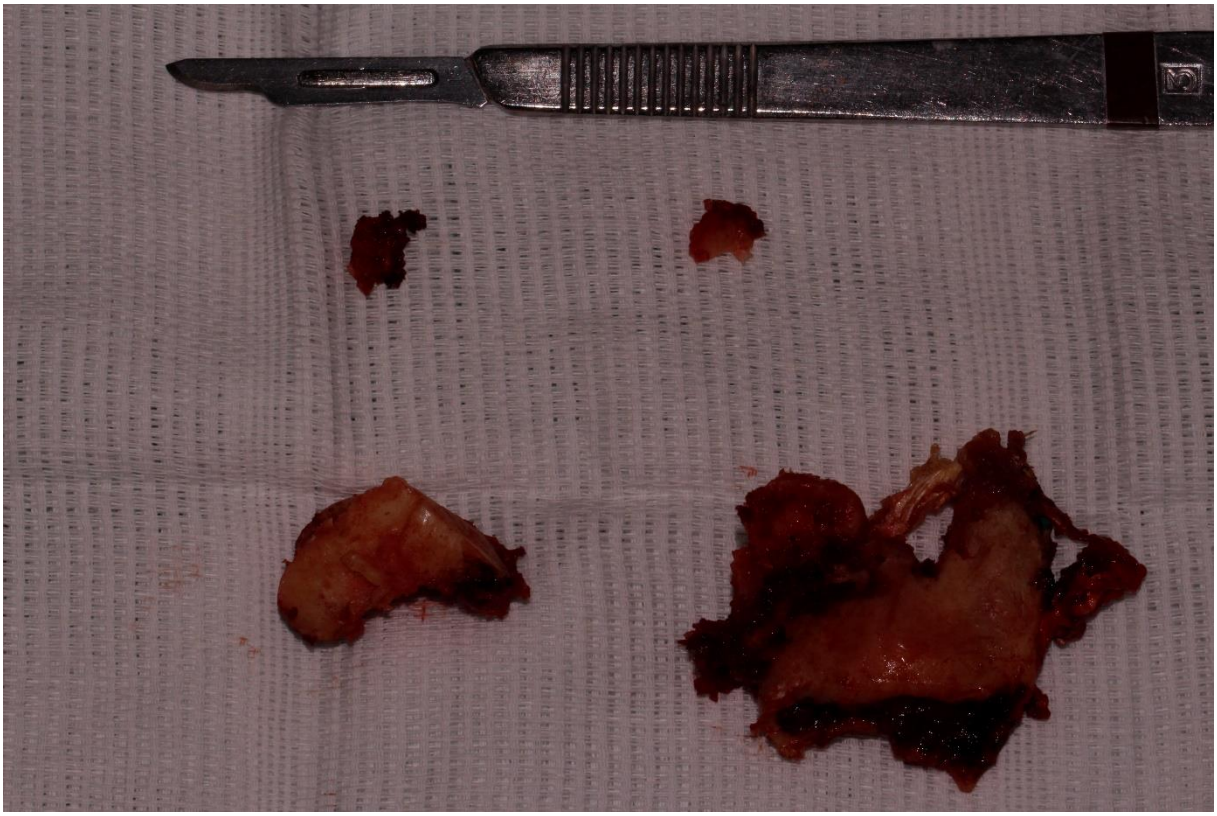

Pic. 18. Removed ankylotic fragments of right TMJ.

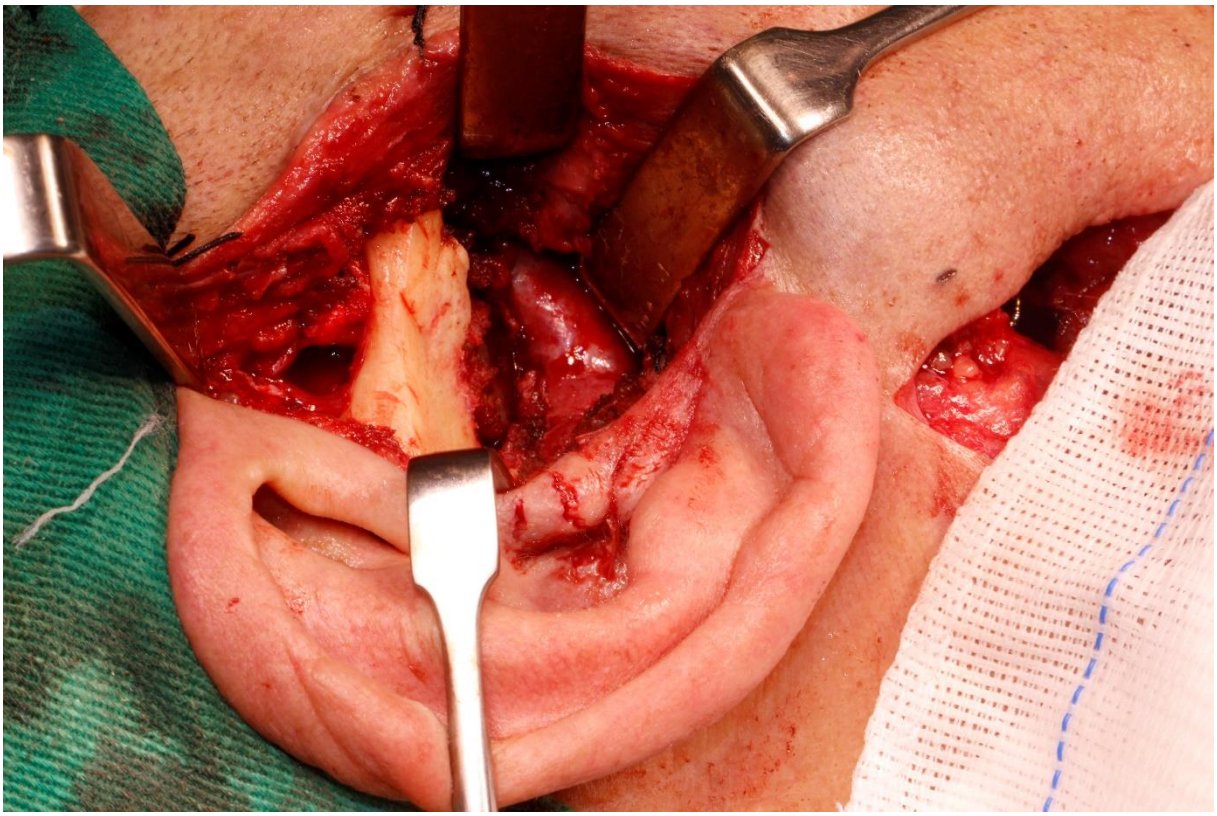

Pic 19. Pososteotomy view of the right TMJ

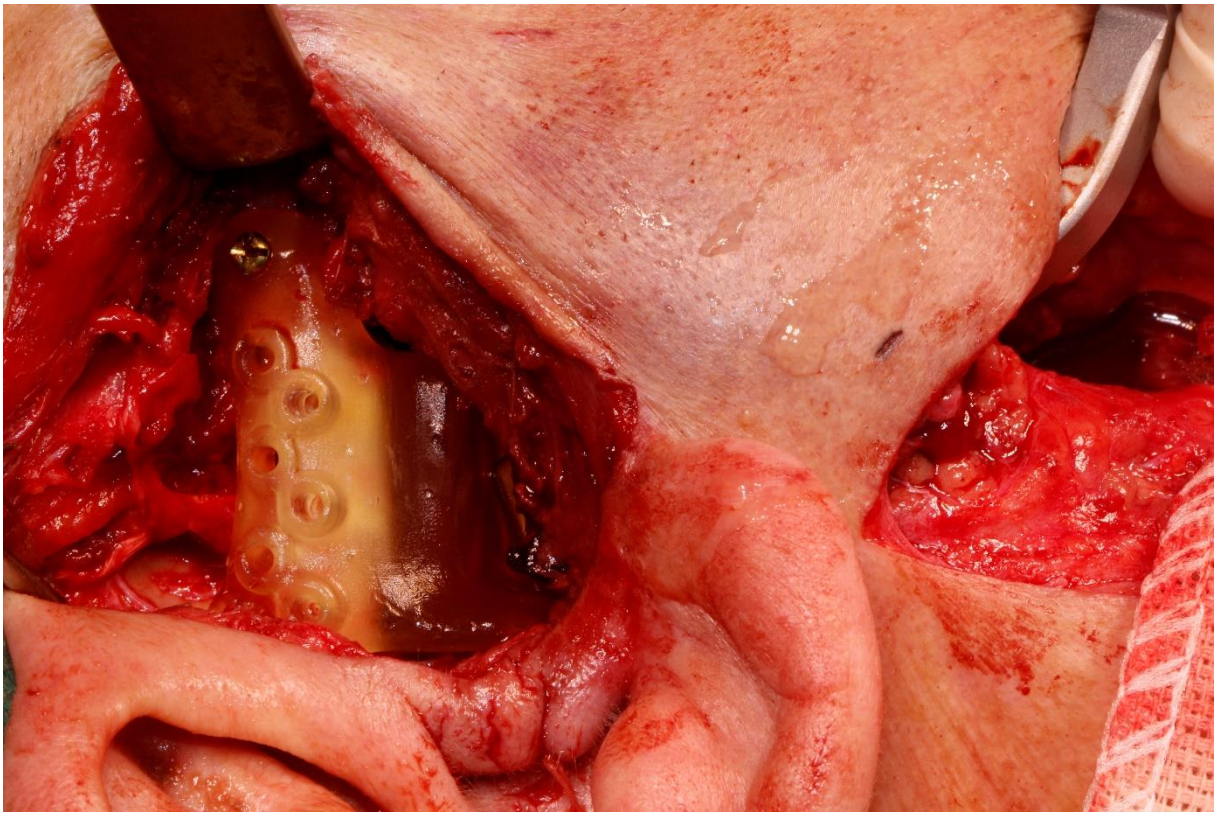

Pic. 20. Drilling guide of the articular fossa(right TMJ)

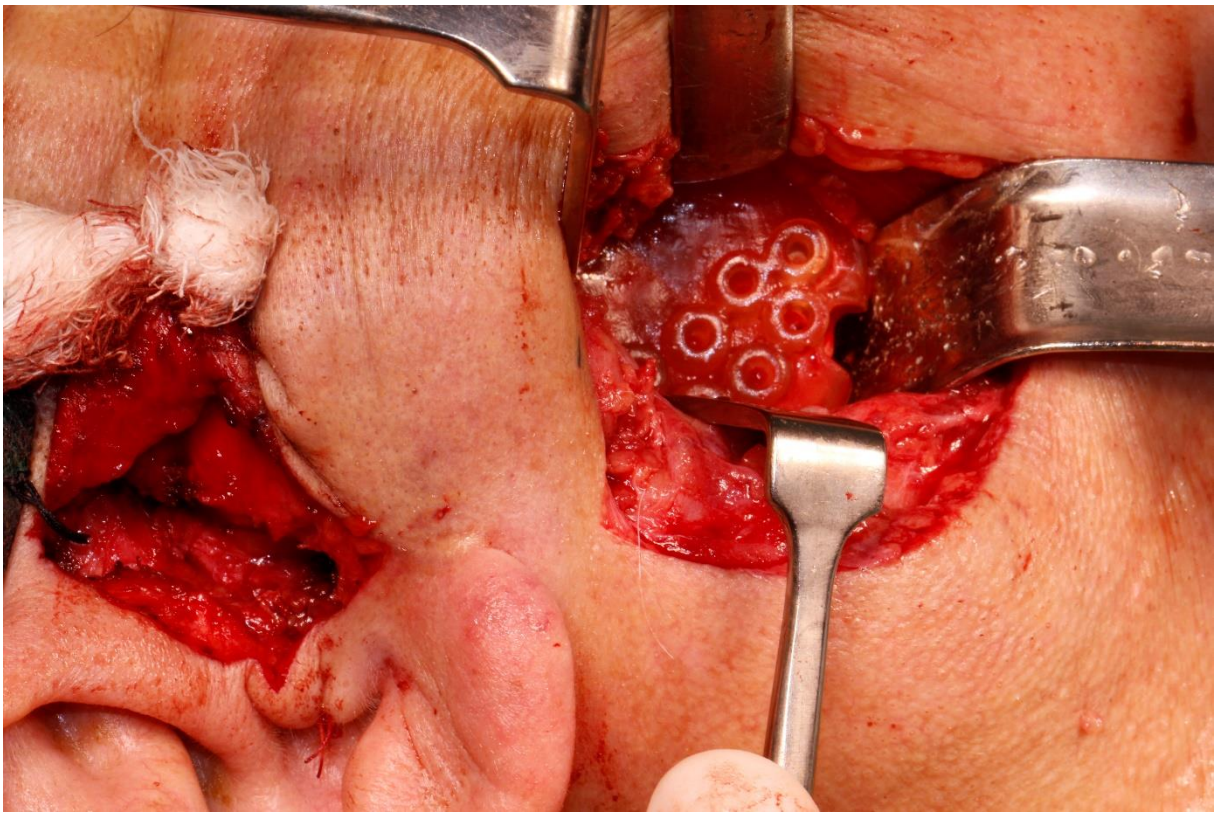

Pic. 21. Correctly fitted osteotomy and drilling guide of the mandibular ramus. (right)

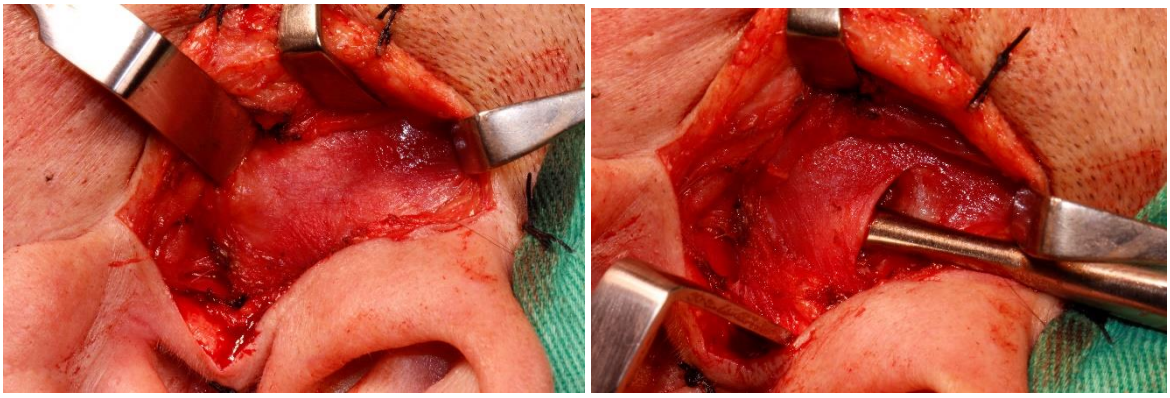

Pic. 22 and 23. Preauricular access to the ankylotic left TMJ

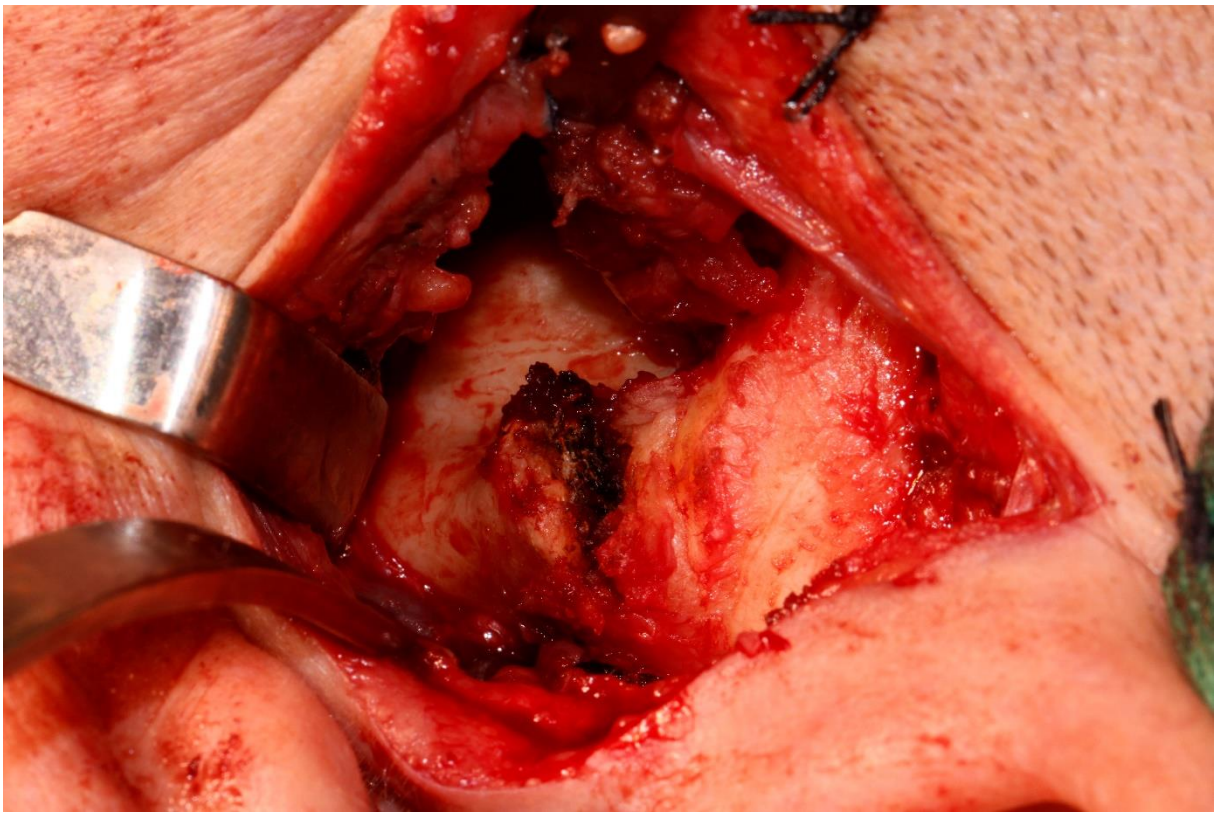

Pic. 24. Fibrous and partial bony fusion of the structures contained within the left TMJ

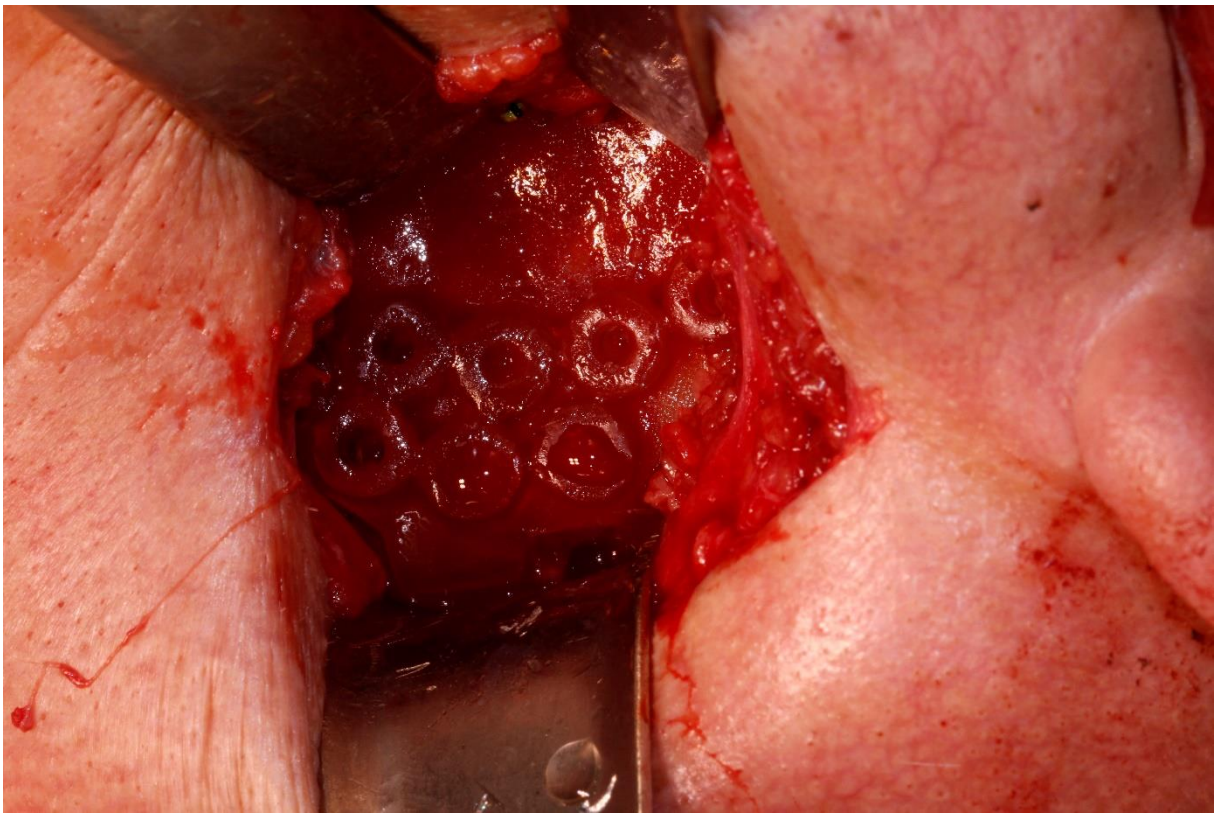

Pic. 25 Correctly fitted osteotomy and drilling guide of the mandibular ramus. (left)

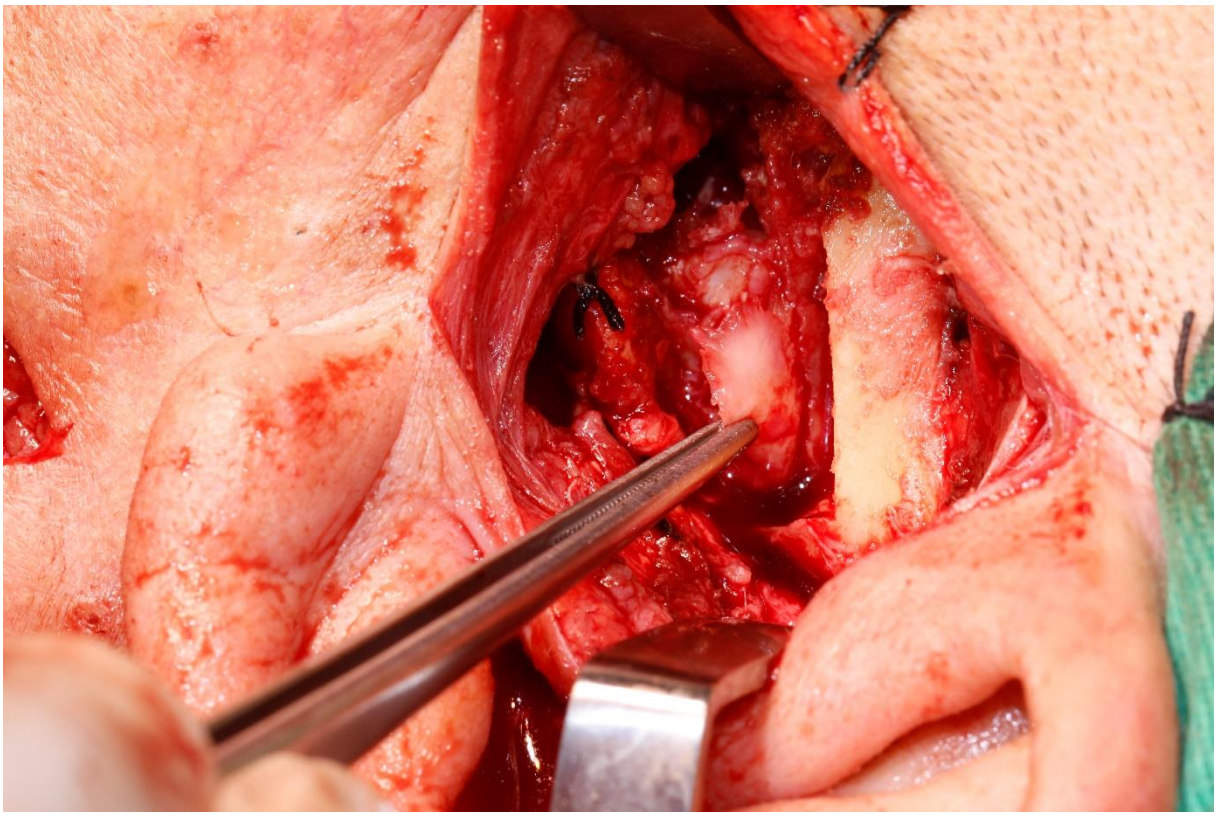

Pic. 26. View of the left TMJ after ostectomy with partially preserved joint disc

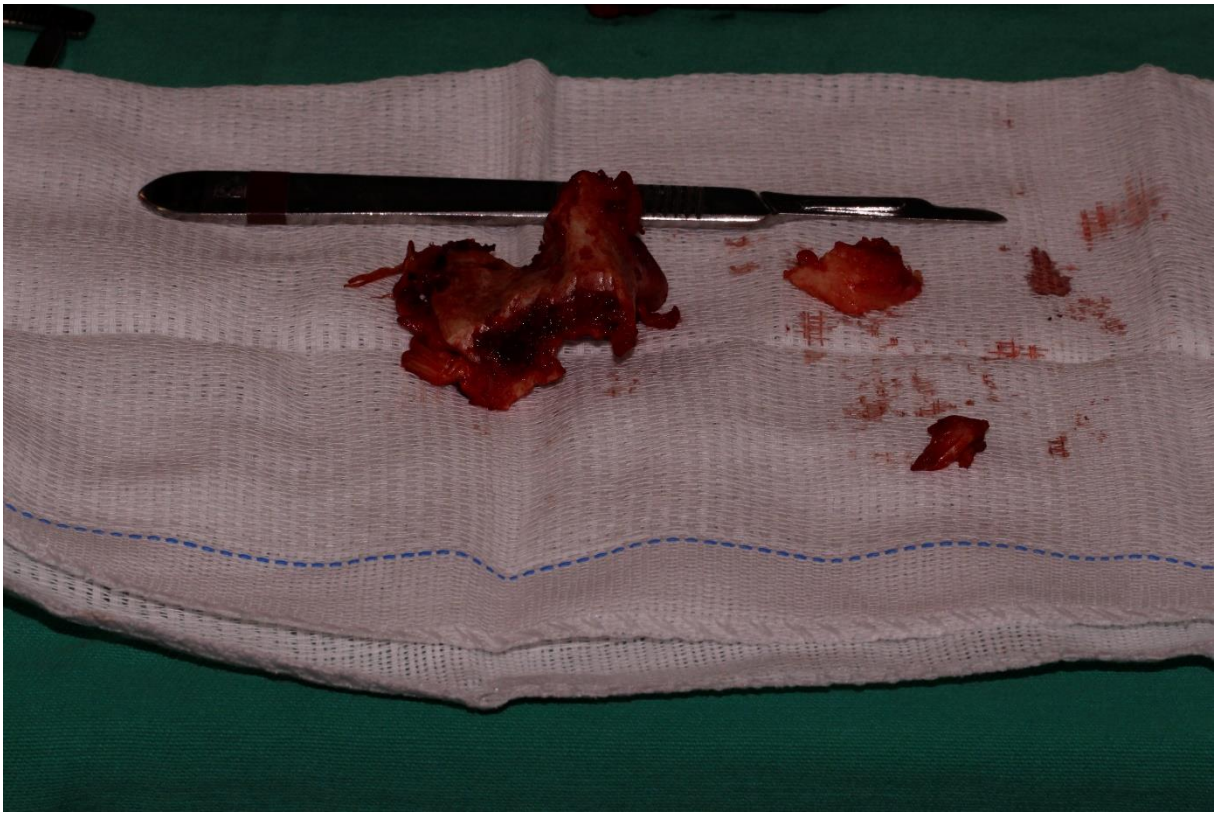

27. View of ankylotically altered fragment of the TMJ on the left side.

Pic 28. Intraoperative jaw opening measurement

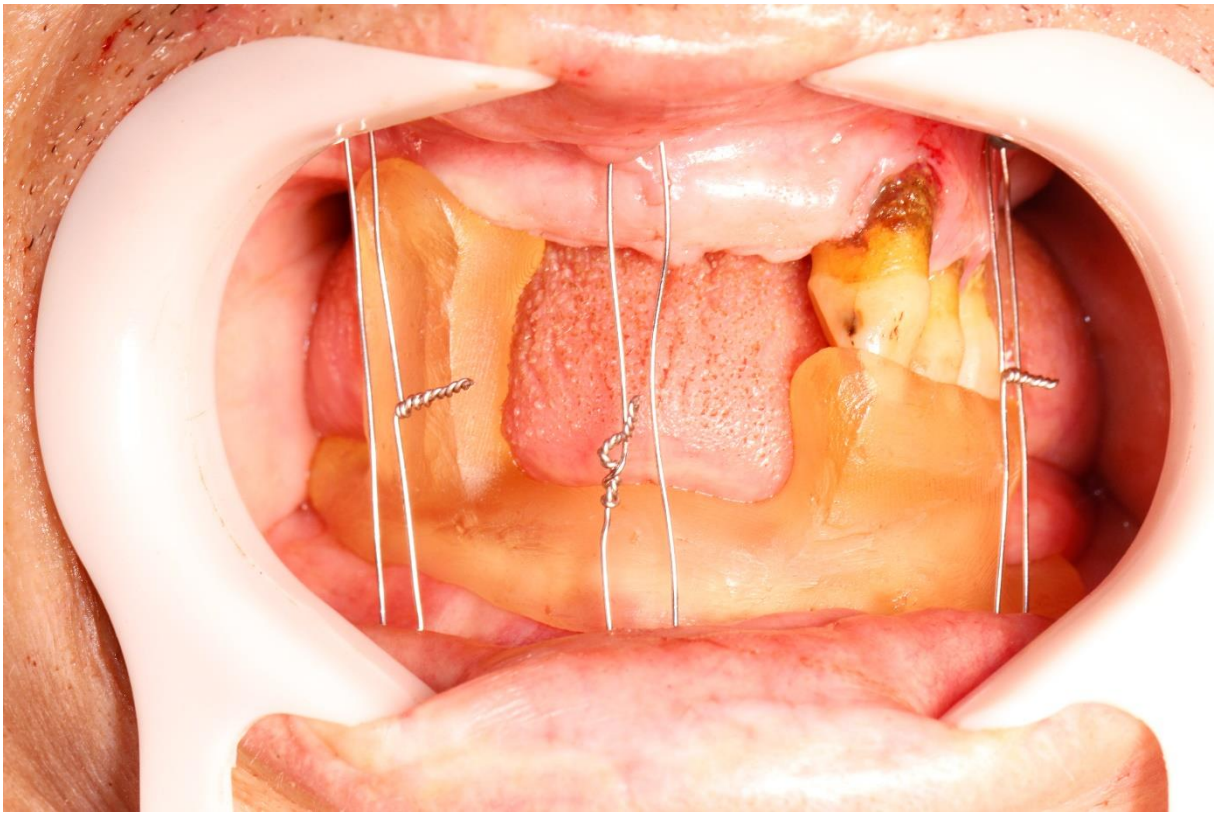

Pic. 30 Intraoral operating splints

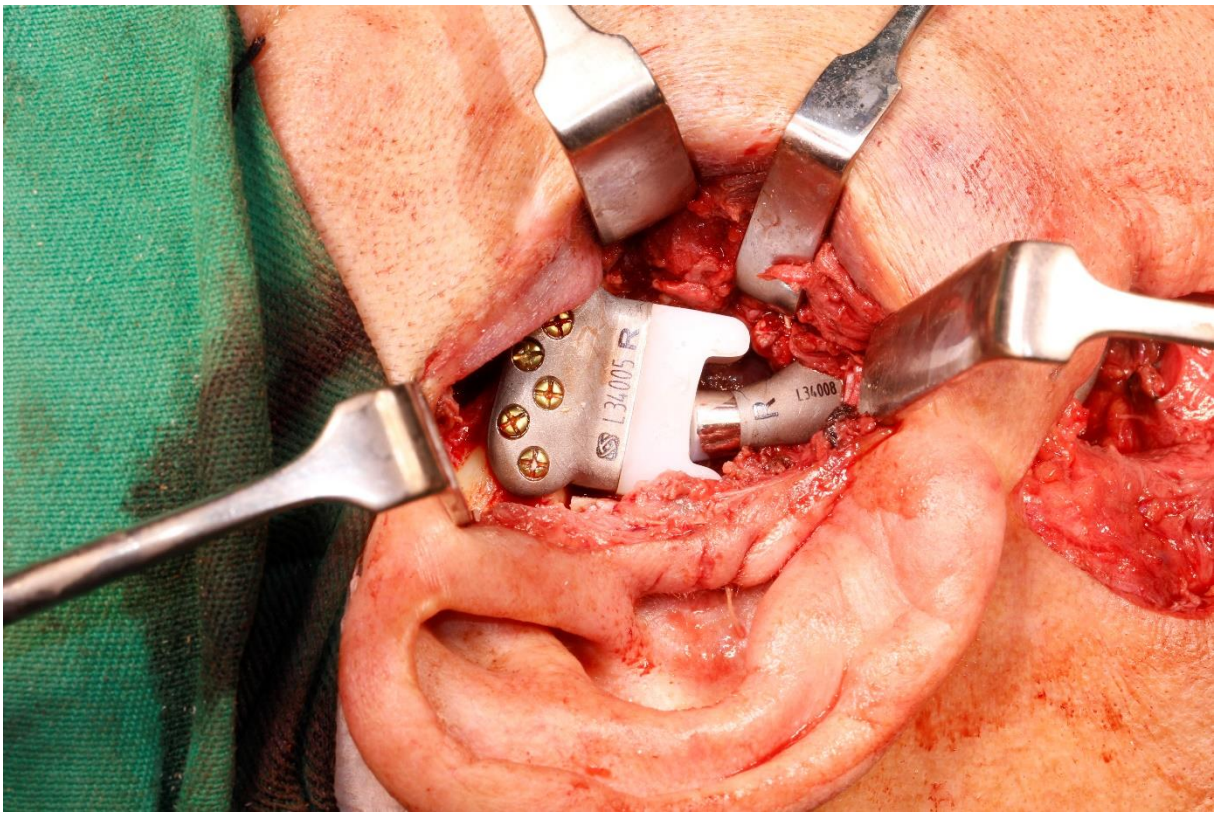

Pic 31. Right side articular fossa prosthesis fitting predrilled holes

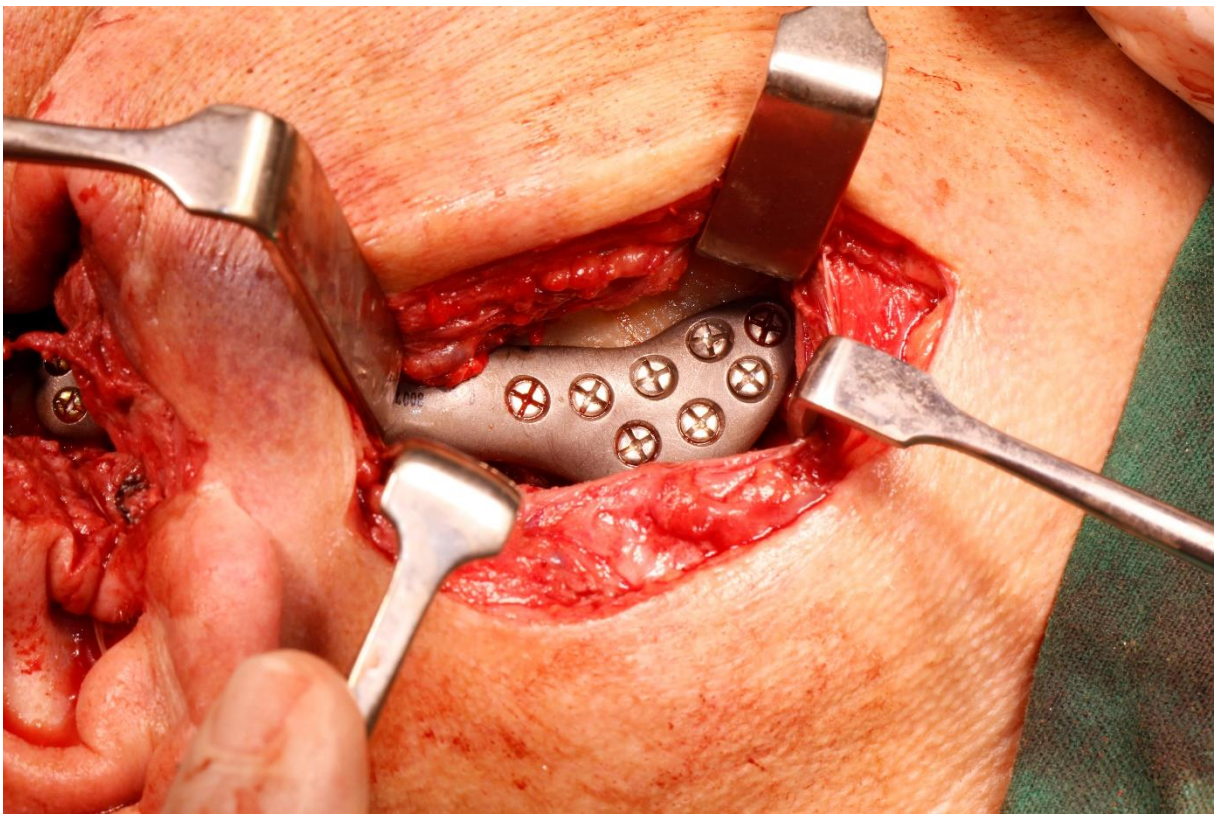

Pic. 32 Prosthesis fitting predrilled holes (right ramus of the mandible)

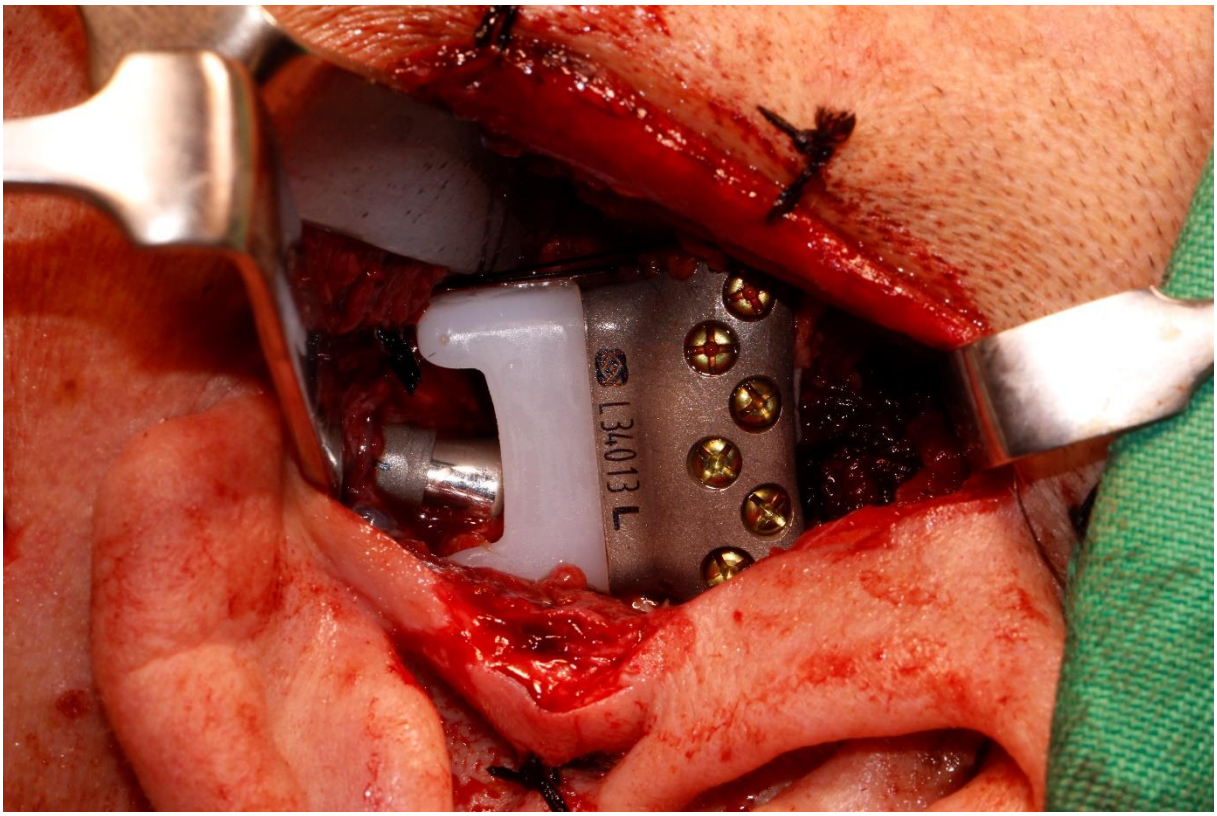

Pic. 33 Left side articular fossa prosthesis fitting predrilled holes

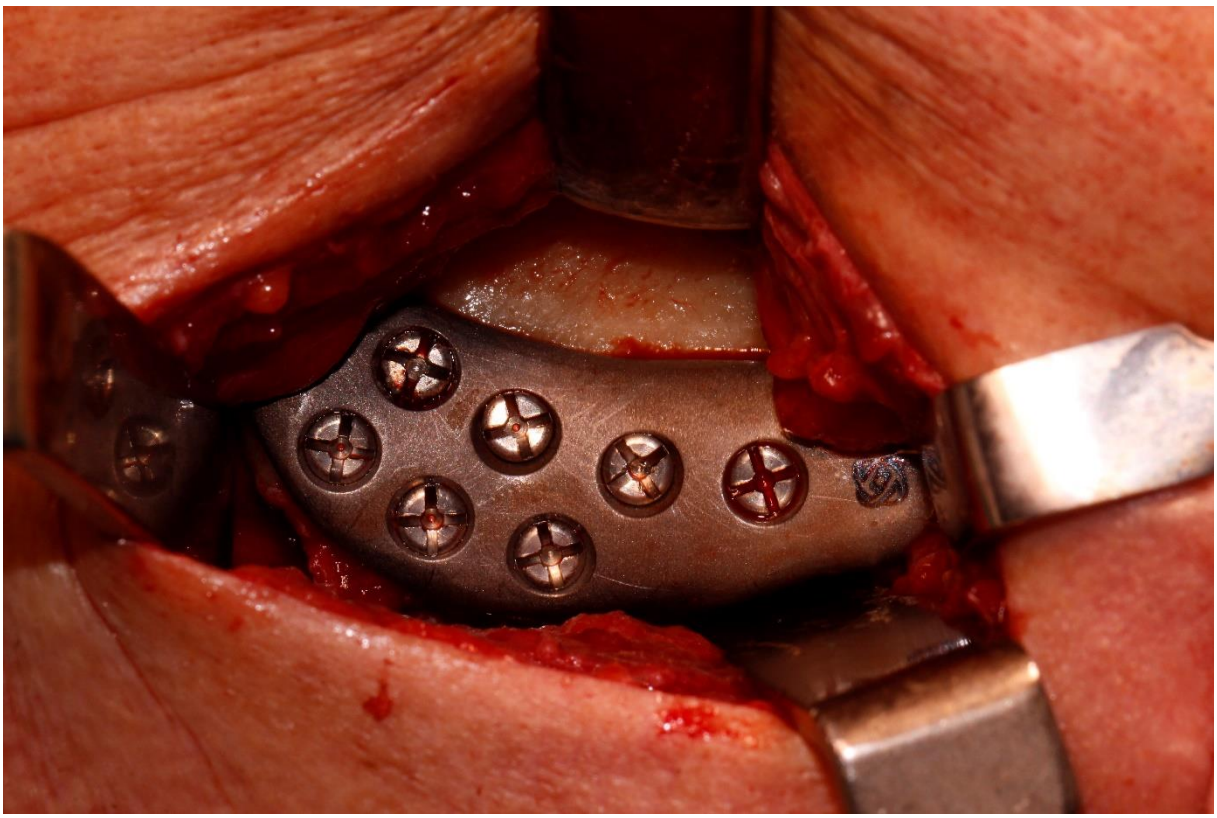

Pic 34. Prosthesis fitting predrilled holes (left ramus of the mandible)

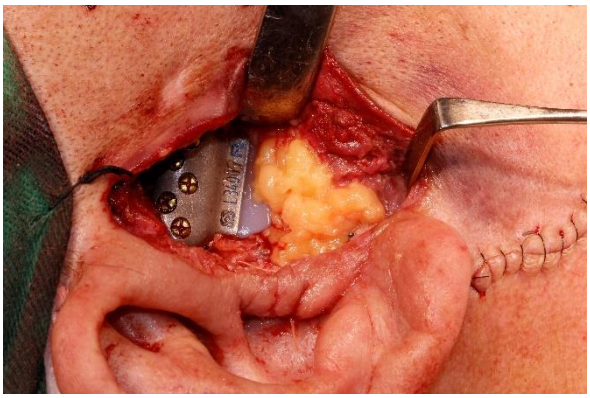
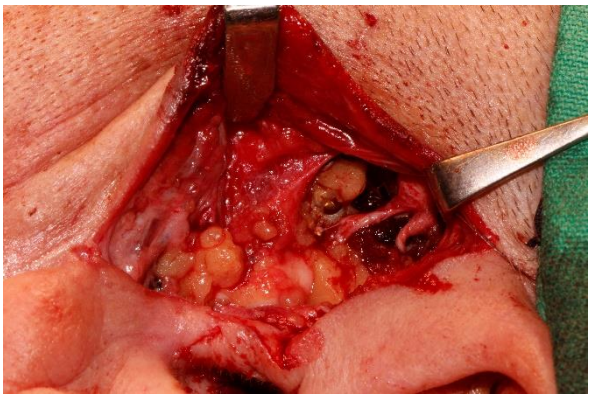

Pic 35 and 36. Fat graft packed around the articulation area of the devices of both temporomandibular joints.

Pic 37 and 38 Postoperative 3D reconstruction based on CT scan (lateral view)

Pic 39. Postoperative 3D reconstruction based on CT scan (frontal view)

Pic. 40,41,42 Postoperatory appearance of the patient

Pic 43. 15 days after the procedure (jaw opening measurement, 33mm), before initiating active physical therapy.

Pic. 44 Postoperative intraoral view

Discussion of Case

One-stage removal of temporomandibular joint ankylosis and prosthetic reconstruction is an extremely complicated maxillofacial procedure. It requires the surgeon to have excellent knowledge of the anatomy of the affected area and experienced manual skills. A beautiful theater of surgery in the hands of wonderful Brazilian surgeons that I had the opportunity to see enriched my perception of surgery. In the hands of experienced surgeons, even the difficult procedure looked easy. Worth mentioning is that surgery went well due to the perfect planning of the operation and operating guides and the effect was more predictable. I would like to express my gratitude for the advices given to me, and the time devoted to show me step by step what the procedure is from the inside out, starting with planning and ending with postoperative care and patient's follow-up visits.

Acknowledgement and References

The author would like to thank Prof Dr. Dr. Mario F. R. Gabrielli of The Division of Oral and Maxillofacial Surgery (Department of Diagnosis and Surgery) at Araraquara, São Paulo, based at the São Paulo State University (UNESP) for his great help, hospitality and great effort in teaching and showing me new surgical horizons. Many thanks to Professor Valfrido A. Pereira Filho in the Araraquara Dental School for his invaluable support and supervision.

1. Linhai He , Zhiyong Zhang, E Xiao, Yang He and Yi Zhang, Pathogenesis of traumatic temporomandibular joint ankylosis: a narrative review *Journal of International Medical Research 48(11) 1–11*

2. Vasconcelos BC, Bessa-Nogueira RV and Cypriano RV. Treatment of temporomanidibular joint ankylosis by gap arthroplasty. *Med Oral Patol Oral Cir Bucal 2006; 11: E66–E69.*
3. Yan YB, Zhang Y, Gan YH, et al. Surgical induction of TMJ bony ankylosis in growing sheep and the role of injury severity of the glenoid fossa on the development of bony ankylosis. *J Craniomaxillofac Surg 2013; 41: 476–486.*
4. R. F. Elgazzar, A. I. Abdelhady, K. A. Saad, M. A. Elshaal, M. M. Hussain, S. E. Abdelal, A. A. Sadakah: Treatment modalities of TMJ ankylosis: experience in Delta Nile, Egypt. *Int. J. Oral Maxillofac. Surg. 2010; 39: 333–342.*
5. Neeti Mittal , Manoj Goyal , Divesh Sardana , J.S. Dua, Outcomes of surgical management of TMJ ankylosis: A systematic review and meta-analysis, *Journal of Cranio-Maxillofacial Surgery Volume 47, Issue 7, July 2019, Pages 1120-1133*
6. El-Sheikh M, Medra A, Warda M: Bird face deformity secondary to bilateral temporomandibular joint ankylosis. *J Cranio-Maxillofac Surg 24: 96e103, 1996*
7. Engel MB: Condylar growth and mandibular deformities. *Angle Orthod 18(3): 132e134, 1948*
8. Abdelouahid Taleuan, Dounia Kamal, Lotfi Aouinti, Moahamed Nourdine Elalami Ankylose de l'articulation temporo-mandibulaire post-arthrosique-case report, *Pan African Medical Journal. 2019;32:151. doi:10.11604/pamj.2019.32.151.17779*
9. Wolford L, Movahed R, Teschke M, Fimmers R, Havard D, Schneiderman E, Temporomandibular Joint Ankylosis can be Successfully Treated with TMJ Concepts Patient-Fitted Total Joint Prosthesis and Autogenous Fat Grafts v12-21-15*, Journal of Oral and Maxillofacial Surgery (2016), doi: 10.1016/j.joms.2016.01.017.*
10. Xia, L., An, J., He, Y. *et al.* Association between the clinical features of and types of temporomandibular joint ankylosis based on a modified classification system. *Sci Rep 9, 10493 (2019). https://doi.org/10.1038/s41598-019-46519-8*
11. 5. Kaban LB, Bouchard C, Troulis MJ. A protocol for management of temporomandibular joint ankylosis in children. *J Oral Maxillofac Surg.* 2009;67(9):1966–1978. doi: 10.1016/j.joms.2009.03.071.
12. Larry J. Peterson *Peterson's Principles of Oral and Maxillofacial Surgery, Edition 1*
13. Andrew J. Sidebottom Alloplastic or autogenous reconstruction of the TMJ, *J Oral Biol Craniofac Res. 2013 Sep-Dec; 3(3): 135–139.*