Handmade external fixator for fifth metacarpal neck fractures. Case study and technique description.

Marcos Maiorano - Alberto Lazzerini

Galeazzi Orthopedic Institute, Milan, Italy.

Summary

Fifth metacarpal neck fractures are the most common metacarpal fractures. The best treatment modality for these fractures is a historical debate among closed reduction and immobilization, no reduction with early mobilization, or surgical reduction and stabilization using various surgical techniques. This is the case of a 40-year-old amateur tennis player with an acute closed fracture of the fifth metacarpal neck treated with our surgical technique using a handmade external fixator constructed from K-wires and polymethylmethacrylate. We believe that our handmade external fixator combines the advantages of a minimal invasion of the soft tissues and provides sufficient mechanical stability to allow an early mobility in a simple and cost effective way to treat a very frequent pathology.

Key words. Metacarpal fractures. Boxer's fracture. External fixation.

Introduction

Fractures of the metacarpal neck represent the most common type of metacarpal fracture, with fractures of the neck of the fifth metacarpal (Boxer's fracture) being the most common type (1)(2). They typically affect young and healthy men (3) leading to missed time

from work. Isolated metacarpal injuries can result in up to 3-6 weeks of missed time with non-operative management alone (4)(5).

The best modality of treatment of these fractures is an historic debate, but especially palmar angulation as a parameter for surgery indication, has been intensively debated (6). While many use an angulation threshold of 40° or even 60° still a maximal angulation of 30° has been the guideline in many recent studies (7)(8)(9).

Most of the consequences of not restoring the normal anatomic alignment of metacarpal fractures, however, are cosmetic (loss of the knuckle) and do not have functional problems (1). In some particular patients such as manual workers or gripping athletes, palmar protrusion of the metacarpal head can cause pain and discomfort, being candidates for the surgery.

Management options for isolated, closed, fifth metacarpal neck fractures include closed reduction and immobilization, no reduction with early mobilization, or surgical reduction and stabilization using various operative techniques (10).

In this case we describe an operative technique used in patients treated with an external fixator constructed from K-wires and polymethylmethacrylate.

Case presentation

This is the case of a 40 years male amateur tennis player with a closed, acute, fifth metacarpal neck fracture on his dominant hand. After an extensive explanation of the pathology and the diverse options of treatment, the surgery management was decided with the patient.

Technique description

The surgery is performed under plexus anesthesia with the patient in supine position and the arm over a hand table.

The first step consists of the closed fracture reduction with the Jahss maneuver. When good fracture reduction is confirmed under image intensifier (Figure 1), fracture fixation is performed.

This starts with the placement of a smooth 1.5 mm K-wire on the fifth metacarpal head to the fourth metacarpal neck (Figure 2). After that, a second K-wire is placed proximally to the fracture line in a parallel disposition to the first (Figure 3).

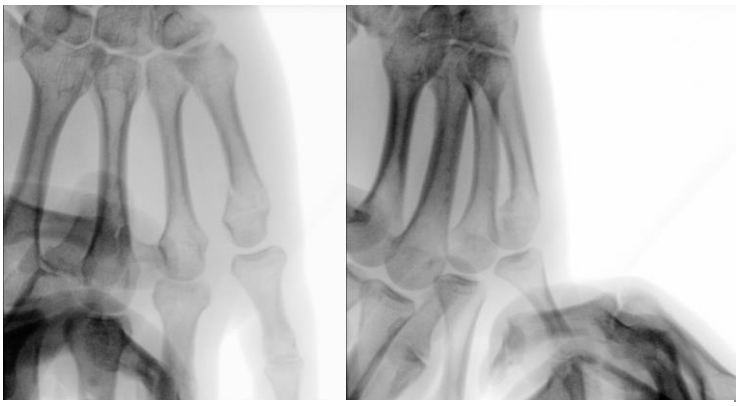

Figure 1

Once this fixation is achieved, we bend the K-wires in such a way that they form a square (Figure 4) and then join them using orthopedic cement forming a closed structure. Finally, the external fixator is achieved (Figure 5) and is draped with a sterile bandage.

Figure 2

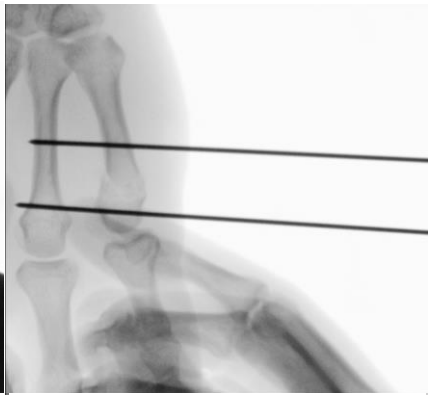

Figure 3

The patient stays in the recovery room about two or three hours to receive postoperative medications such as analgesics and antibiotics.

Postoperatively, the patient can move the wrist and fingers freely, with weight lifting restricted. The duration of treatment depends mainly on the presence of fracture union but usually does not exceed six weeks.

Discussion

The surgical treatment of the fifth metacarpal neck fractures includes alternatives ranging from closed reduction and percutaneous fixation with K-wires to open reduction and internal fixation with plate and screws.

Plate fixation has been shown to provide sufficient stability to allow early mobility. This represents an obvious advantage for those patients who cannot tolerate a prolonged period of immobilization or those who are unable to protect exposed pins. However, many

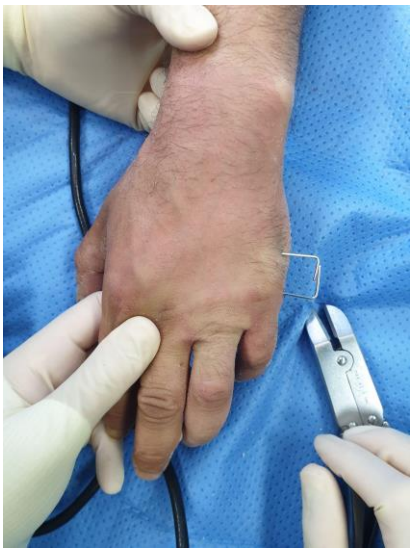

Figure 4

Figure 5

complications have been reported, including metacarpal head avascular necrosis, nonunion, severe tendon irritation, and high rate of stiffness due to excessive soft tissue damage (11).

That is why the use of K-wires has become widely accepted and multiple alternatives have been proposed, such as anterograde,

retrograde, crossed and transverse pinning among others. However, the use of pins is not without complications. A cadaveric work has been shown that each of these options puts different nerve and tendon structures at risk that the surgeon must be aware of, in order to anticipate possible complications and advise patients accordingly. (12). In addition to this, the stability provided by the K-wires is not enough and they must be accompanied by some type of immobilization.

The use of K-wires and acrylic resin for rigid fixation of the bones of the hand dates back to 1974. At that time the indications were the fixation of corrective osteotomies and arthrodesis (13). Subsequently, other works have described the application of external fixators using these same materials in comminuted fractures of the phalanges and metacarpals or open fractures, with associated injuries or skin defects (14). However, the use of external fixation for the treatment of acute and isolated metacarpal fractures has not been reported.

The placement of the K-wires in the fourth metacarpal provides stability to the system as the fracture is suspended between two rigid and stable structures, the cement and the fourth metacarpal itself. It's why we believe that our handmade external fixator combines the advantages of a minimal invasion of the soft tissues and provides

sufficient mechanical stability to allow an early mobility, in a simple and cost effective way to treat a very frequent pathology.

As a future prospect this external fixator could be biomechanically tested and then clinically evaluated to determine the accuracy of our assumptions.

Acknowledgement

To Dr. Alberto Lazzerini for sharing his knowledge with me and teaching me his technique.

References

1. Neumeister, Michael W., et al. "Non-Surgical Management of Metacarpal Fractures." *Clinics in Plastic Surgery*, vol. 41, no. 3, 2014, pp. 451–461., https://doi.org/10.1016/j.cps.2014.03.008.
2. Hunter JM, Cowen NJ. Fifth metacarpal fractures in a compensation clinic population. A report on one hundred and thirty-three cases. J Bone Joint Surg Am. 1970 Sep;52(6):1159-65.
3. Nakashian MN, Pointer L, Owens BD, Wolf JM. Incidence of metacarpal fractures in the US population. Hand (N Y). 2012 Dec;7(4):426-30. doi: 10.1007/s11552-012-9442-0.
4. Statius Muller MG, Poolman RW, van Hoogstraten MJ, Steller EP. Immediate mobilization gives good results in boxer's fractures with volar angulation up to 70 degrees: a prospective randomized trial comparing immediate mobilization with cast immobilization. Arch Orthop Trauma Surg. 2003 Dec;123(10):534-7. doi: 10.1007/s00402-003-0580-2. Epub 2003 Aug 28.
5. van Aaken J, Kämpfen S, Berli M, Fritschy D, Della Santa D, Fusetti C. Outcome of boxer's fractures treated by a soft wrap and buddy taping: a prospective study. Hand (N Y). 2007 Dec;2(4):212-7. doi: 10.1007/s11552-007-9054-2. Epub 2007 Jul 3.

6. Boeckstyns MEH. Challenging the dogma: severely angulated neck fractures of the fifth metacarpal must be treated surgically. J Hand Surg Eur Vol. 2021 Jan;46(1):30-36. doi: 10.1177/1753193420968040. Epub 2020 Nov 1.
7. Galal S, Safwat W. Transverse pinning versus intramedullary pinning in fifth metacarpal's neck fractures: A randomized controlled study with patient-reported outcome. J Clin Orthop Trauma. 2017 Oct-Dec;8(4):339-343. doi: 10.1016/j.jcot.2017.05.015. Epub 2017 Jun 3.
8. Amsallem L, Pierrart J, Bihel T, Sekri J, Lafosse T, Masmejean E, Delgrande D. Simplified internal fixation of fifth metacarpal neck fractures. Orthop Traumatol Surg Res. 2018 Apr;104(2):257-260. doi: 10.1016/j.otsr.2017.12.010. Epub 2018 Feb 2.
9. Surke C, Meier R, Haug L, Vögelin E. Osteosynthesis of fifth metacarpal neck fractures with a photodynamic polymer bone stabilization system. J Hand Surg Eur Vol. 2020 Feb;45(2):119-125. doi: 10.1177/1753193419880775. Epub 2019 Oct 22.
10. France TJ, Leversedge FJ, Lauder A. Clinical Outcomes of Severely Angulated Fifth Metacarpal Neck Fractures Treated Nonsurgically. Hand (N Y). 2022 Jan 7:15589447211063238. doi: 10.1177/15589447211063238. Epub ahead of print.
11. Kollitz KM, Hammert WC, Vedder NB, Huang JI. Metacarpal fractures: treatment and complications. Hand (N Y). 2014 Mar;9(1):16-23. doi: 10.1007/s11552-013-9562-1.
12. Akinleye SD, Garofolo-Gonzalez G, Culbertson MD, Choueka J. Iatrogenic Injuries in Percutaneous Pinning Techniques for Fifth Metacarpal Neck Fractures. Hand (N Y). 2019 May;14(3):386-392. doi: 10.1177/1558944717731858. Epub 2017 Sep 21.
13. Crockett DJ. Rigid fixation of bones of the hand using K wires bonded with acrylic resin. Hand. 1974 Feb;6(1):106-7. doi: 10.1016/0072-968x(74)90022-9.
14. Walter FL, Papandrea RF. A mini external fixator for hand and finger fractures constructed from readily available materials. Tech Hand Up Extrem Surg. 2011 Dec;15(4):215-8. doi: 10.1097/BTH.0b013e318217615f.