IBRA Case Study

Guyon's canal syndrome – An unusual Cause

Garcia Bensi, A MD(1), Lopez – Osornio, P MD (2), Casañas, J MD (3)

Centro Medico Teknon, Barcelona

Keywords:

Guyon's canal – Cubital syndrome – Kinking – Ulnar Syndrome – Ulnar Surgery

Summary:

This case report is an unusual cause of the guyon's canal that was presented during my stay in the Teknon Clinic in Barcelona. This patient went to the medical consultation with weakness and grip loss of his left hand and the fall of objects during his daylife. His strength was altered without traumas. We made specific studies of his hand, during the MRI a double arterial kinking was noticed so we realized that was an unusual cause of compression of the ulnar motor branch in the guyon's channel that was confirmed with EMG and surgery was indicated to recover his strength.

In surgery time, that kinking was visualized that was the cause of his illness, during this time, the ulnar motor branch was released with very cautelous careful of the ischemia. In the immediately postop a dorsal splint was made to protect the surgery, and in a 3 weeks we can check the new results of his grip that was increased in a 50% approx. We are waiting until the final outcome to the have the best result of the surgery.

(1) Upper limb surgeon. CLIMBA (Clinica de la Mano Buenos Aires) Buenos Aires Argentina, Viamonte 1632, Buenos Aires Argentina.
(2) Upper Limb Surgery Traumaunit Centro Medico Teknon, Barcelona Spain
(3) Director of Traumaunit and peripherical nerve Centro Medico Teknon, Barcelona Spain

Email Address: garcia@climba.com.ar

Introduction:

Ulnar nerve compression neuropathy caused by direct compression in Guyon's canal also known as handlebar palsy (seen in cyclists).
Anatomy and Zones:
Guyon's canal is approximately 4 cm long, begins at the proximal extent of the transverse carpal ligament and ends at the aponeurotic arch of the hypothenar muscles Contents. Ulnar nerve bifurcates into the superficial sensory and deep motor branches.

Boundaries of Guyon's canal			
Floor	Transverse carpal ligament, hypothenar muscles		
Roof	Volar carpal ligament		
Ulnar border	Pisiform and pisohamate ligament, abductor digiti minimi muscle belly		
Radial border	Hook of hamate		
Zones of Guyon's canal			
	Location	*Common Causes of Compression*	*Symptoms*
Zone 1	Proximal to bifurcation of the nerve	Ganglia and hook of hamate fractures	Mixed motor and sensory
Zone 2	Surrounds deep motor branch	Ganglia and hook of hamate fractures	Motor only
Zone 3	Surrounds superficial sensory branch	Ulnar artery thrombosis or aneurysm	Sensory only

Deep branch of the ulnar nerve, innervates all of the interosseous muscles and the 3rd and 4th lumbricals. Innervates the hypothenar muscles, the adductor pollicis, and the medial head (deep) of the flexor pollicis brevis (FPB).
The most common compression causes ganglion cyst (80% of nontraumatic causes),lipoma, repetitive trauma, ulnar artery thrombosis or aneurysm, hook of hamate fracture or nonunion, pisiform dislocation, inflammatory arthritis, fibrous band, muscle or bony anomaly, congenital bands, palmaris brevis hypertrophy, idiopathic.

Presentation varies based on location of compression within Guyon's canal and may be pure motor, pure sensory mixed motor and sensory.
Symptoms:
Pain and paresthesia in ulnar 1-1/2 digits, weakness to intrinsics, ring and small finger digital flexion or thumb adduction, clawing of ring and little fingers
caused from loss of intrinsics flexing the MCPs and extending the IP joints
Allen test, it must be made and helps diagnose ulnar artery thrombosis the same as neurovascular exam that ulnar nerve palsy results in paralysis of the intrinsic muscles (adductor pollicis, deep head FPB, interossei, and lumbricals 4 and 5), weakened grasp from loss of MP joint flexion power, weak pinch from loss of thumb adduction (as much as 70% of pinch strength is lost).
Froment sign: IP flexion compensating for loss of thumb adduction when attempting to hold a piece of paper, loss of MCP flexion and adduction by adductor pollicis (ulnar n.) compensatory IP hyperflexion by FPL (AIN).
Jeane's sign: a compensatory thumb MCP hyperextension and thumb adduction by EPL (radial n.) compensates for loss of IP extension and thumb adduction by adductor pollicis (ulna n.).
Wartenberg sign: abduction posturing of the little finger.
Imagining very important to diagnose the cause of the compression, like Radiographs, CT scan, MRI, Doppler US.
NCS and EMG very helpful in establishing diagnosis and prognosis , threshold for diagnosis, conduction velocity <50 m/sec across elbow and low amplitudes of sensory nerve action potentials and compound muscle action potentials.

The importance of this topic was that is an unusual or not a common cause of compression, that was only selective to the ulnar motor branch instead of has a mixed ulnar nerve injury. The difficult main topic was to understand why he has weakness without having traumas or having a sport ,for example, like cycling or others. The only reason we strongly believe that there was an external cause of compression, been in the top list the cyst in this area. Usage and understand MRI images let us realize that there was a kinking in the guyon's canal.

Differential diagnosis was made once the MRI images were obtained and we clearly define the main compression of this patient with the arterial kinking compression, and realize the presentation of the unique ulnar motor branch compression.

The usage of microscope was an excellent resource to manage nerve injuries with extremally precision, and EMG intraoperatory combined the best way for the excellent outcome.

I participate in the diagnosis and full surgery time including the microscope time, I know that I could not see the full recovery of this injury, because it will take few months until the complete healing. Is notable the manage of the illness in this trauma and nerve peripherical clinic and the possibility to do specifics studies in a short period of time.

Case Presentation:

This case is a male of 53 years old with no personal history that present wrist and 4th and 5th weakness and low agility and function of his left hand and an evolution of 3 month ago, without traumas, falls nor another cause (Medical consultation was 22/03/2021). Also this patient has flexion of 4th and 5th proximal interphalangeal joints, a mild preacher's hand was noticed. He can't hold objects for a short period of time

Clinical founding's are 1est finger Abductor (abductor pollicis longus) and interosseous mussels with Abductor Minimis (ADM) intact, Duchenne's sing and Froment's sign +. EMG confirmed an exclusive motor ulnar nerve branch distally denervation, and ADM without any founding nor alterations.

MR Scan (24/03/21) inform us the triple arterial kinking with double ulnar modification and a simple kinking in the radial artery. Fig 1.

Surgery indication was made with nerve stimulator (ENG recording intraoperatory).



Fig. 1. A) MRI coronal plane left hand with kinking of the radial artery (right) and ulnar artery (left).

B) Kinking type III ulnar artery

C) Kinking type II ulnar artery, pisiform bone (Blue)

Management and Outcome:

The operation is performed under regional anesthesia (axillary block) with a pneumatic tourniquet placed at the upper arm close to the armpit. The patient is placed supine with the affected arm on a hand table.

Ulnar approach was made. The skin incision borders the radial side of the flexor carpi ulnaris (FCU) tendon, diagonally crosses the proximal wrist crease, then follows longitudinally in the palm in line with the ring finger. The fascia on the radial side of the FCU is opened, and the ulnar nerve and artery are identified just below the radial edge of the FCU. The nerve is traced from proximal to distal. The roof of Guyon's canal, the volar carpal ligament, is divided in line with the skin incision. The nerve and artery are carefully mobilized and explored. (Fig 2).

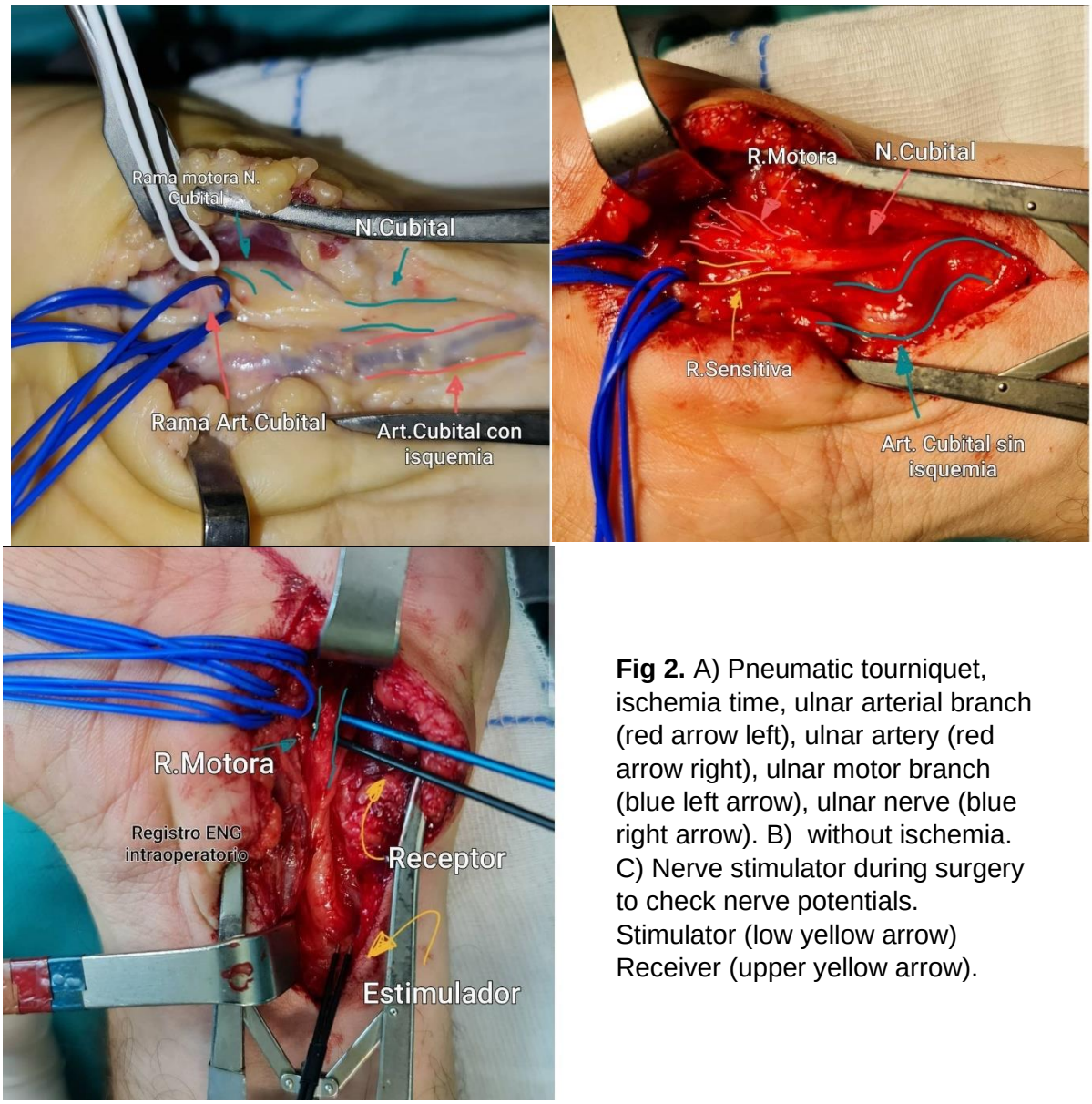

Fig 2. A) Pneumatic tourniquet, ischemia time, ulnar arterial branch (red arrow left), ulnar artery (red arrow right), ulnar motor branch (blue left arrow), ulnar nerve (blue right arrow). B) without ischemia. C) Nerve stimulator during surgery to check nerve potentials. Stimulator (low yellow arrow) Receiver (upper yellow arrow).

Intraoperatory ENG, a low voltage potential was noticed in the ulnar motor branch for intrinsics mussels, with the exception of the ADM that was intact. Notice that the compression is distal to the exit of the ulnar motor branch nearly Zone 1.

Neurolysis was made with the use of microscope and the communicating of the distal ulnar artery was ligated. This communicating artery was compressing the motor ulnar branch. The difference between the using ischemia or not is an important reason to believe that when the pneumatic tourniquet was released, the arterial morphology was the cause of the compression, instead of only check the nerve with ischemia. The using of ENG stimulator guide us to understand the injury, and the most important thing, where the neurolysis must be performed.

Finally we made subcutaneous suture and skin sutures, completing with a dorsal split.

The stay of this patient at the clinic were 2 days, because in early hours there was a complication of mild bleeding that was noticed for the nurses that inform us. In this condition we have to go to surgery to check the problem, and there was a little epineural artery. Once this was coagulated, no complications were noticed.

The patient was looked forward for 3 weeks, one per week, in the second one, all stiches were removed but he has a hand therapy in the 3 day pop. At the 3erd week, the patient notice a good result of the surgery telling us he can hold objects for a long period of time without any complication.

Discussion:

My opinion of this case is that the importance of the treatment and how to manage it, specially beeing in a high advance center that has the possibility to do the specific studies really quickly and have nerve stimulator plus the microscope to stay focused on the nerve injuries. I learned how to make diagnosis of different causes of nerve injuries and beside this, specially how to manage nerves, not only at surgery. The really excellent outcome starts at the consulting room, making differential diagnosis using EMGs, MRI, for example, but they made the importance of the clinic semiology and specific tests we made to the patient, understanding what to look forward into the specific studies.

Sometimes we are focused in some causes (common ones) and when we have something different we start to understand that the patient is unique, so his illness is unique too, for that reason we have to evaluate the patient as a one single piece.

During surgery to understand that some anatomical variants really exist, sometimes without complications, sometimes making some nerve or arterial compression. The usage of microscope it takes a lot of hours to know how manage it well, it is practice but with really good surgeons.

Acknowledgement and References:

- Guyon’s Canal Revised: an anatomic study of the carpal ulnar neurovascular space. *J Hand Surg Am. 1996 Sep*

- Ulnar Tunnel Syndrome, Radial Tunnel Syndrome, Anterior Interosseous Nerve Syndrome and Pronator Syndrome. *Instr Course Lecture 2017 Feb.*
- MR anatomy and pathology of the ulnar nerve involving the cubital tunnel and Guyon's canal. *Clin Immagining 2016 Mar-Apr.*
- The deep (motor) branch of the ulnar nerve: a detailed examination of its course and the clinical significance of its damage. *J Hand Surg Eur Vol 2009 Feb.*
- Nerve Surgery. *Susan E. Mackinnon. Chap 10 page 251.*