Modified intra-oral quadrangular Le Fort II combined with classic Le Fort I Osteotomy (double-step maxillo-malar osteotomy) for correction of midface deficiency: a case report.

Otacílio Luiz Chagas-Júnior[1,2], Guido Sigron[2], and Oliver Ploder[2,3]

1 – IBRA Scholar

2 – Department of Oral and Maxillofacial Surgery, Landeskrankenhaus Feldkirch, Austria

3 – Chairman

Keywords: Class III; Le Fort II Osteotomy; Le Fort I Osteotomy; Orthognathic Surgery; Malar Deficiency; Maxillary Deficiency.

Summary

Class III patients often present maxillary and midface antero-posterior deficiency despite the appearance of mandibular prognathism. Several techniques had been described in the literature to treat this problem. In this case report with a midface deficiency associated to Class III Angle occlusion treated by means of double-step maxillary Le Fort I and II osteotomy and BSSO is presented.

Introduction

Various approaches have been used to treat both midface and maxillary deficiency, including high Le Fort I osteotomy, Le Fort I osteotomy associated to infraorbital augmentation, extra-oral Le Fort II or III osteotomies, and modified Le Fort III.[1-8] Specifically, the intraoral quadrangular Le Fort II (IQLFIIO) or maxillo-malar osteotomy was first described by Keller and Sather (1987)[1] and is indicated for patients with hypoplasia with flattening of the zygomatic buttresses, paranasal and suborbital areas, but with normal projection of the nose.[4]

Some modifications have been proposed in the literature.[2-5,7] Klug and Cede (2017) had proposed the use of angulated piezosurgical instruments for inferior orbital rim osteotomy thus emphasizing the avoidance of the use of chisels in the orbital region, and the osteosynthesis only laterally at the zygomatic buttress with 2 L-shaped miniplates is sufficient for stable fixation.[7]

Complications related to this approach are infraorbital nerve damage, herniation of periorbital tissue in the maxillary sinus and fracture of the thin anterior wall of the maxillary sinus during mobilization of the maxillo-malar complex.[4] This approach is contraindicated in those cases with vertical hyperplasia greater than 4-5 mm, and in those cases with a 'gummy' smile or skeletal open bite, which requires a clockwise rotation of the maxillary occlusal plane. Moreover, this procedure is not indicated in dentofacial asymmetries where the upper interincisive centre line is deviated more than 2 mm, or in cases where horizontal correction of the occlusal plane is needed. In these situations, a high Le Fort I osteotomy with interpositional bone grafts

or a combination with classic Le Fort I osteotomy seems to be more indicated.[3-5]

Some authors had described the combinated osteotomies to improve the midface patient outcome.[2-3] The greatest advantage for combined osteotomies is that both midface and maxillary deformities can be addressed predictably and simultaneously as separate components.[3] The aim of this report is to present a slightly modification of IQLFIIO according to present available literature.

Case Report

Planning

A 22-years-old female patient was referred by her orthodontist to the Department of Oral and Maxillofacial Surgery, Academic Teaching Hospital, Feldkirch, Austria, for orthognathic surgery. She presented a Class III occlusion associated to a midface deficiency due to bi-zygomatic anteroposterior hypoplasia (Figure 1). The facial analysis, CBCT (i-CAT Kavo), impressions, photos, and facial scanning (Bellus3D App for iPhone) were performed. Then the casts were scanned (3Shape scanner) individually and in the planned final oclusion for virtual surgical planning (VSP Dolphin 3D software) (Figures 1-7).[9] It was planned a 5mm midface advancement and approximately 3° maxillary clockwise rotation (CR) associated to bilateral sagital split osteotomy (BSSO) to correct the occlusal plane (Figure 4). Three splints were fabricated: the first, to intra-oral modified quadrangular Le Fort II osteotomy with a 5 mm advancement; the second, for classic Le Fort I

osteotomy for CR of the maxillary complex; and the third, for BSSO to correct the mandibular occlusal plane.

Surgical Procedure

The surgical technique is similar from used by Klug and Cede.[7] The slightly modification proposed here was the horizontal bone cutting in the infra-orbital area performed by means of piezotome between infra-orbital nerve foramen and orbital rim (Figure 5), thus avoiding the orbital floor. The other osteotomy steps were the same but using a reciprocant saw.

Due to planning of a clockwise rotation of the maxillomandibular complex a combined Le Fort I osteotomy was planned. The first step included a Le Fort II osteotomy with 5 mm advancement of the midface (Figure 6). Thereafter, the stabilization of the Le Fort II osteotomy was performed using two 2.0-mm osteosynthesis “L” plates (KLS Martin – Arnett Orthognathic Set) as proposed in the literature.[7] The second step was followed by performing a horizontal Le Fort I osteotomy. This segment was rotated in a clockwise rotation to achieve improvement of the upper incisor inclination and to support the overbite and overjet, and was fixed by bilateral double “L” plates. Finally, the bilateral sagittal split osteotomy of the mandible was followed according to the planning. In order to increase the long-term stability, the final occlusion was planned with a significant overbite in the front area and a little open bite in the posterior part (Figure 7). The patient recovered very well in the post-operative period and she is under closed follow-up (Figures 9-11).

Discussion

Patients who present with true maxillary-zygomatic deficiency on clinical and cephalometric examinations and have a class III dental malocclusion (commonly referred to as “pseudoprognathism” or “dish-face” deformity) but who exhibit a normal nasal-ethmoidal projection are potential candidates for this procedure, as in this case report.[1] The authors agree with the statement that IQLFIIO must be classified as a rare and uncommon osteotomy in the field of craniomaxillofacial and orthognathic surgery, and despite this have been presenting promising stable outcomes.[1-8]

The main modification of intra-oral quadrangular Le Fort II osteotomy from other techniques is to avoid cutting the orbital rim and consequently the orbital floor. This maneuver can help to decrease the nerve damage and preventing some orbital complications.[5,7] According to Park et al., although Le Fort II caused a higher level of neurosensory disturbance than Le Fort I, sensory recovery occurred in most patients between 6 and 12 months after the operation.[10]

Moreover, a CR in the level of Le Fort II osteotomy may cause a huge gap in the infraorbital rim area which would cause aesthetic and stability problems. In recognition on this, the combination of Le Fort I and II is very advisable and enables transverse and vertical corrections as well: multipiece maxillary osteotomies, maxillo-mandibular complex rotations (yaw, pitch and roll movements).[1-7] Therefore, a complementary conventional Le Fort I osteotomy was performed to allow a CR of the maxillary complex after a bi-zygomatic 5mm advancement. The soft tissue improvement and long-term

stability look like being stimulating to perform IQLFIIO more and more for those patients who present maxillo-malar deformities.[7] It can be concluded that combined osteotomies, modified IQLFIIO proposed in this report associated to conventional Le Fort I osteotomy, can improve the outcomes in patients with anteroposterior midface hypoplasia associated to class III Angle occlusion.

Acknowledgements

We would like to acknowledge to the IBRA (International Bone Research Association) to support Dr. Chagas-Júnior with the Scholarship Program.

References

1. Keller, E. E., & Sather, A. H. (1987). Intraoral quadrangular Le Fort II osteotomy. *Journal of oral and maxillofacial surgery*, *45*(3), 223-232.
2. Van Sickels, J. E., & Tiner, B. D. (1994). A combined Le Fort I and bilateral zygomatic osteotomy for management of midface and maxillary deficiency. *Journal of oral and maxillofacial surgery*, *52*(3), 327-331.
3. Choung, P. H., & Kim, E. S. (1997). Combined Le Fort II and I Osteotomy via an Intraoral Approach 1. *International Journal of Oral & Maxillofacial Surgery-Supplement*, *26*.

4. Ronchi, P., Chiapasco, M., & Frattini, D. (1997). Modified intraoral maxillo-malar osteotomy: long-term results in 16 consecutive cases. *Journal of Cranio-Maxillofacial Surgery*, *25*(1), 46-50.
5. Stoelinga, P. J., & Brouns, J. J. (2000). The quadrangular osteotomy revisited. *Journal of Cranio-Maxillofacial Surgery*, *28*(2), 79-84.
6. Urban, S. D., Rebellato, J., & Keller, E. E. (2004). Intraoral maxillary quadrangular Le Fort II osteotomy: a long-term follow-up study. *Journal of oral and maxillofacial surgery*, *62*(8), 943-952.
7. Klug, C., & Cede, J. (2017). Technical modifications for intraoral quadrangular Le Fort II osteotomy. *Journal of Oral and Maxillofacial Surgery*, *75*(2), 402-e1.
8. Wagner, F., Figl, M., Cede, J., Schicho, K., Sinko, K., & Klug, C. (2018). Soft tissue changes in patients undergoing intraoral quadrangular Le Fort II osteotomy versus conventional Le Fort I osteotomy. *Journal of Oral and Maxillofacial Surgery*, *76*(2), 416-425.
9. Oliver Ploder, Robert Köhnke, Heinz Winsauer, Carolin Götz, Oliver Bissinger, Bernhard Haller & Andreas Kolk (2018): Skeletal-versus soft-tissue-based cephalometric analyses: is the correlation reproducible?, Acta Odontologica Scandinavica, DOI: 10.1080/00016357.2018.1515443
10. Park, J. W., Choung, P. H., Kho, H. S., Kim, Y. K., & Chung, J. W. (2011). A comparison of neurosensory alteration and recovery pattern among different types of orthognathic surgeries using the current perception threshold. *Oral Surgery, Oral Medicine, Oral Pathology, Oral Radiology, and Endodontology*, *111*(1), 24-33.

Figures

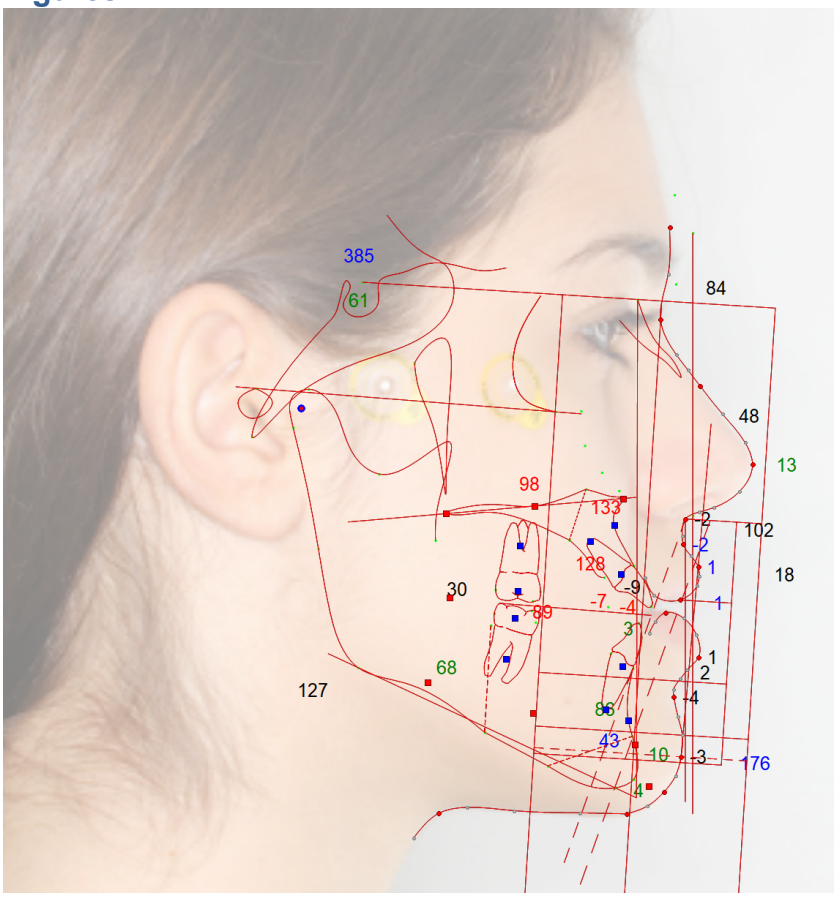

Fig. 1 Preoperative Ceph and 2D Analysis

Dev Norm: (•) Standard ( ) Polygon/Wiggle-gram [ ] Hide Values [ ] Use Same Color Ok Print

Group/Measurement	Value	Norm	Std Dev	Dev Norm
Analyse Feldkirch 2017				
Skelettal Parameters				
SNA (°)	83.8	82.0	3.5	0.5
SNB (°)	88.5	80.9	3.4	2.2 **
ANB (°)	-4.7	1.6	1.5	-4.2 ****
Wits Appraisal (mm)	-6.6	-1.0	1.0	-5.6 *****
Plane Angulation				
Cranio-Mx Base/SN-Palatal Plane (°)	-4.7	7.3	3.5	-3.4 ***
Maxilla Plane Angulation (°)	98.5	85.0	3.0	4.5 ****
Occlusal Plane Angulation (°)	89.0	75.0	3.0	4.7 ****
Mandibular Plane Angulation (°)	68.5	65.0	3.0	1.2 *
Palatal-Mand Angle (PP-MP) (°)	30.0	25.0	6.0	0.8
Gonial/Jaw Angle (Ar-Go-Me) (°)	126.8	123.4	6.7	0.5
Björk Summenwinkel (°)	385.3	396.0	4.0	-2.7 **
Y-Axis (SGn-SN) (°)	61.1	67.0	5.5	-1.1 *
Dental Parameters				
U1 - SN (°)	132.6	102.7	5.5	5.4 *****
U1 - Palatal Plane (°)	127.9	113.0	4.7	3.2 ***
IMPA (L1-MP) (°)	85.9	95.0	7.0	-1.3 *
Overjet (mm)	2.5	2.5	2.5	-0.0
Overbite (mm)	-3.9	2.5	2.0	-3.2 ***
Upper incisor exposure (ULI-Mx1tip) (mm)	1.5	3.5	1.0	-2.0 **
Upper incisor tip projection (Mx1-Sn) (mm)	-9.3	-9.2	2.2	-0.1
Interincisal Angle (U1-L1) (°)	116.3	130.0	6.0	-2.3 **
Soft Tissue Analysis				
Soft Tissue Face				
if Sn' is retrusive - move Sn' 1-3 mm anterior	-1.7	N/A	N/A	N/A
TVL-A' (mm)	-2.1	0.9	1.5	-2.0 **
TVL-UL (mm)	1.2	3.7	1.2	-2.1 **
TVL-LL (mm)	1.3	1.9	1.4	-0.4
TVL-B' (mm)	-4.2	-5.3	1.5	0.7
TVL-Pog' (mm)	-2.6	-2.6	1.9	-0.0
Soft Tissue Vertical				
Anterior Facial Height (N-Me) (mm)	120.6	138.5	5.5	-3.2 ***
Facial Halves (%) N:Sub/Na:Me	43.7	50.0	5.0	-1.3 *
Facial Halves Na'-Sn:Sn-Me' (%)	67.4	90.0	10.0	-2.3 **
Upper Facial Height (G - SN) (mm)	64.9	62.5	2.5	1.0 *
PFH/AFH (%)	75.1	62.9	N/A	N/A
Facial angle (G'-Sn'-Pog') (°)	175.9	169.0	3.4	2.0 **
Nasolabial angle (Col-Sn'-ULA) (°)	101.8	104.0	6.8	-0.3
Soft Tissue Nose				
Nasal Projection Sn´-Tip (mm)	15.1	18.0	2.0	-1.5 *
Nasal Height N/ANS´-N/Me (%)	40.8	43.0	100.0	-0.0
Soft Tissue Lips				
UL length (Sn'-ULI) (mm)	18.2	21.0	1.9	-1.5 *
UL thickness (Mx1 labial-ULA) (mm)	12.2	12.6	1.8	-0.2
LL length (LLS-Me') (mm)	45.1	46.9	2.3	-0.8
LL thickness (mm)	11.9	13.6	1.4	-1.2 *
Soft Tissue Lower Face				
Lower 1/3 of face (Sn'-Me') (mm)	66.2	71.1	3.5	-1.4 *
Lower Face % (Sn-Me':G'-Me') (%)	51.1	54.0	1.5	-1.9 *
Lower Facial 3rds (SnStms/StmiMe')(%)	27.0	33.3	5.0	-1.3 *
Soft Tissue Chin				
Forehead to chin (G'-Pog') (mm)	2.6	5.9	2.3	-1.4 *
Pogonion Position: pog-TVL (mm)	-12.6	6.5	5.8	-3.3 ***
Chin Projection (mm)	-1.0	-2.0	2.0	0.5
Holdaway Angle (NB to H-line) (°)	3.9	8.0	4.0	-1.0 *
Chin % of LFH (B'-Me':Sn-Me') (%)	40.2	N/A	N/A	N/A
Chin Height (Mdl-Me') (mm)	42.8	48.6	2.4	-2.4 **
Chin Thickness (Pog-Pog') (mm)	10.0	11.8	1.5	-1.2 *
Menton Thickness (Me-Me') (mm)	6.4	7.4	1.6	-0.7
Retruded-protruded (Pog'-Sn) (mm)	-2.6	-2.6	1.9	-0.0
Flat-angular (B'-Pog') (mm)	1.6	2.7	1.1	-1.0 *
Short-long (Mdl-Me') (mm)	42.8	48.6	2.4	-2.4 **

Fig. 2 Preoperative Analysis

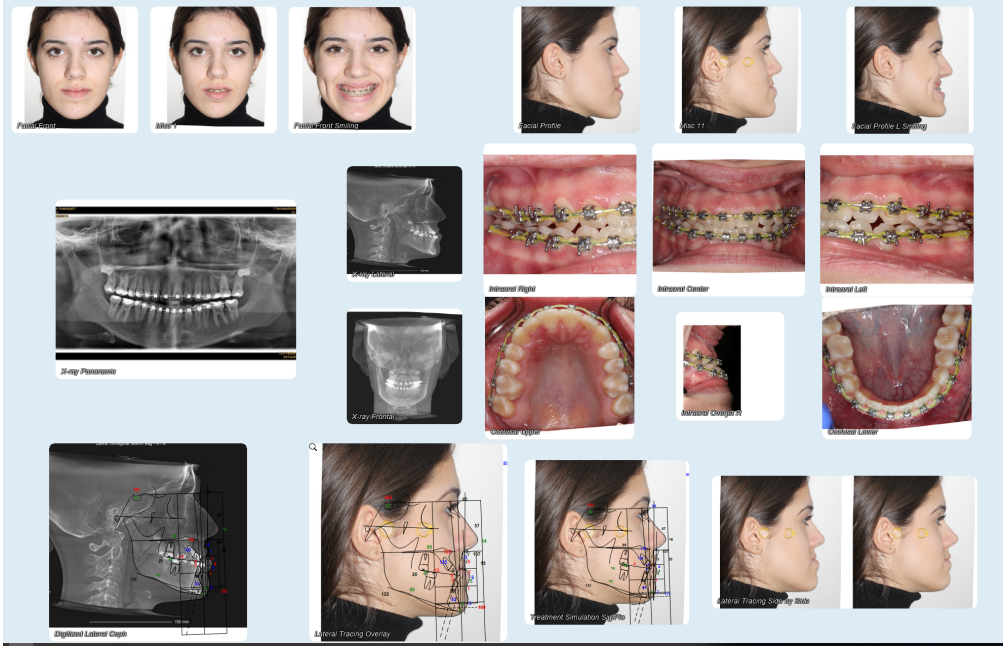

Fig. 3 Dolphin Layout of Preoperative Planning and Simulation of Surgery

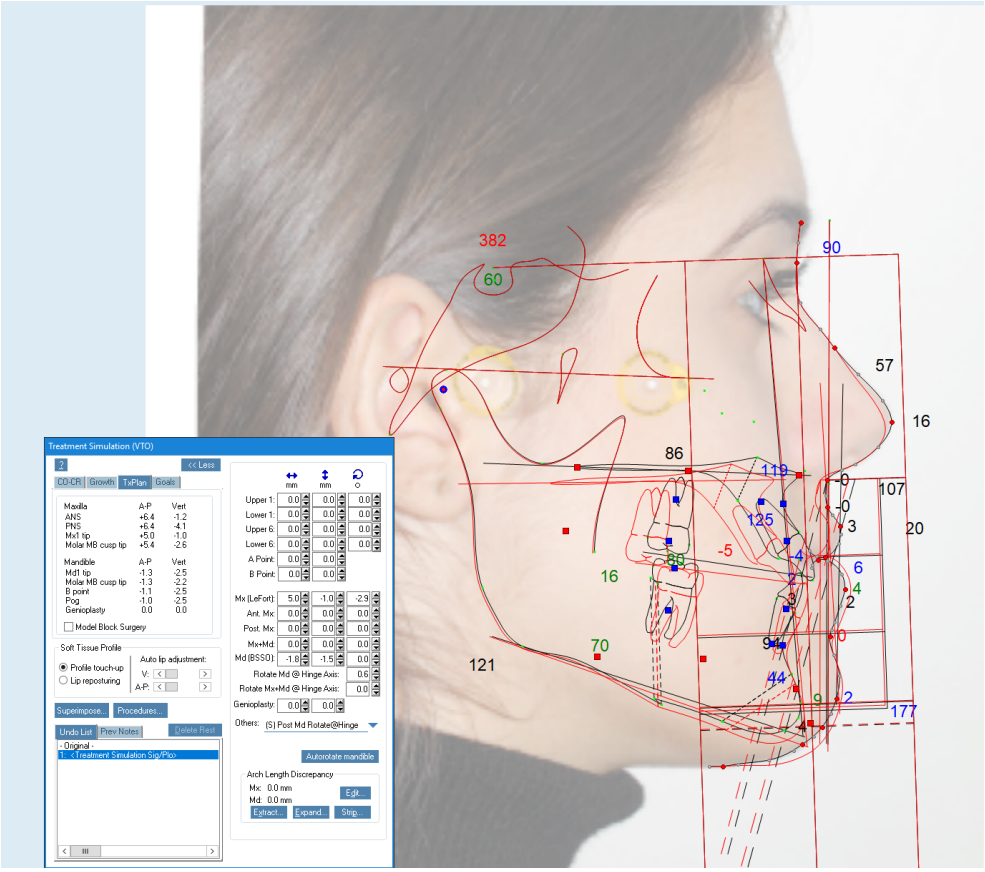

Fig. 4 2D Simulation of Bimaxillary Osteotomy with Clockwise Rotation of the Maxillomandibular Complex

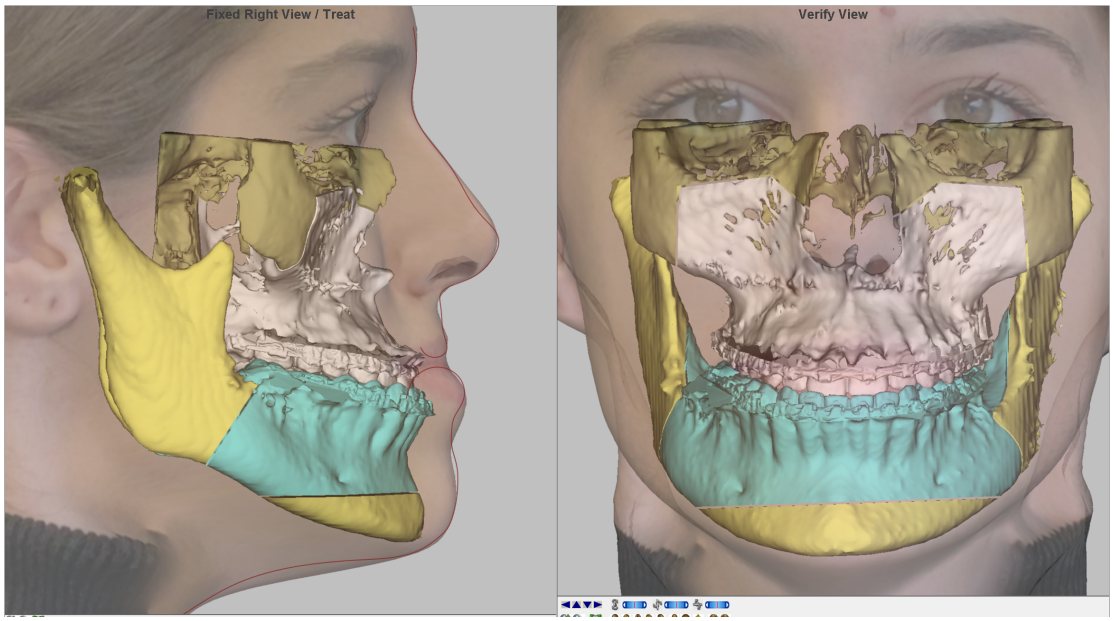

Fig. 5 3D Planning Using Dolphin. Initial Situation

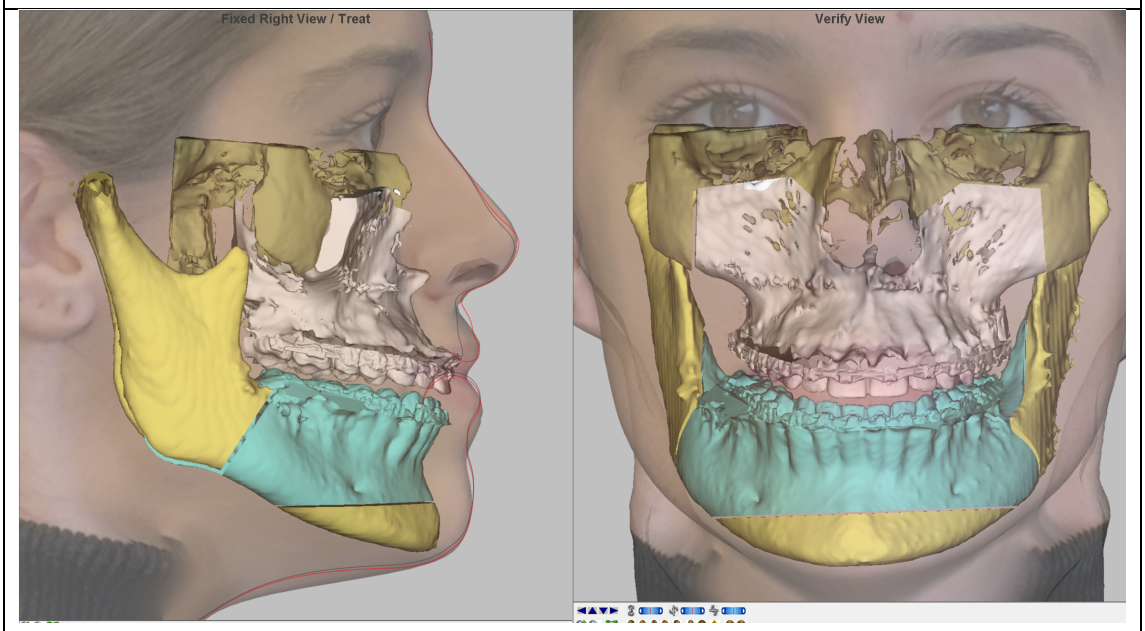

Fig. 6 3D Planning Using Dolphin. Simulation of the First Step During Surgery – Le Fort II Osteotomy

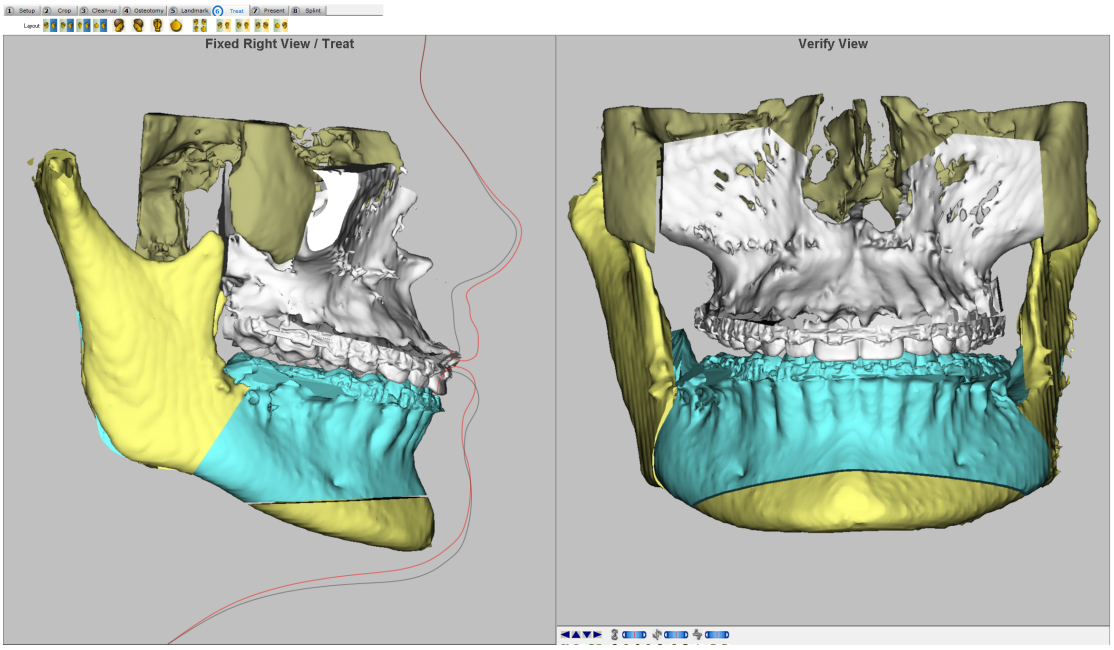

Fig. 7 3D Planning Using Dolphin. Simulation of the Second Step During Surgery – Le Fort I Osteotomy and BSSO

Fig. 8 Side by Side Simulation of Dolphin 2D

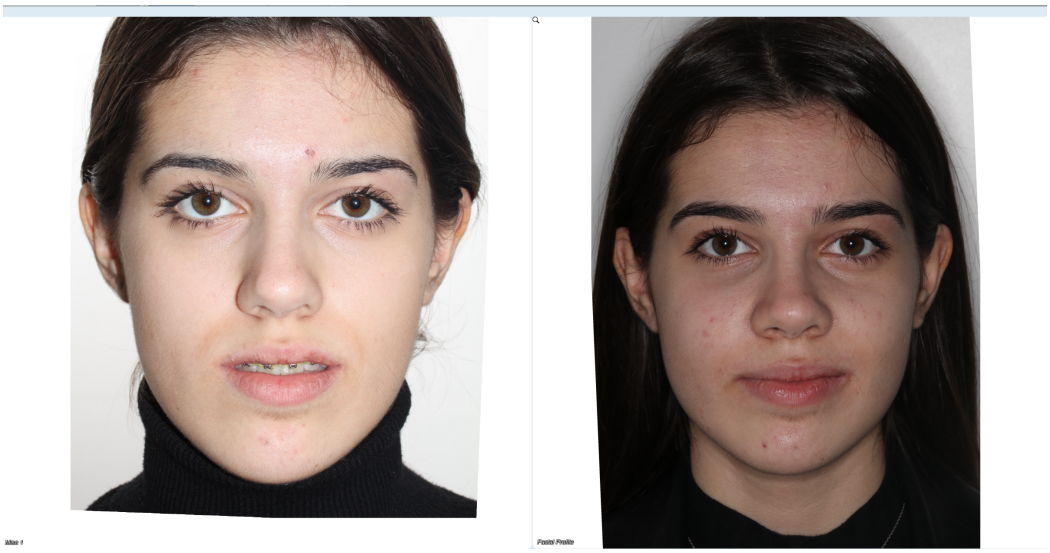

Fig. 9 Pre- and Postoperative Facial Front View (6 Weeks posteoperatively)

Fig. 10 Pre- and Postoperative Facial Profile View (6 Weeks posteoperatively)

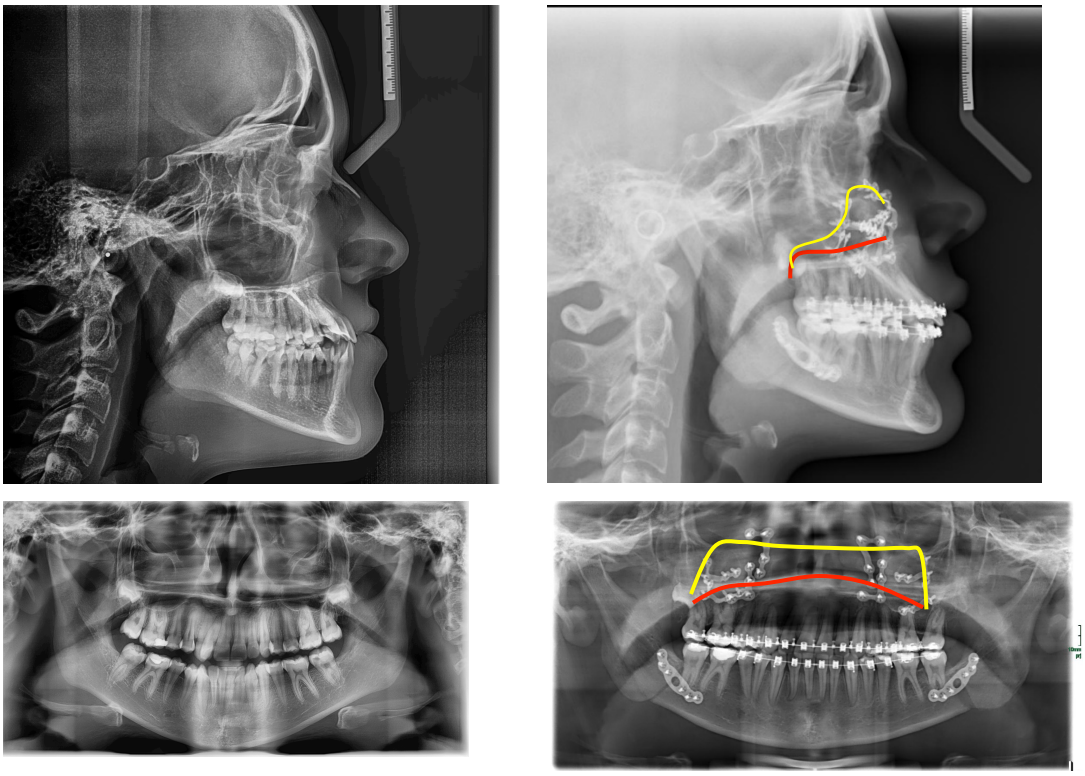

Fig. 11 Pre- and postoperatice radiographs of the patient (yellow – Le Fort II and red – Le Fort I osteotomy)