Sauvé-Kapandji a valid solution for DRUJ arthritis

Martín Nicolás Muñoz - IBRA scholarship program (C) fellowship
Hand Unit Maastricht University Medical Center, Maastricht, Netherlands

Introduction

Numerous procedures have been described for managing the altered distal radioulnar joint (DRUJ), not only because there is no single procedure superior to another but mainly because of a broad spectrum of pathology requiring different surgical techniques for each lesion.
Malunited fractures and traumatic events are the most common causes of DRUJ dysfunction. But it could also be related to radial epiphysiodesis, Madelung deformities, and other pathologies.
If the radius fracture heals with some deformity, either dorsal or volar angulation, the DRUJ is not congruent, and the patient may complain of progressive pain and limited forearm rotation.
The **Sauvé-Kapandji** varies from the Darrach procedure in that it preserves ulnar support of the wrist because the distal radioulnar ligaments and ulnocarpal ligaments are maintained. Both are bailout procedures for advanced and symptomatic DRUJ arthritis. (1)
Regardless of their differences, the S-K and Darrach procedures can decrease pain and swelling and improve the rotation of the forearm. (2)
However, the S-K method is superior to the Darrach procedure in reducing ulnar migration and improving grip strength, and better postoperative cosmetic outcomes, most noticeable when the forearm is in pronation. (3)
On the other hand, preventing carpal bone destruction cannot be a hundred percent achieved with either procedure. (4–6)
The present report aims to describe the demographic, clinical characteristics, and functional outcomes of 30 patients after S-K, with a median of 70 months follow-up.

Methods

Institutional review board approval was obtained retrospectively for reviewing charts of patients who received a Sauvé-Kapandji procedure. Patients were identified via the university hospital upper extremity trauma database (January 2008-September 2021). This hospital serves as a tertiary referral center for treating upper extremities injuries.
Indications for the Sauvé-Kapandji in this study were Arthrosis after Distal Radius fracture 33,3% (n:9 patients), Malunion after DR fracture 33,3% (n:9 patients), Instability of Distal Radial Ulnar Joint 11,1% (n:3) and other indications 22,2% (n:6).
Eventually, from the 40 patients included, two (n=2) died because of some other medical reason, seven(n=7) underwent Sauvé-Kapandji procedure <6 months ago, and one (n=1) declined to participate. Despite this, it was possible to track 70% (n=30) of the patients.
Retrospectively baseline characteristics, operation history, operative details, pre-operative function, potential peri-/postoperative complications, and potential secondary procedures were extracted from hospital medical charts. The baseline characteristics were determined as the data just before the SK procedure.
Quick DASH and PRWHE questionnaires, alongside signed informed consent forms, were retrieved via mail from all included patients after first being contacted by phone to ask for interest in participation.

Figure 1

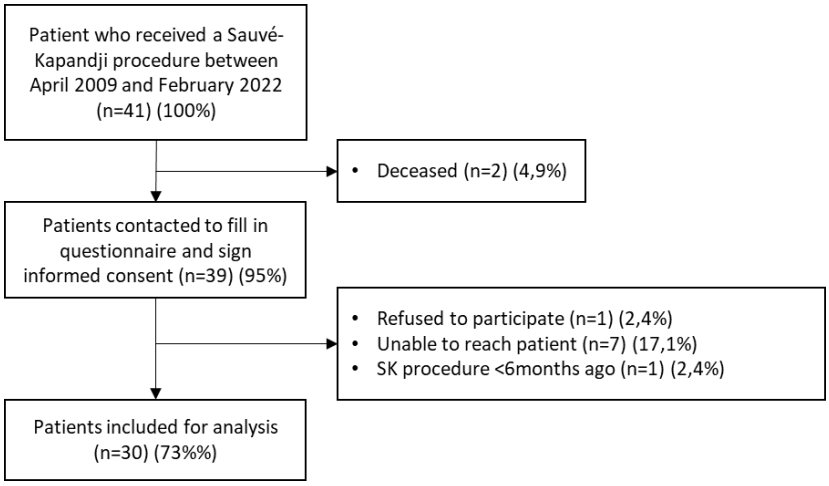

Figure 1 - Flowchart inclusion

Table 1: Baseline characteristics

Variable	Value
Gender (%) (n=30)	
Male	16 (53,3)
Female	14 (46,7)
Age (n=30)	
During procedure (y)	50 ± 18 (20-85)
Current age (y)	57 ± 18 (22-90)
Height (cm) (n=30)	174 ± 12 (155-198)
Weight (kg) (n=30)	77,3 ± 15,2 (55-108)
BMI (n=30)	25,4 ± 3,5 (18,4-31,9)
Smoking status (non, former, current) (%) (n=28)	17 (60,7), 5 (17,9), 6 (21,4)
Pack-years (n=11)	13,3 ± 8,1 (3-30)
Alcohol status (no, yes) (%) (n=28)	13 (46,4), 15 (53,6)
Amount of alcohol per week, median [IQR] (n=13)	3 [11] (1-25)

Abbreviations; n: number of participants involved; y: years; cm: centimeter; kg: kilogram; BMI: body mass index, calculated as weight in kilograms divided by height in meters squared; continuous values displayed as mean ± SD (range) or median [IQR] (range) depending on distribution; absolute values showed as the total amount (percentage).

Surgical technique

Slater 2008 (4) describes the SK procedure technique in further detail. In short, after achieving anesthesia and blood voidance, a longitudinal incision is made over the distal ulna border, exposing the distal ulna between the flexor- and extensor carpi ulnaris tendons. The ulnar head is temporarily placed using a Kirschner wire, followed by an ulnar osteotomy proximal to the metaphysis creating a 10mm pseudoarthrosis. The DRUJ is scraped out, and the spongiosa harvested from the resected ulna was packed into the arthrodesis location. After positioning the ulna, the K-wire is fixated again. One lag screw for compression of the ulnar head in the sigmoid notch, followed by a set screw proximal to the lag screw, was inserted through the joint, taking care that the screws did not penetrate the cortex of the radius, but had good grip and were countersunk into the ulnar head. After flushing, the cavity is closed, inserting the fascia of the pronator quadratus into the defect. The remaining soft tissue and skin are closed in a routine fashion, and splints are applied to keep the wrist and forearm in neutral rotation. In the present study, the SK procedures were performed by three experienced hand surgeons.

Results

The present report aims to describe the demographic, clinical characteristics, and functional outcomes of 30 patients after a S-K, with a median of 70 months follow-up (IQR 44; range 6-146).
The mean age of the participants was 50 years (SD 18; range 20-85) at the time of the procedure, with a male/female ratio of 16/14 (53,3%/46,7%).
Indications for the Sauvé-Kapandji in this study were Arthrosis after Distal Radi Fracture 33,3% (n:9 patients), Malunion after DRF 33,3% (n:9 patients), Instability of Distal Radial Ulnar Joint 11,1% (n:3) and other indications 22,2% (n:6).
Complications occurred in 7 patients (23,3 %), in which four of them presented Ulnocarpal Abutment Syndrome 14,8%; one patient ulnar plus with ulnocarpal impactation (3%), one osteomyelitis ulnar stump (3%), and one compartment syndrome (3%).
Finally, 23,3% of the patients required a second-time surgery. Four of this group needed a Schecker prothese; one was a debridement surgery, one was surgical removal of hardware, and one was an ulnar shortening osteotomy.
Mean postsurgical QuickDASH end PRWHE scores regarding patient satisfaction were 31,5 and 34,5, respectively.

Discussion

As we previously said, multiple alternatives dealing with DRUJ disorders exist. Still, no single procedure is superior to another, mainly because the broad spectrum of the pathology requires different surgical techniques for each lesion. (2)
A current review of the topic shows comparable long-term patient-reported outcomes when treating DRUJ dysfunction between Darrach and Sauvé Kapandji, the most known traditional techniques. (7,8)
Sauvé-Kapandji is an achievable procedure with early good functional results. But it is essential to remember that that is not free from possible complications.
Many unfortunate events like nonunions, delayed union of the arthrodesis, fibrous or osseous union at the pseudoarthrosis, and painful instability at the proximal stump are possible. Complications like these cannot be a hundred percent prevented, as they may occur throughout patients' evolution once the biomechanics of the Distal Radial Joint (DRUJ) is affected. (2)
Our results are comparable to Giberson-Chen et al. showing similar DASH values and the same percentage of complications. In this same study, none of the patients required further revision surgeries. Still, the author emphasizes that a year follow-up after the S-K procedure might be too short for thoroughly evaluating some other complications, including additional revision surgeries. (9)
In our group of patients, four of the seven complications, 57,14%, were due to ulnar stump instability. Minami et al. state that using ECU(Extensor Carpi Ulnaris) tendon (modified Sauvé Kapandji) seems to stabilize the ulnar stump, showing promising results by improving pain at the proximal ulnar stump, rotation, and conserving forearm alignment in both coronal and lateral plane. (10,11)
In the latest stages of DRUJ disorders, in which it is not possible to consider any of the other options mentioned before, semi-constrained prostheses seem to have a promising role as a valid alternative to salvage procedures that enable a full range of motion and the ability to grip and lift weights encountered in daily living activities. (12)
Nevertheless, we believe it is essential to keep developing medical research in this field.

Conclusion

To conclude, we could say that regarding the lack of analysis of some other essential variants in this descriptive report. We would not be able to affirm that S-K is the most suitable treatment for patients with DRUJ disorders or that we could recommend this surgery procedure above another.
However, we all could agree that each treatment should match the patient's necessities according to their characteristics and the clinical stage of the pathology. It means that we should evaluate every single case separately.
On the other side, we could also prevent DRUJ problems due to post-traumatic events after intra-articular distal radius fractures by a better and more complete assessment, for example, a CT-Based Assessment of Fracture Patterns in Distal Radius. (13)

Bibliography

1. Zimmerman RM, Kim JM, Jupiter JB. Arthritis of the Distal Radioulnar Joint: From Darrach to Total Joint Arthroplasty. Journal of the American Academy of Orthopaedic Surgeons. 2012 Oct;20(10):623–32.
2. Lluch A. The Sauvé-Kapandji Procedure. J Wrist Surg. 2013 Feb 8;02(01):033–40.
3. Lamont S, Debkowska M, Johnsen P, Froehle A, Cotterell IH, Isaacs J. Outcomes of Darrach and Sauvé-Kapandji Procedures: A Systematic Review. HAND. 2022 Jul 9;155894472211076.
4. Slater RR. The Sauvé-Kapandji Procedure. J Hand Surg Am. 2008 Nov;33(9):1632–8.
5. Chu PJ, Lee HM, Hung ST, Shih JT. Stabilization of the Proximal Ulnar Stump after the Darrach or Sauvé-Kapandji Procedure using the Extensor Carpi Ulnaris Tendon. HAND. 2008 Dec 21;3(4):346–51.
6. Lamont S, Debkowska M, Johnsen P, Froehle A, Cotterell IH, Isaacs J. Outcomes of Darrach and Sauvé-Kapandji Procedures: A Systematic Review. HAND. 2022 Jul 9;155894472211076.
7. Verhiel SHWL, Özkan S, Ritt MJPF, Chen NC, Eberlin KR. A Comparative Study Between Darrach and Sauvé-Kapandji Procedures for Post-Traumatic Distal Radioulnar Joint Dysfunction. HAND. 2021 May 27;16(3):375–84.
8. Ikeda M, Kawabata A, Suzuki K, Toyama M, Egi T. Outcome of the Sauvé–Kapandji procedure for distal radioulnar joint disorder with rheumatoid arthritis or osteoarthritis: Results of one-year follow-up. Mod Rheumatol. 2018 May 4;28(3):490–4.
9. Giberson-Chen CC, Leland HA, Benavent KA, Harper CM, Earp BE, Rozental TD. Functional Outcomes After Sauve-Kapandji Arthrodesis. J Hand Surg Am. 2020 May;45(5):408–16.
10. Minami A, Kato H, Iwasaki N. Modification of the Sauvé-Kapandji procedure with extensor carpi ulnaris tenodesis. J Hand Surg Am. 2000 Nov;25(6):1080–4.
11. Minami A, Iwasaki N, Ishikawa J ichi, Suenaga N, Kato H. Stabilization of the Proximal Ulnar Stump in the Sauvé-Kapandji Procedure by Using the Extensor Carpi Ulnaris Tendon: Long-Term Follow-Up Studies. J Hand Surg Am. 2006 Mar;31(3):440–4.
12. Savvidou C, Murphy E, Mailhot E, Jacob S, Scheker L. Semiconstrained Distal Radioulnar Joint Prosthesis. J Wrist Surg. 2013 Feb 8;02(01):041–8.
13. Brink P, Rikli D. Four-Corner Concept: CT-Based Assessment of Fracture Patterns in Distal Radius. J Wrist Surg. 2016 Jan 25;05(02):147–51.