IBRA International Bone Research Association

IMPORTANCE OF COMPUTED TOMOGRAPHY AS A PRE-ARTHROSCOPIC STUDY OF THE TEMPOROMANDIBULAR JOINT: A CASE OF PERSISTENT HUSCHKE'S FORAMEN.

Llensa Leandro [1], Daniel Falbo M. de Souza[2]

KEYWORDS

Formamen Huschke, Foramen tympanicum, Temporomandibular joint arthroscopy, persistent foramen tympanicum, Computed tomography.

SUMMARY

Temporomandibular joint (TMJ) arthroscopy is a minimally invasive procedure for the diagnosis and treatment of internal joint disorders. This surgical intervention is considered by the current literature as a technique with a high rate of favorable results and a low rate of complications.

Most of these complications are minor and of short duration. Some of them may increase morbidity; it may be life threatening in rare cases and may require additional emergency surgical procedures.

It is vitally important to have imaging studies prior to surgery for accurate diagnosis and assessment of the anatomical site to be operated on. MRI is the imaging modality that is considered the gold standard in joint diagnosis, providing valuable information of the soft tissue, including the articular disc as the main structure. A pre-surgical computed axial tomography or cone beam

1 Felowship from Department of Oral and Maxillofacial Surgery, Hospital Zonal General Manuel Belgrano, Buenos Aires, Argentina.
2 Fellowship Director from Department of Oral and Maxillofacial Surgery, Hospital Samaritano, Higienópolis, São Paulo, Brazil

tomography should also be routinely requested to assess the bony structures involved.

The CT scan can be used to analyze the presence of anatomical alterations of the TMJ such as the persistence of Huschke's foramen (HF) or tympanic foramen. The HHF is an anatomical variation in the tympanic portion of the temporal bone that is located on the face posteromedial to the temporomandibular joint (TMJ) or anteroinferior to the external auditory canal (EAC).

This anatomical variation may predispose to TMJ pathology or be associated with post-surgical complications from an arthroscopic procedure, either by the unintentional passage of the arthroscope into the CAE and its resulting otologic complications or by the passage of injected substances into the joint, thus being a contraindication for treatment.

This is why it should be considered routine to request a CT scan as a preoperative study prior to TMJ arthroscopy.

INTRODUCTION

Internal disorders of the temporomandibular joint (TMJ) have been classified according to the origin of the problem into myogenic, which are composed of problems in the masticatory muscles associated with the TMJ, and arthrogenic, which include disorders within the components of the TMJ itself. Arthrogenic TMDs include internal disorders, arthralgias, osteoarthritis and osteoarthrosis.[1]

Joint disc displacement is a subgroup of arthrogenic TMDs that manifests with TMJ pain, clicking during jaw function, jaw deviation, and functional limitation of mouth opening.

The prevalence of TMJD has been reported to be around 3.7% to 12% and females have a higher prevalence rate than males. Furthermore, among patients with TMD, about 44.2% and up to 55.6% have TMJ disc displacement and degenerative disorders, respectively. [1]

The main goal of treatment of arthrogenic TMDs is to reduce pain, restore normal jaw movements, and improve patients' quality of life. Reported treatment strategies for arthrogenic TMDs involve three sequences. First, conservative treatments that include medications, patient education and counseling, occlusal splints, physical therapy, and low-level laser therapy. Second, less invasive treatments including intra-articular injection of drugs; (hyaluronic acid (HA), corticosteroids (CS), morphine and/or growth factors found in platelet rich plasma (PRP), arthrocentesis with or without treatment with occlusal splinting or arthroscopy, either alone or in combination with HA or CS or PRP, etc. Thirdly, surgical treatment including minimally invasive arthroscopic procedures or invasive open joint surgeries such as disc plication, discectomy and arthroplasty. Currently, there is no consensus on the most effective treatment for patients with arthrogenic DTM. It is of vital importance to identify causative agents in order to reverse them and slow the progression of the disease.

Currently, temporomandibular joint arthroscopy occupies a very important place in the step-by-step treatment of internal TMJ disorders.

In the current world bibliography there are many articles dedicated to different aspects of this minimally invasive surgery, but there are few previous studies that should be evaluated at the time of indicating or contraindicating the surgical procedure.

Magnetic resonance imaging (MRI) does not use ionizing radiation or radiopharmaceuticals, this being one of its great advantages. The slices can be performed in T1 or T2 sequences (relaxation times). T1 sequences provide very good information of fatty tissues (which are observed bright), while T2 provides information of tissues with high water content, being more useful in pathological processes, since they usually present an increase of vascularization.

In the TMJ, bright images in the joint space in T2 are associated with joint effusion and synovial inflammation, which has been correlated in several articles with pain. In addition, it allows to visualize the articular disc in various

positions during mouth opening and thus to evaluate its reduction capacity. It is considered the gold standard as a diagnostic study to assess temporomandibular dysfunction syndrome.

Computed tomography (CT), also called scan or CAT (computed axial tomography), is the most important diagnostic test to assess bone structures. Its great advantage is the information it provides in the three planes of space.

Cone beam tomography is a technology that allows the scanning and acquisition of specific volume of the patient's head and generates 3D data. By means of tomography, in addition to evaluating the articular bone structures, we can rule out the presence of articular anatomical accidents, such as Huschke's foramen (HH) or tympanic foramen, which, if present, may contraindicate treatment.

This study, as well as MRI, should be considered as a protocol prior to invasive TMJ procedures.

Huschke's foramen is an anatomical variation in the tympanic portion of the temporal bone. When present, it is located on the anteroinferior aspect of the external auditory canal (EAC), or posteromedial aspect of the temporomandibular joint (Figure 1). [2,3]

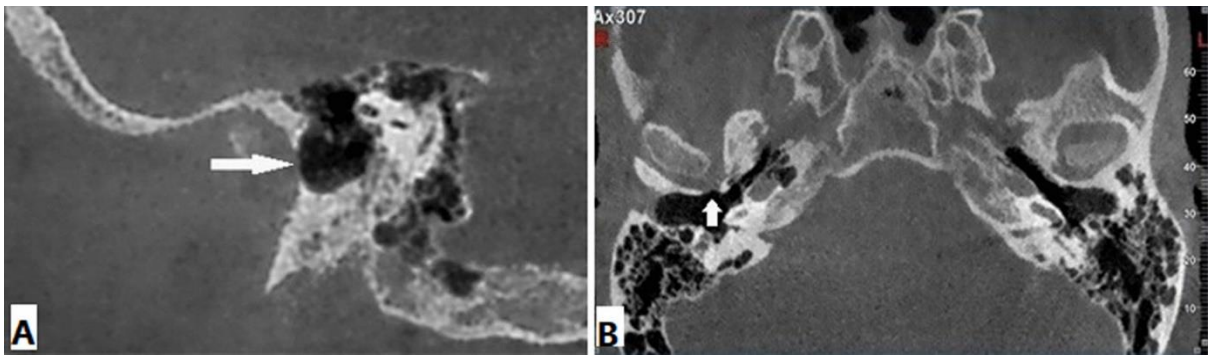

Figure 1
A: Sagittal view, CT scan of right TMJ, white arrow shows bony dehiscence in posterior wall of the joint in direct communication with CAE. B: Axial view, CT scan of right TMJ, white arrow shows bony dehiscence in posterior wall of the joint in direct communication with the CAE.

FH may predispose to TMJ pathology [4] or may be associated with saliva discharge into the EAC during mastication [5,6.] During TMJ arthroscopy, inadvertent passage of the arthroscope into the EAC and resulting otologic complications have also been reported. [7,8]

The tympanic bone, which contributes to the formation of the CAE and tympanic cavity, develops from a process of membranous ossification. The tympanic membrane is formed in utero by the connection of the first entoblastic and epiblastic sacs. At 9 weeks gestational age, four ossification centers develop around the tympanic membrane, which fuse to form a U-shaped bone.

This bone fuses with the squamous portion of the temporal bone during the 35th week of gestational age. Therefore, at birth, the entire tympanic bone is incompletely developed and is U-shaped. Two prominences, one anterior and one posterior to the U-shaped bone, emerge and grow toward each other. These two ossification points fuse at the age of 1 year, the first step in the development of EAC.

The foramen tympanicum persists medial to the fusion point. In most children, the foramen tympanicum gradually becomes smaller and closes completely before the age of 5 years, but occasionally it may persist. Therefore, dehiscence of the tympanic bone present at the precise point of fusion of the two prominences should be considered an anatomical variant only after the age of 5 years (Figure 2).

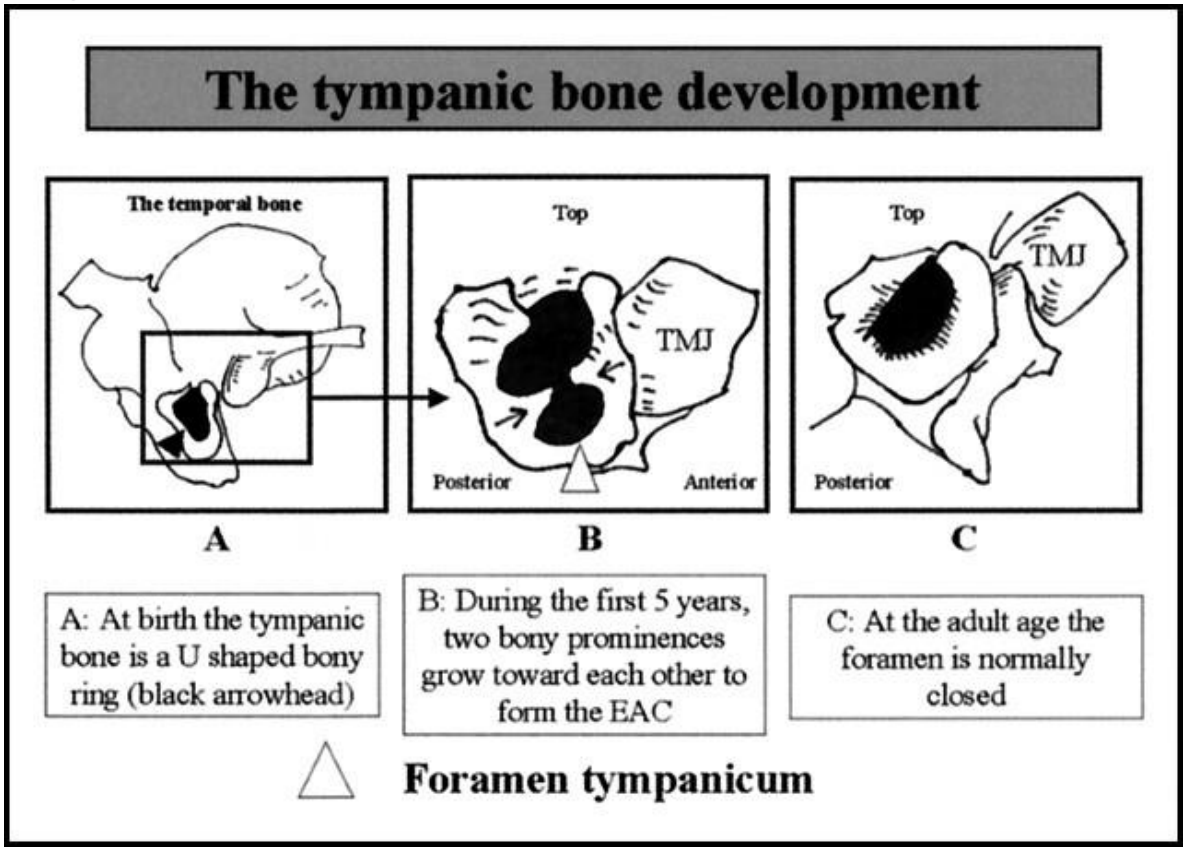

Figure 2

In 1987, the first case of TMJ herniation in the CAE through a patent foramen of Huschke was described. Trauma, inflammation and mass effect are well-known causes of TMJ herniation at the EAC. Spontaneous soft tissue herniation of the TMJ into the EAC through Huschke's foramen is extremely rare, with approximately 30 cases reported in the literature. Symptoms of FH include conductive hearing loss, otalgia, otorrhea, and clicking-type tinnitus; although it can be asymptomatic. [9,10,11]

These herniations are characteristic and fairly easy to identify clinically because they are usually visible only when the patient's mouth is closed and may disappear completely when the mouth is opened (Figure 3).

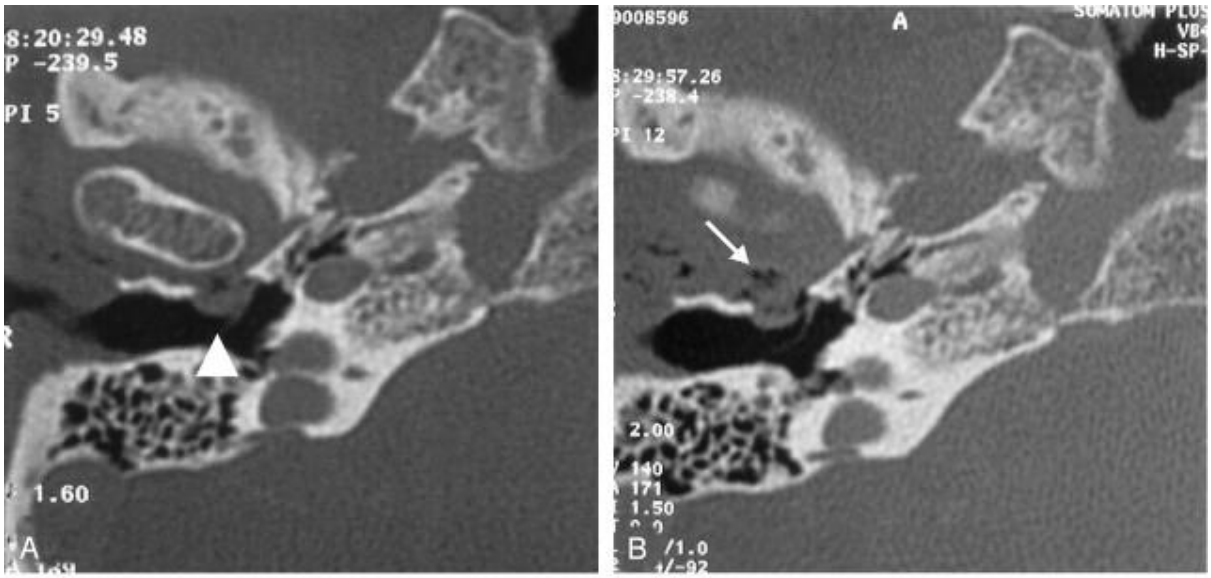

Figura 3
A, Closed-mouth view shows herniation of soft tissue herniation into the EAC 2 mm lateral to the tympanic membrane (*arrowhead*).
B, Open-mouth view show subcutaneous air pockets spreading along the TMJ (*arrow*). Slight retraction of the soft tissue material is noted when the mouth is open.

Cases of herniation of articular tissue through Huschke's foramen with associated symptoms may require surgical intervention for closure of this anatomical feature and correction of associated symptoms. Surgery is performed by pre auricular, endaural or endoscopic approaches through the external auditory canal.

As techniques for TMJ arthroscopy have developed, concomitant complications have arisen.

The presence of this anatomic feature can facilitate injury to the ear during TMJ arthroscopy performed with an endoscope less than 3 mm in diameter, which can penetrate the canal through the patent foramen. Reported otologic complications include tympanic membrane rupture, incus dislocation, tympanic segment injury to the facial nerve, disruption of the labyrinth, and ear infection.

Perhaps the most devastating of the complications reported to date is injury to the middle and inner ear structures, which has resulted in hearing loss, vertigo and facial paresis. [12]

Preoperative detection of Huschke's foramen is of great importance to practitioners performing ear and TMJ surgery.

Few publications in the current world literature develop the associated otologic complications following TMJ arthroscopy, and even fewer refer to an anatomic alteration of the surgical site.

In 1987 Joseph E. Van Sickels published a case of postoperative hearing loss associated with a failed entry into the articular space when performing arthroscopy, having as hypothesis the perforation of the tympanic membrane due to a previous anatomical articular alteration. [13]

CASE PRESENTATION

A 27-year-old female patient, with no relevant general medical history, presented with a history of difficulty in normal mandibular dynamics and pain in the bilateral temporomandibular joint region at the Oral and Maxillofacial Surgery Department of the Samaritano Hospital, São Paulo, Brazil.

The detailed clinical history revealed that the patient has had this symptomatology for one year and in an MRI she presented signs linked to an anteromedial dislocation of the articular disc bilaterally, with reduction in maximum mouth opening, and that she had already undergone non-invasive clinical treatment (including bite plate, physiotherapy and muscle relaxant drugs) for 8 months.

On extraoral physical examination, she presented a maximum mouth opening of 27mm, without deviation in mandibular opening and closing, with pain on palpation in the TMJ region. On intraoral examination, the patient presented complete dentition with correct occlusal relationship.

Given the persistence of bilateral TMJ-related signs and symptoms refractory to clinical treatment, bilateral TMJ arthroscopy is indicated for the patient. Routine pre-surgical studies are requested, including complete blood tests, chest X-ray and electrocardiogram with surgical risk assessment.

As complementary imaging tests, a new MRI of bilateral TMJ with mouth closed and mouth open, and a CT scan of the craniofacial region are requested.

In the next consultation, the patient's studies were evaluated, and the CT scan showed the persistence of a bilateral Huschke's foramen, without herniation of the articular contents towards the external auditory canal (Figure 4).

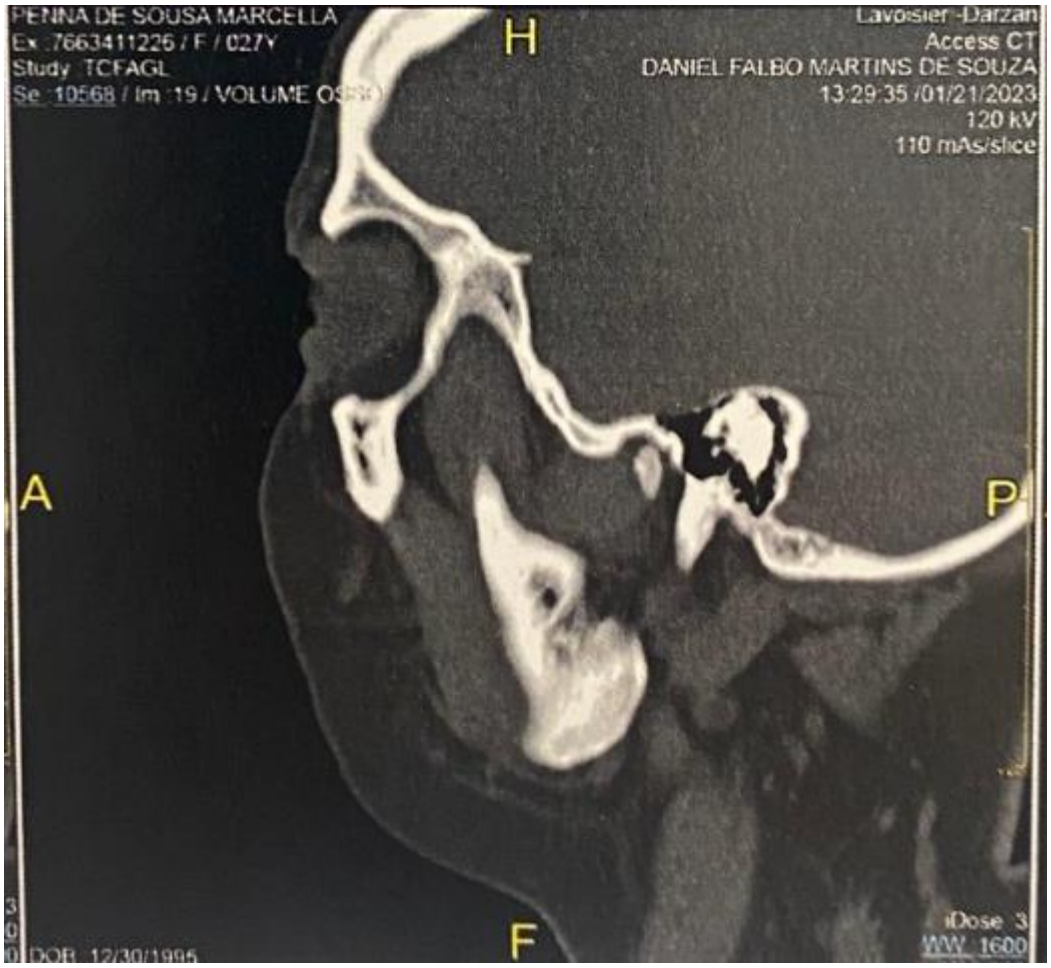

Figure 4

For this reason, it is decided, together with the patient's determination, to contraindicate the TMJ arthroscopy procedure due to the possible complications that may arise and to reinforce the non-invasive clinical treatment to improve the symptomatology.

DISCUSSION

Internal temporomandibular joint disorders are highly prevalent and there is currently no consensus on the ideal treatment to perform.

It is widely known that TMJ arthroscopy is a minimally invasive procedure with favorable short and long term results and a low complication rate.

It is vitally important to perform a thorough preoperative workup clinically and with appropriate imaging studies including MRI and CT.

By means of computed tomography we can rule out the presence of intra-articular anatomical bone accidents which cannot be determined by magnetic resonance imaging and which, if present, may contraindicate treatment, as for example the case of Huschke's foramen (HF).

Cone beam computed tomography (CBCT) is currently the modality of choice for the evaluation of temporomandibular joint bone changes due to lower radiation dose, higher spatial resolution and increasing availability.

The FH is a developmental defect, located posteromedial to the TMJ in the tympanic portion of the temporal bone. It normally closes during growth before 5 years of age. However, it may not close in some cases and remain present throughout life. The prevalence of FH ranges from 1.5% to 43% in different studies.

The presence of FH may be asymptomatic and, therefore, patients with this variation may go unnoticed. Signs and symptoms of FH include middle ear inflammation, tinnitus, hearing loss, otalgia, and TMJ pain []. FH may be associated with soft tissue herniation from the TMJ to the CAE and may predispose individuals to internal joint derangement, in addition to predisposing ear injury during TMJ arthroscopy.

Preoperative detection of HF in patients with TMJD has clinical significance and may affect the treatment plan for these patients.

Surgeons performing TMJ arthroscopy should be aware of the anatomic variants of the temporal bone tympanic plate, specifically the persistent Huschke's foramen.

ACKNOWLEDGEMENT

I am immensely grateful to IBRA for selecting me to participate in this experience, grateful to Prof. Dr. Daniel Falbo for giving me this opportunity as a visitor on his staff and being extremely supportive. Dr. Fablo and his team were very hospitable and made sure that I could participate in all the surgeries and discussions. I would like to highlight the valuable presence of Dr. Bruna Caroline on the team, who also gave me great help at this stage. Finally, I would like to thank my team in Argentina who allowed me to live this experience and I wish to add the knowledge I learned.

REFERENCES

1. Al-Moraissi EA, Wolford LM, Ellis III E, Neff A, The Hierarchy of Different Treatments for Arthrogenous Temporomandibular Disorders: A Network Meta-Analysis of Randomized Clinical Trials, Journal of Cranio-Maxillofacial Surgery, 2020.-
2. Wang RG, Bingham B, Hawke M, Kwok P, Li JR. Persistence of the foramen of Huschke in the adult: an osteological study**.** J Otolaryngol 1991.-
3. Anson BJ, Donaldson JA. Surgical Anatomy of the Temporal Bone. 3rd ed. Philadelphia: W. B. Saunders;1981.-
4. Toyama C, da Silva C, Fugita D, Scapini F. Hernia de la articulación temporomandibular en el conducto auditivo externo. Otol Neurotol. 2009; 30 :426. doi:0.1097/MAO.0b013e318179974e.
5. Rushton V, Pemberton M. Otorrea salival: reporte de un caso y revisión de la literatura. Dentomaxilofac Radiol. 2005; 34 :376–9. doi: 10.1259/dmfr/21133587.
6. Ars B. Le foramen de Huschke**.** Acta Otorhinolaryngol Belg 1988;42:654–658
7. Hawke M, Kwok P, Mehta M, Wang RG. Bilateral spontaneous temporomandibular joint herniation into the external auditory canal. J Otolaryngol 1987;16:387–389
8. Cecire AA, Austin BW. Polyp of the external ear canal arising from the temporomandibular joint: a case report. J Otolaryngol 1991;20:168–170
9. Hasani M, Haghnegahdar A, Khojastepour L, Golbahar Haghighi MJ. Determining the existence of the foramen of Huschke in patients with temporomandibular joint disorders using cone beam computed tomography: retrospective cohort study. BMC Med Imaging. 2022 Aug 13;22(1):145. doi: 10.1186/s12880-022-00850-1. PMID: 35963990; PMCID: PMC9375943.
10. Applebaum EL, Berg LF, Kumar A. Otologic complications following temporomandibular joint arthroscopy. Ann Otol Rhinol Laryngol 1988;97:675–679
11. Herzog S, Fiese R. Persistent foramen of Huschke: possible risk factor for otologic complications after arthroscopy of the temporomandibular joint. Oral Surg Oral Med Oral Pathol 1989;68:267–270
12. Lacout A, Marsot-Dupuch K, Smoker WR, Lasjaunias P. Foramen tympanicum, or foramen of Huschke: pathologic cases and anatomic CT

study. AJNR Am J Neuroradiol. 2005 Jun-Jul;26(6):1317-23. PMID: 15956489; PMCID: PMC8149078.

13. Van Sickels JE, Nishioka GJ, Hegewald MD, Neal GD. Middle ear injury resulting from temporomandibular joint arthroscopy. J Oral Maxillofac Surg. 1987 Nov;45(11):962-5. doi: 10.1016/0278-2391(87)90450-2. PMID: 3312539.