OPEN

Cotton Osteotomy: An Integral Midfoot Procedure for Forefoot Varus Correction

Choon Chief Hong, MBBS, MMed(Ortho), MPH, Simone Santini, MD,†‡§ and Victor Valderrabano, MD, PhD‡§*

Downloaded from http://journals.lww.com/techfootankle by BhDMf5ePHKav1zEoum1tQfN4a+kJLhEZgbsIHo4XMi0hCywCX1AWnYQp/IlQrHD3i3D0OdRyi7TvSFl4Cf3VC4/OAVpDDa8K2+Ya6H515kE= on 01/15/2024

Abstract: Forefoot varus is a component of the adult-acquired flatfoot deformity which had to be dealt with independently because isolated hindfoot procedures are insufficient to address this deformity. The dorsal opening wedge osteotomy of the medial cuneiform also known as the Cotton osteotomy is an effective and reliable procedure in the correction of forefoot varus with consistently reported good outcomes in terms of improved radiographic and functional outcomes with excellent bony union rate. Notably, it is also very versatile in that the degree of sagittal correction can be adjusted freely. The use of anatomic Cotton plates with titanium wedge integration makes the osteotomy even more robust with the prevention of early loss of correction and reduction of shear forces at the osteotomy site. Therefore, we describe our technique and experience using an anatomic Cotton plate with titanium wedge integration in Cotton osteotomy for forefoot varus.

Level of Evidence: Level V.

Key Words: Cotton osteotomy, forefoot varus, flatfoot deformity, plantarflexion osteotomy, medial cuneiform osteotomy

(*Tech Foot & Ankle* 2024;00: 000–000)

Forefoot varus or supinatus deformity is part of the progressive collapsing foot deformity (PCFD) spectrum that is seen in adult-acquired flatfoot deformity involving not only the hindfoot but also the whole foot.[1–3] It is also prevalent in cases of developmental pes planovalgus and medial column instability/osteoarthritis.[1–3] Although the forefoot varus deformity typically develops as a compensatory mechanism when the hindfoot drifts to valgus, it can also be a primary pathology in medial column instability and collapse driving the hindfoot into the valgus instead (forefoot-driven hindfoot valgus).[1,2] This deformity should be addressed independently because hindfoot procedures are futile in treating forefoot varus. A medial column arthrodesis procedure such as plantarflexion first tarsometatarsal arthrodesis (TMT-I or modified Lapidus arthrodesis), naviculocuneiform arthrodesis, talonavicular arthrodesis, as well as a plantarflexion first-ray osteotomy, or the medial cuneiform osteotomy known as the Cotton osteotomy, are commonly used to plantarflex the first ray and restore the medial arch stability.[1–5]

This article focuses on this plantarflexion medial cuneiform osteotomy, a joint-preserving procedure first described by Cotton in 1936 to correct the medial longitudinal arch collapse and therefore restore the "triangle of support" of the foot.[5] The Cotton osteotomy consists of a dorsal opening wedge osteotomy of the medial cuneiform, correcting the flexible forefoot varus deformity. It is commonly performed in combination with other hindfoot procedures to correct the overall PCFD and it is often the last bony corrective procedure because reconstruction of the deformities starts from the proximal aspect at the hindfoot and moves distally once the adequate hindfoot correction is achieved.[1,2] The Cotton osteotomy is versatile in that the degree of plantarflexion is adjustable according to the size of the opening wedge and it has a good union rate with excellent radiographic and functional outcomes.[6] Lastly, it does not burn bridges because it allows further procedures to the medial column should an arthrodesis be necessary for adjacent joint disease in the future.

INDICATIONS AND CONTRAINDICATIONS

Cotton osteotomy is indicated for:

(1) Primary forefoot varus, such as congenital pes planovalgus et abductus et supinatus, overcorrected clubfoot, or tarsal coalition.
(2) Acquired forefoot varus/forefoot supinatus in PCFD.
(3) Secondary or unaddressed forefoot varus after hindfoot valgus corrective procedure (revision surgery).

Cotton osteotomy is contraindicated for:

(1) Arthritic medial column joints such as first tarsometatarsal joint osteoarthritis and/or naviculocuneiform osteoarthritis.
(2) Obvious instability at medial column joints such as first tarsometatarsal (TMT-I) instability or naviculocuneiform joint sagging.
(3) Poor skin condition around the medial cuneiform (eczema, infection, and poor vascular supply).
(4) Severe osteoporosis, Charcot foot.

PREOPERATIVE EXAMINATION, IMAGING, AND PLANNING

Adequate history-taking and clinical examination are crucial in establishing an accurate diagnosis. History-taking should include the duration, location, and type of pain especially if it is mechanical in nature. One must always check for rest pain to rule out possibilities of other pathologies such as Charcot arthropathy, inflammatory/crystal arthropathy, vascular conditions, and infection/malignancy. The patient's premorbid functional status, level of sporting activities, occupation, smoking status, and previous medical and surgical conditions must be obtained. Any concomitant chronic medications such as consumption of anticoagulants, diabetes drugs, or immunosuppressant drugs should be elucidated as it may affect surgery

From the *Department of Orthopaedic Surgery, National University Hospital, Singapore, Singapore; †Department of Orthopaedic and Trauma Surgery, University Campus Bio-Medico of Rome, Rome, Italy; ‡Swiss Ortho Center, Swiss Medical Network, Schmerzklinik Basel; and §University of Basel, Basel, Switzerland.

V.V. is a consultant at Medartis, Basel, Switzerland. The remaining authors declare no conflict of interest.

Address correspondence and reprint requests to Victor Valderrabano, MD, PhD, Swiss Ortho Center, Swiss Medical Network, Schmerzklinik Basel, Hirschgässlein 15, Basel 4010, Switzerland.
E-mail: vvalderrabano@swissmedical.net.

Copyright © 2024 The Author(s). Published by Wolters Kluwer Health, Inc. This is an open access article distributed under the terms of the Creative Commons Attribution-Non Commercial-No Derivatives License 4.0 (CCBY-NC-ND), where it is permissible to download and share the work provided it is properly cited. The work cannot be changed in any way or used commercially without permission from the journal.

Downloaded from http://journals.lww.com/techfootankle by BhDMf5ePHKav1zEoum1tQfN4a+kJLhEZgbsIHo4XMi0hCywCX1AWnYQp/IlQrHD3i3D0OdRyi7TvSFl4Cf3VC4/OAVpDDa8K2+Ya6H515kE= on 01/15/2024

leading to excessive bleeding, hematoma, or wound complications. Any prior treatments such as orthotic usage, injections, or surgery should also be considered.

The clinical examination must be performed comprehensively from the standing to resting position including gait review. Hindfoot alignment (varus or valgus), midfoot (supination or pronation), and forefoot (forefoot varus/valgus/abductus, adductus) must be assessed while standing followed by evaluation of the flexibility of the deformity. This can be performed with a heel rise or active elevation of the midfoot arch while observing for correction of the hindfoot alignment and restoration of the medial arch. At rest, the hindfoot, midfoot, and forefoot must be examined for range of motion and rigidity. Reducibility of the deformity is of utmost importance as it will skew the decision for arthrodesis in a rigid/fixed deformity while joint-preserving procedures, such as the Cotton osteotomy, are preferred for supple/flexible deformity. Specifically, the forefoot must be examined after the hindfoot is reduced to neutral to determine if the forefoot is in flexible compensatory varus.[1,2] Following that, with the hindfoot in neutral, the compensatory forefoot varus ("hidden" forefoot supinatus) if present must be checked for rigidity as mentioned earlier. A flexible compensatory forefoot varus is correctable if the lateral border of the foot can be corrected to a plane perpendicular to the axis of the tibia and the fifth metatarsal head can be palpable along the same plane as the first metatarsal head (planta pedis in one perpendicular plane).[1] Finally, the examination can be completed with an examination of the neurovascular status of the entire foot and ankle. Soft tissue condition of the foot is also very important as the skin envelope is very thin and risks of wound complications are high if surgery is performed in the presence of active soft tissue inflammation such as eczema flare and cellulitis.

The basic imaging modality necessary is typically radiographs in the form of weight-bearing images of the foot (AP/Lateral) and ankle (mortise). Special views such as the Saltzman or Hindfoot Alignment view is instrumental to identifying hindfoot alignment and inframalleolar deformity if any. In particular, the lateral view of the foot is vital to identify the area of deformity in the midfoot affecting the medial arch. The Meary angle and calcaneal pitch can be measured as an objective marker for deformity correction. In addition, the preoperative cuneiform articular angle (CAA) which measures the angle between the proximal and distal articular surfaces of the medial cuneiform (on lateral view) can be utilized to predict graft size intraoperatively because each millimeter increase in the width of the wedge leads to an approximate 2.1 degree decrease of the CAA.[2,7] Conventional or weight-bearing computed tomography scans can be used as adjuncts when there is suspicion of bony coalitions, osteoarthritic changes, or bone erosions while magnetic resonance imaging can be useful in cases where there is potential concomitant soft tissue conditions such as posterior tibial tendon (PTT) injuries, spring ligament tear, or ankle osteochondral lesions to delineate the extent of injuries and command additional procedures such as bone grafting, arthrodesis instead of osteotomy, tendon repair/transfer, and ligament repair/reconstruction to treat the deformity comprehensively.

SURGICAL TECHNIQUE OF COTTON OSTEOTOMY

Setup

Specific surgical instruments and equipment for this procedure should be prepared early and they consist of a periosteal elevator, small Hohmann retractors, small osteotomes, K-wires, microsagittal saw, autograft/allograft, and a Cotton plate, as an anatomic Cotton plate with titanium wedge integration (eg, Cotton Plate Aptus, 2.8 Trilock C-plate [Medartis, Basel, Switzerland]). The patient is anesthetized and placed supine with the foot at the end of the surgical table. A thigh tourniquet is applied to the affected leg, and the foot is cleaned with betadine and draped sterile.

FIGURE 1. Cotton osteotomy—approach. Dorsomedial incision made medial to the EHL tendon. EHL indicates extensor hallucis longus.

 Copyright © 2024 The Author(s). Published by Wolters Kluwer Health, Inc.

Downloaded from http://journals.lww.com/techfootankle by BhDMf5ePHKav1zEoum1tQfN4a+kJLhEZgbsIHo4XMi0hCywCX1AWnYQp/IlQrHD3i3D0OdRyi7TvSFl4Cf3VC4/OAVpDDa8K2+Ya6H515kE= on 01/15/2024

Incision

The medial cuneiform bone can be palpated proximal to the base of the first metatarsal and by following the anterior tibial tendon. It can also be confirmed on intraoperative fluoroscopy if required and marked before incision. A dorsomedial incision is made directly on the medial cuneiform, just medial to the extensor hallucis longus (Fig. 1). Careful dissection is performed until the medial cuneiform is exposed. At this stage, care should be taken to prevent injury to the medial dorsal cutaneous nerve and its branch to the medial cuneiform.[8]

Exposure

The distal and proximal border of the medial cuneiform can be identified clinically by marking the TMT-I and naviculocuneiform joint.; fluoroscopy can be used for confirmation if required (Fig. 2). Care must be taken at the proximal end of the dissection to prevent iatrogenic laceration of the anterior tibial tendon which passes medial to the proximal part of the medial cuneiform to the medial/plantar part of the medial cuneiform bone and first metatarsal base. Similarly, the extensor hallucis longus which is just dorsal to the incision should be retracted properly and protected from injury during exposure to the lateral border of the medial cuneiform bone. No dissection is necessary at the plantar cortex because it should be preserved as the hinge to the dorsal opening wedge osteotomy.

Osteotomy

Once the proximal and distal borders of the medial cuneiform are identified, the osteotomy line is placed in the middle of the bone which is often parallel to the plane of the second tarsometatarsal joint. Insert a K-wire at the midpoint of the osteotomy line and confirm the trajectory with fluoroscopy on lateral view (Fig. 3). Place a small Hohmann retractor on the lateral border of the medial cuneiform to protect the intermediate cuneiform and another Hohmann retractor on the medioplantar border to protect the anterior tibial tendon. Proceed to use the microsagittal saw sliding along the guiding K-wire to perform the osteotomy from dorsal to plantar direction and stop ~5 mm before reaching the plantar cortex (Fig. 4). After the osteotomy is completed, remove the K-wire and use a thin osteotome to distract the osteotomy slowly while avoiding fracture of the plantar cortex hinge (Fig. 5).

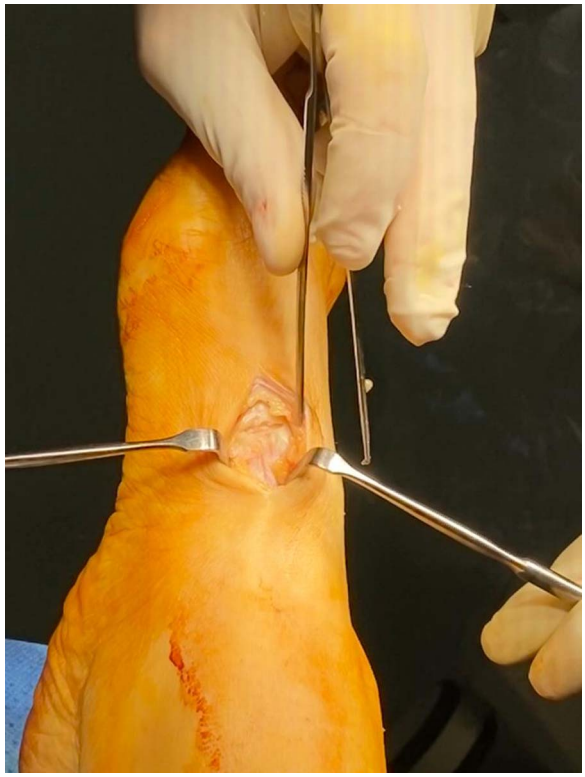

FIGURE 2. Cotton osteotomy—borders of the medial cuneiform bone. The medial cuneiform is exposed with the distal border of the articular surface [first tarsometatarsal (TMT-I) joint] was identified just next to the forceps.

Osteotomy Titanium Wedge

The wedge distractor is inserted to open the osteotomy and the dimension of the necessary wedge is measured. Create an opening wedge (usually 5 to 10 mm) until the desired correction is achieved. This can be confirmed by examining for any residual forefoot varus using both thumbs to push on the first and fifth metatarsal heads respectively to feel if the first metatarsal head is still elevated in relation to the fifth metatarsal. The goal is to have a physiological plane of the planta pedis.

Following that, the width of the wedge is measured which can be seen on the distractor (Fig. 6). Once the size is confirmed, remove the wedge distractor and insert the desired-sized titanium wedge using an introducer that is attached to its base. Ensure that the base of the titanium wedge is inserted flush to the edge of the osteotomy and the dorsal surface of the medial cuneiform (Fig. 7). At this stage, the introducer can be removed and the titanium wedge will be stabilized in the osteotomy by natural compression. The uncoated titanium wedge avoids a possible correction loss during the bone healing period and allows an easy wedge removal (if necessary) in the future, due to the absence of bone ingrowth.

Plate Fixation

Place the anatomic low-profile (1.6 mm thickness) dorsomedial Cotton plate (Cotton Plate Aptus, 2.8 Trilock C-plate [Medartis, Basel, Switzerland]) over the titanium wedge, and an attachment screw is inserted through the plate to fix the titanium wedge to the plate in place (Fig. 8). The position of the plate can be confirmed with fluoroscopy and adjusted if necessary. Once satisfactory, two cortical or locking screws on each side of the plate can then be inserted on both ends of the plate respectively to fix the plate down to the medial cuneiform bone. This plate allows the optional use of both cortical and locking screws although one must take note that cortical screws may not provide as much construct rigidity as the locking screws. Small amounts of autograft or allograft bone chips can now be inserted into the osteotomy space to fill up the residual open wedge bony space (Fig. 9). Final fluoroscopy is performed to verify the plate and screws positioning as well as correction of the deformity (Fig. 10).

Additional Procedures

As the Cotton osteotomy is typically performed as the final bony procedure for the correction of residual forefoot varus after hindfoot bony procedures (eg, Calcaneal osteotomies, hindfoot arthrodesis), additional soft tissue procedures may be required after the Cotton osteotomy such as PTT reconstruction or repair of the spring ligament. Further, a Strayer Gastrocnemius-Soleus release for equinus contracture might be also necessary. Repair of the diseased PTT or even augmentation by side-to-side tenodesis with flexor digitorum longus can allow

Copyright © 2024 The Author(s). Published by Wolters Kluwer Health, Inc.

Downloaded from http://journals.lww.com/techfootankle by BhDMf5ePHKav1zEoum1tQfN4a+kJLhEZgbsIHo4XMi0hCywCX1AWnYQp/IlQrHD3i3D0OdRyi7TvSFl4Cf3VC4/OAVpDDa8K2+Ya6H515kE= on 01/15/2024

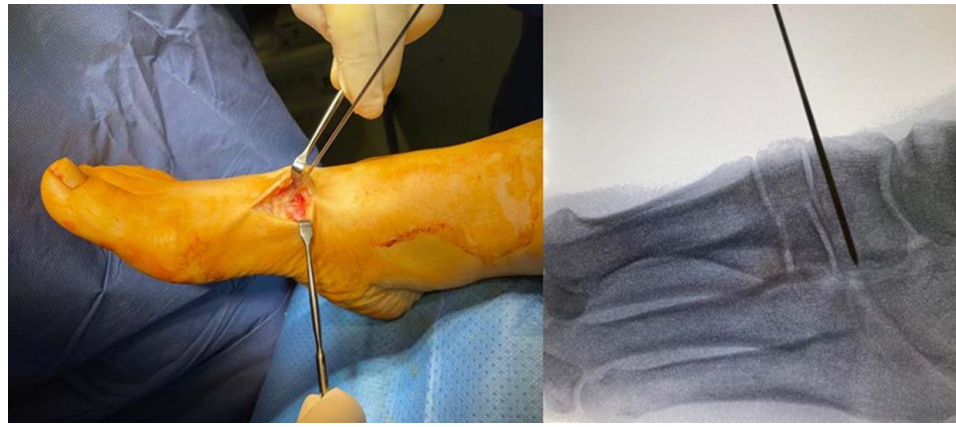

FIGURE 3. Cotton osteotomy—marking of osteotomy. K-wire was inserted at the midpoint of the osteotomy line and confirmed via lateral view on fluoroscopy. Do appreciate the osteotomy line which is parallel to the second tarsometatarsal joint.

tendon recovery and provide significant strength to function as a dynamic stabilizer of the Chopart and subtalar joint medially.[9]

Postoperative Care

Upon skin closure and application of dressings postoperatively, the patient is allowed partial weight-bearing of 15% body weight in a walker boot (Aircast Walker, DJO Global). Typically, the patient is instructed to keep the foot elevated and minimize weight-bearing for the first 2 weeks to reduce swelling and allow surgical wounds to heal. Following that, the sutures are removed at the end of the first 2 weeks and gentle active range of motion exercises can be allowed under physiotherapist supervision. Progressive to full weight-bearing in a stiff-soled high ankle supportive boot is usually allowed from the sixth week postoperative check-up after weight-bearing radiographs are taken, to visualize healing of the Cotton osteotomy. Strengthening exercises and passive range of motion exercises will also be initiated and gradually increased as tolerated. At 12 weeks, a repeat weight-bearing radiograph and clinical assessment are performed to assess for status of the osteotomy and stability of the reconstructed foot (Fig. 11). Most patients can at this stage transition to progressive sports activities.

FIGURE 4. Cotton osteotomy—performing the osteotomy. With protection by Hohmann retractors, the osteotomy is performed using a saw along the guiding K-wire.

FIGURE 5. Cotton osteotomy—opening of the osteotomy. After the osteotomy is completed, the K-wire is removed and an osteotome is used to open up a dorsal wedge carefully without breaking the plantar cortex hinge.

 Copyright © 2024 The Author(s). Published by Wolters Kluwer Health, Inc.

Downloaded from http://journals.lww.com/techfootankle by BhDMf5ePHKav1zEoum1tQfN4a+kJLhEZgbsIHo4XMi0hCywCX1AWnYQp/IlQrHD3i3D0OdRyi7TvSFl4Cf3VC4/OAVpDDa8K2+Ya6H515kE= on 01/15/2024

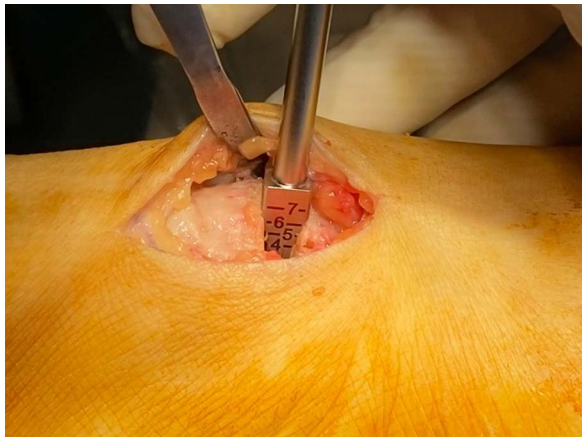

FIGURE 6. Cotton osteotomy—wedge distractor. The wedge distractor is inserted into the osteotomy for distraction, and the wedge's width can be adjusted according to clinical assessment of the forefoot varus correction.

Potential Complications

Intraoperative pitfalls:
(1) injury to medial dorsal cutaneous nerve during superficial dissection to reach medial cuneiform[8];
(2) injury to anterior tibial tendon during exposure of proximal medial cuneiform;
(3) fracture of the plantar cortex hinge;
(4) unintentional osteotomy to the medial border of the intermediate cuneiform or fracture into the TMT-I-joint or naviculocuneiform joint.

Early complications:
(1) wound breakdown or poor healing;
(2) superficial or deep infection.

Late complications:
(1) loss of correction;
(2) nonunion;
(3) malunion.

All late complications can be minimized by using a strong plate and titanium wedge construct with autologous or allograft bone grafting. The advantages and disadvantages of the Cotton Plate Aptus, 2.8 Trilock C-plate [Medartis, Basel, Switzerland] plate are compared with conventional locking plate implants in Table 1. The following risk factors can create long-term complications: noncompliance of patients, smoking, vitamin D3 insufficiency, uncontrolled diabetes, hypoproteinaemia, and others.

FIGURE 7. Cotton osteotomy—insertion of the titanium wedge. The wedge distractor has been removed and the desired sized (in this case is 6 mm) titanium wedge with the introducer seen in the osteotomy site. Ensure that the base of the titanium wedge is flushed to the edges of the dorsal surface of the medial cuneiform.

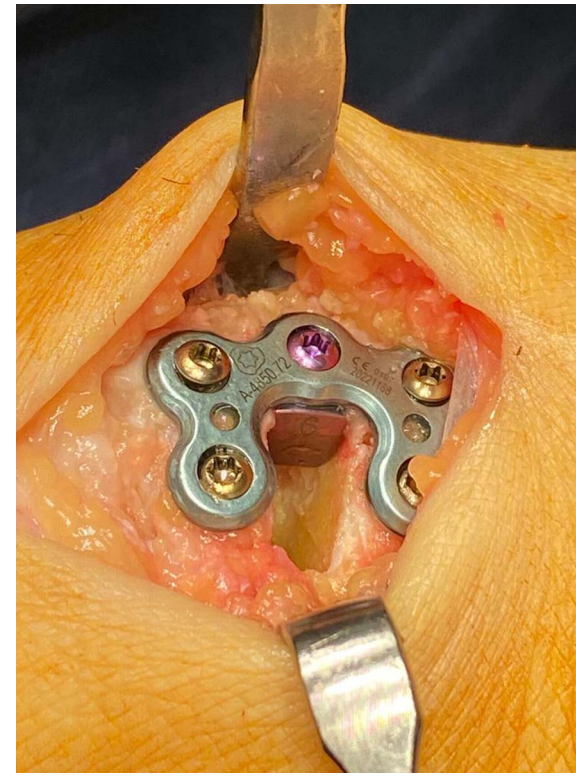

FIGURE 8. Cotton osteotomy—anatomic low-profile plate with titanium wedge. After the titanium wedge is placed in the appropriate position, the anatomic dorsomedial Cotton plate is inserted and an attachment screw (purple) is used to fix the plate and wedge in place (anatomic Cotton Plate Aptus, 2.8 Trilock C-plate [Medartis, Basel, Switzerland]). Two cortical screws are

OWN COHORT AND LITERATURE RESULTS

Between January 2020 and December 2022, the senior author performed 37 Cotton osteotomies using the anatomically shaped Cotton Plate Aptus, 2.8 Trilock C-plate [Medartis, Basel, Switzerland] Plate with titanium wedge followed by bone grafting. All cases healed radiologically within the first 3 months postoperatively. No revision surgeries were needed.

DISCUSSION

Multiple studies have reported that the Cotton osteotomy is an effective procedure in the correction of medial longitudinal arch collapse with high union rates, good radiographic corrections, and low complication rates.[2,3,5–7,10–12] Hirose and Johnson[6] reported good outcomes in 16 feet (15 patients) when correcting for forefoot varus as a component of the adult-acquired flatfoot deformity with all cases achieving statistically significant improvement in radiographic parameters with no cases of nonunion at the final follow-up. They have also suggested that Cotton osteotomy holds several benefits such as preservation of the first ray mobility, predictable union, and ability to vary the

Copyright © 2024 The Author(s). Published by Wolters Kluwer Health, Inc.

Downloaded from http://journals.lww.com/techfootankle by BhDMf5ePHKav1zEoum1tQfN4a+kJLhEZgbsIHo4XMi0hCywCX1AWnYQp/IlQrHD3i3D0OdRyi7TvSFl4Cf3VC4/OAVpDDa8K2+Ya6H515kE= on 01/15/2024

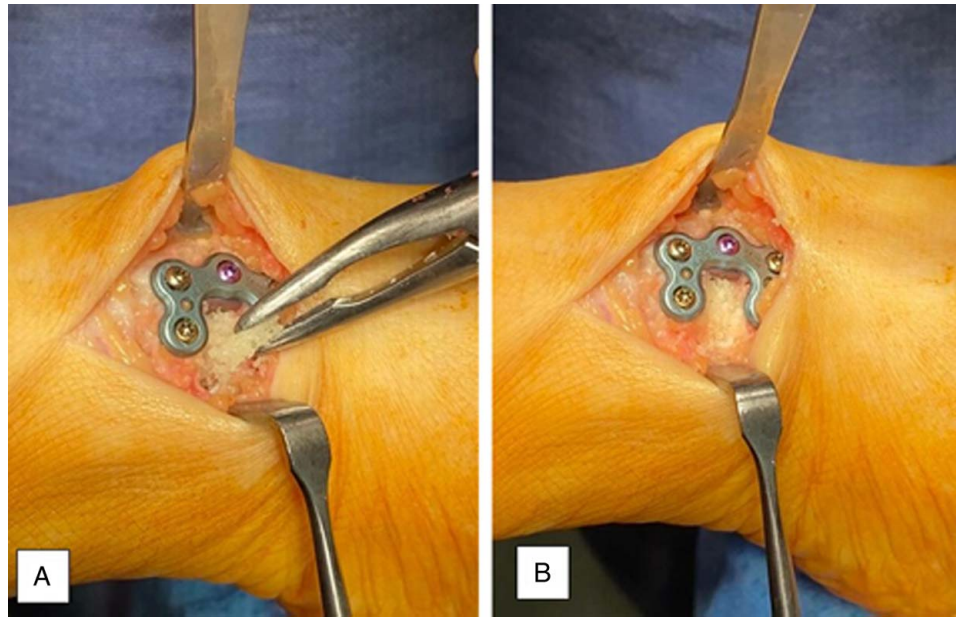

FIGURE 9. Cotton osteotomy—bone grafting. A bone graft can be used to fill up the residual defect in the osteotomy (A). See the final appearance of the compressed bone graft in (B).

amount of correction.[6] Similarly, Boffeli and Schnell[10] also demonstrated good outcomes in 37 feet after Cotton osteotomy for residual forefoot varus with low complication rates (8.1%).

In particular, radiographic corrections of the midfoot sagittal alignment after the Cotton osteotomy are significantly reliable.[2,3,6,7,10–15] Aiyer et al[14] evaluated the radiographic parameters of 67 patients with Cotton osteotomy and reported significant improvement in all the articular surface angles and medial arch height in every patient. When compared to a matched cohort of 28 patients without Cotton osteotomy, they found that the medial arch sag angle which is subtended by the first line along the proximal articular surface of the navicular and the second line along the distal articular surface of the medial cuneiform had an additional 6.5 degrees of correction while the Meary angle did not show any significant differences. The medial arch sag angle is a new radiographic parameter that quantifies the medial arch sag including multiple apices of sagittal deformity (naviculocuneiform joint and/or first metatarsocuneiform joint) which are not assessed by the conventional Meary angle (talo-first metatarsal angle).[14] Another study by Abousayed et al[3] reported a series of patients with the longest radiographic follow-up of Cotton osteotomy in the treatment of forefoot varus with an average duration of 8.6 ± 2.6 years and demonstrated that the lengthened shape of the medial cuneiform did not collapse and was maintained at the final follow-up. However, even though the improvement in calcaneal pitch was maintained at the final follow-up, the authors stated that approximately half the patients (8 out of 14) lost over 50% of the medial column height at the final follow-up indicating that further collapse can still occur through other medial column joints.[3] This highlighted the potential risk of medial column instability after a joint-preserving surgery

FIGURE 10. Cotton osteotomy—final x-rays. Final fluoroscopy images lateral and AP showing the position of the Cotton plate with titanium wedge (Cotton Plate Aptus, 2.8 Trilock C-plate [Medartis, Basel, Switzerland]). One can also appreciate the reduction in CAA and the plantarflexion of the first ray post Cotton osteotomy. CAA indicates cuneiform articular angle.

 Copyright © 2024 The Author(s). Published by Wolters Kluwer Health, Inc.

Downloaded from http://journals.lww.com/techfootankle by BhDMf5ePHKav1zEoum1tQfN4a+kJLhEZgbsIHo4XMi0hCywCX1AWnYQp/IlQrHD3i3D0OdRyi7TvSFl4Cf3VC4/OAVpDDa8K2+Ya6H515kE= on 01/15/2024

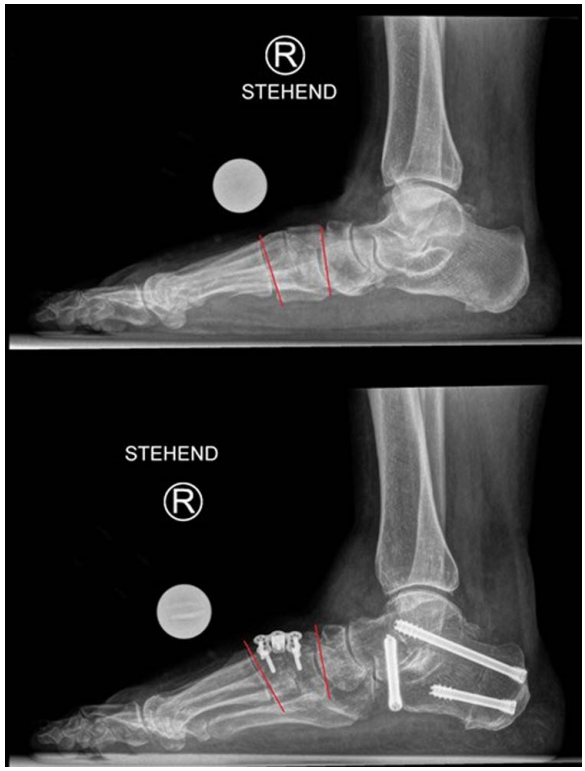

FIGURE 11. Weight-bearing radiograph at 3 months postoperatively showing increased CAA when compared to the preoperative radiograph. Preoperative CAA was measured to be 7 degrees and postoperative CAA was 16 degrees giving rise to an increased CAA of 9 degrees. CAA indicates cuneiform articular angle.

although none of the patients had recurrence of deformity. Regardless, Cotton osteotomy is a very reliable joint-preserving surgery with good correction power to treat the residual forefoot varus after hindfoot correction of the PCFD.[1–3,6,7,10–15]

Although the Cotton osteotomy appears to be a relatively straightforward procedure, the singular step that may be challenging is the amount of osteotomy distraction needed as this decision is often based on clinical examination intraoperatively when the surgeon examines the forefoot to see if the residual forefoot varus is corrected by comparing the position of first metatarsal head in relation to the fifth metatarsal head. However, there are no studies to our knowledge that have examined the maximal width of the wedge size acceptable. A recent consensus paper has proposed that the typical dorsal opening wedge size for Cotton osteotomy ranges from 5 to 11 mm although this was based on expert opinions.[2] One study that may be helpful to address this paucity in literature was reported by Conti et al[15] where they correlated the CAA to the patient-reported outcome scores and found that those with postoperative CAA of ≥ -2 degrees (mild plantarflexion) had better patient-reported outcome scores that those with postoperative CAA of <-2 degrees (moderate plantarflexion). The authors concluded that patients with a more plantarflexed medial cuneiform after Cotton osteotomy had inferior patient-reported outcomes suggesting that overcorrection of the medial column sagittal deformity in PCFD via Cotton osteotomy can be detrimental to clinical outcomes.[15] Therefore, the optimal dorsal opening wedge size should depend on the amount of forefoot varus correction clinically and no overcorrection is necessary. This is also perfectly sensible because the wedge should not be excessively oversized as it could result in negative outcomes such as fracture displacement of the plantar cortex hinge leading to loss of fixation and correction.

One of the benefits of Cotton osteotomy is the predictable bony healing because the extraosseous and intraosseous blood supply to the medial cuneiform is excellent with no watershed regions of poor vascularity.[2,16] Because of this, there is a high rate of consolidation reported with both autograft and allograft bone.[2,16] On top of that, there is no need for fixation of the osteotomy and graft as it is inherently quite a stable osteotomy. Wang et al[11] performed a case-control study comparing the press-fit technique to a single screw fixation of Cotton osteotomy with an allograft bone wedge and found that there are no significant differences found in the radiographic parameters and functional scores at 12 months postoperatively. Similarly, newer techniques of using press-fit trabecular titanium wedges have been shown to have similar radiographic and functional outcomes when compared to allograft bone wedges.[12,17,18] Romeo et al[12] demonstrated in a comparative cohort of 18 patients in each arm treated with allograft wedges and titanium trabecular wedges, respectively, that radiographic parameters and functional outcome scores (AOFAS and VAS) were comparable with no difference in complications. Another case series reported 2 cases of nonunion with trabecular titanium wedge where 1 needed revision surgery, but the other was asymptomatic with no recurrence of deformity.[17] One potential drawback anticipated with this technique would be the difficulty in removing the trabecular titanium wedge after osseointegration in the event of revision surgery for the medial column. Therefore, a small titanium wedge attached to the thin dorsal plate which was used in this technique combines the best of both worlds in which there is a solid wedge with a thin dorsal plate that is easy to remove if needed for revision surgery and there is no need to harvest a big wedge of bone to eliminate donor site

TABLE 1. Advantages and Disadvantages of the Cotton Plate Aptus, 2.8 Trilock C-plate [Medartis, Basel, Switzerland]

Cotton Plate Aptus, 2.8 Trilock C-plate [Medartis, Basel, Switzerland]	
Advantages	**Disadvantages**
Anatomically shaped	Titanium wedge is small and may not be strong enough to hold the correction
Allows the option of cortical and multidirectional angle locking screws	Titanium wedge sits on the dorsal aspect of the osteotomy and does not extend into the entire osteotomy gap which may reduce construct stability
Solid titanium wedge to prevent loss of correction during bone healing	Still requires bone graft to fill up the residual osteotomy gap albeit a lesser amount of graft
Uncoated titanium wedge allows easy wedge removal if needed for future adjacent joint degeneration surgery	
Requires lesser bone graft to fill up the residual gap in the Cotton osteotomy site	

Copyright © 2024 The Author(s). Published by Wolters Kluwer Health, Inc.

Downloaded from http://journals.lww.com/techfootankle by BhDMf5ePHKav1zEoum1tQfN4a+kJLhEZgbsIHo4XMi0hCywCX1AWnYQp/IlQrHD3i3D0OdRyi7TvSFl4Cf3VC4/OAVpDDa8K2+Ya6H515kE= on 01/15/2024

morbidity. This is because only small amounts of bone graft are needed to fill up the residual gap after the titanium wedge is inserted. This is usually sufficient from the autologous bone harvested from concomitant procedures in the hindfoot. Correspondingly, the use of a dorsal wedge plate construct has also been demonstrated to be as good as the dorsal allograft bone wedge in cadaveric radiographic and pedobarographic outcomes studies.[19] However, the authors are limited by the large differences in medical reimbursements and subsidies in health care economies globally to make a meaningful statement about the cost of the implant used in this study.

CONCLUSIONS

The Cotton osteotomy is a reliable and effective procedure to manage residual forefoot varus following hindfoot corrective procedures for PCFD with excellent reported radiographic and clinical outcomes. The benefits of Cotton osteotomy with a titanium wedge attached to an anatomic plate are the easy adjustment of the amount of correction, stable osteotomy, and no loss of correction over time with a high union rate.

ACKNOWLEDGMENT

The authors acknowledge the International Bone Research Association (IBRA) for their utmost support in orthopedic education by providing financial support in the form of a scholarship for a visiting clinical fellowship which culminated in this manuscript.

REFERENCES

1. Tankson CJ. The Cotton osteotomy: indications and techniques. *Foot Ankle Clin*. 2007;12:309–315; vii.
2. Johnson JE, Sangeorzan BJ, de Cesar Netto C, et al. Consensus on indications for medial cuneiform opening wedge (Cotton) osteotomy in the treatment of progressive collapsing foot deformity. *Foot Ankle Int*. 2020;41:1289–1291.
3. Abousayed MM, Coleman MM, Wei L, et al. Radiographic outcomes of cotton osteotomy in treatment of adult-acquired flatfoot deformity. *Foot Ankle Int*. 2021;42:1384–1390.
4. Greisberg J, Assal M, Hansen ST Jr, et al. Isolated medial column stabilization improves alignment in adult-acquired flatfoot. *Clin Orthop Relat Res*. 2005:197–202.
5. Cotton FJ. Foot statics and surgery. *N Engl J Med*. 1936;214:353–362.
6. Hirose CB, Johnson JE. Plantarflexion opening wedge medial cuneiform osteotomy for correction of fixed forefoot varus associated with flatfoot deformity. *Foot Ankle Int*. 2004;25:568–574.
7. Kunas GC, Do HT, Aiyer A, et al. Contribution of medial cuneiform osteotomy to correction of longitudinal arch collapse in stage IIb adult-acquired flatfoot deformity. *Foot Ankle Int*. 2018;39:885–893.
8. Wei B, Lau BC, Amendola A. Surgical anatomy of the medial cuneiform (Cotton) osteotomy. *Foot Ankle Orthop*. 2019;4:2473011419885344.
9. Valderrabano V, Hintermann B, Wischer T, et al. Recovery of the posterior tibial muscle after late reconstruction following tendon rupture. *Foot Ankle Int*. 2004;25:85–95.
10. Boffeli TJ, Schnell KR. Cotton osteotomy in flatfoot reconstruction: a review of consecutive cases. *J Foot Ankle Surg*. 2017;56:990–995.
11. Wang CS, Tzeng YH, Lin CC, et al. Comparison of screw fixation versus non-fixation in dorsal opening wedge medial cuneiform osteotomy of adult acquired flatfoot. *Foot Ankle Surg*. 2020;26:193–197.
12. Romeo G, Bianchi A, Cerbone V, et al. Medial cuneiform opening wedge osteotomy for correction of flexible flatfoot deformity: trabecular titanium vs. bone allograft wedges. *Biomed Res Int*. 2019;2019:1472471.
13. Lutz M, Myerson M. Radiographic analysis of an opening wedge osteotomy of the medial cuneiform. *Foot Ankle Int*. 2011;32:278–287.
14. Aiyer A, Dall GF, Shub J, et al. Radiographic correction following reconstruction of adult acquired flat foot deformity using the cotton medial cuneiform osteotomy. *Foot Ankle Int*. 2016;37:508–513.
15. Conti MS, Garfinkel JH, Kunas GC, et al. Postoperative medial cuneiform position correlation with patient-reported outcomes following cotton osteotomy for reconstruction of the stage II adult-acquired flatfoot deformity. *Foot Ankle Int*. 2019;40:491–498.
16. Kraus JC, McKeon KE, Johnson JE, et al. Intraosseous and extraosseous blood supply to the medial cuneiform: implications for dorsal opening wedge plantarflexion osteotomy. *Foot Ankle Int*. 2014;35:394–400.
17. Tsai J, McDonald E, Sutton R, et al. Severe flexible pes planovalgus deformity correction using trabecular metallic wedges. *Foot Ankle Int*. 2019;40:402–407.
18. Fraser TW, Kadakia AR, Doty JF. Complications and early radiographic outcomes of flatfoot deformity correction with metallic midfoot opening wedge implants. *Foot Ankle Orthop*. 2019;4:2473011419868971.
19. League AC, Parks BG, Schon LC. Radiographic and pedobarographic comparison of femoral head allograft versus block plate with dorsal opening wedge medial cuneiform osteotomy: a biomechanical study. *Foot Ankle Int*. 2008;29:922–926.

 Copyright © 2024 The Author(s). Published by Wolters Kluwer Health, Inc.