Title: Chronic longitudinal instability of the forearm, description and treatment.

Keywords:

Interosseous membrane forearm, forearm instability, Essex-Lopresti injury, radioulnar longitudinal instability.

Summary:

Formed by the radius and ulna, the forearm works as a unit. The interosseous membrane of the forearm is a structure between the ulnar and the radial shaft with the purpose of interconnecting both of them and bringing longitudinal stability, and with the proximal and distal radioulnar joints, is responsible of the correct functioning of the forearm.

Injuries in the interosseous membrane create instability that can lead to proximal impingement of radial head, distal impingement of the ulna or both. Clinically, patients can show pain in the wrist or elbow, weakness of the forearm, and/or pronosupination limitation.

Most frequently it develops after a fall on the hand with axial loading through the forearm and a concomitant radial head fracture.

Known as the Essex-Lopresti injury, the longitudinal instability of the forearm is frequently misdiagnosed as it is rare, so the most usual is treating chronic injuries.

Treatment in acute cases is in discussion but reconstruction of the central band of the interosseous membrane is the recommended in chronic symptomatic cases.

This case study shows a patient with a chronic injury of the membrane and its treatment.

Introduction:

The forearm contains the radius, the ulna and all the flexo-extensor muscles of the hand. It is also the attachment of the braquial muscles that allow elbow flexoextension. The forearm is also responsible of the pronation and supination movements, therefore any injury involving it may cause problems in flexoextensión of the wrist, digits and pronosupination, so potentially severely limiting the function of the upper limb.

Radius and ulna work as a unit thanks to the interosseous membrane and the proximal and distal radioulnar joints (figure 1). The interosseous membrane, being the central band its most important part, is responsible of longitudinal stability of the forearm (is also an important load transferer), so its failure means radial proximal migration and ulnar distal migration, which directly affects the pronosupination movement. This may cause pain distally, because ulnar impingement in the wrist, or distal, because of the excessive contact between the radial head and the capitellum. It is also related to forearm pain, grip weakness and pronosupination limitations.

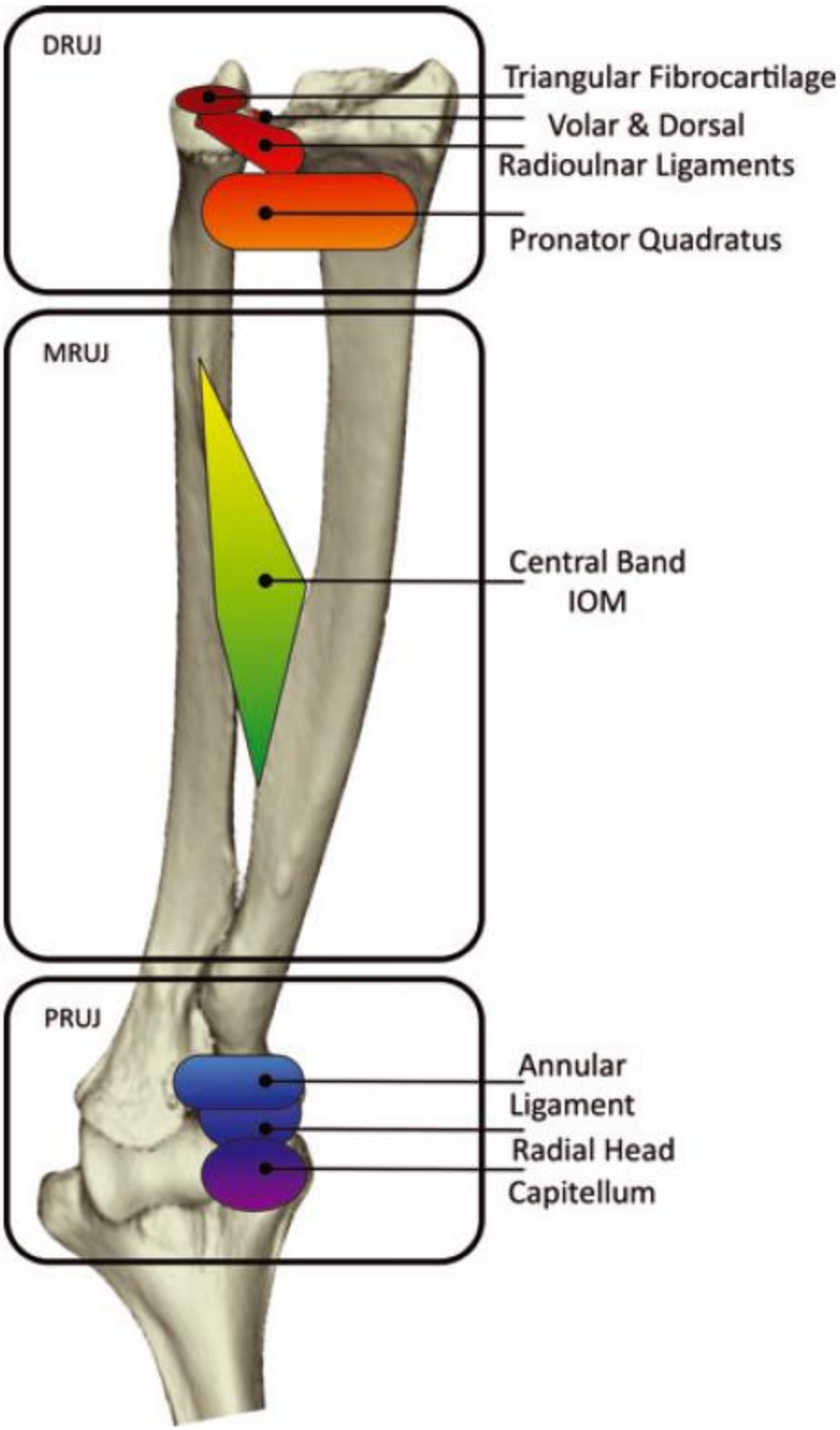

Figure 1. Interosseous membrane and the proximal and distal radioulnar joints. Courtesy Prof. A. Watts

The first in describing this pathology were Curr and Coe in 1946, but it was named after Essex-Lopresti, who presented in 1951 two patients showing some of the features previously mentioned. Since then, its physiopathology and anatomy have been studied by many investigators, trying to understand it and looking for the best treatment.

It is a rare injury, found in 1% of the radial head fractures, although there are some authors considering a higher incidence in recent publications, and is frequently misdiagnosed (over 60% aren´t noted) due to its rarity and limited acute clinical findings.

The cause of the rupture of the membrane is an axial load through wrist to the forearm that tears it and the distal radioulnar joint, leading to a radial head fracture, a radial head dislocation (or both), or a distal ulnar dislocation. The most common presentation is a fractured radial head with pain in the forearm and wrist, usually not important or even absent initially, so, as said, easily misdiagnosed, and lately noticed when chronic. It must be suspected in any patient with a radial head fracture with pain in the forearm or wrist. In the less common case of obvious dislocation of the ulna or distal radioulnar instability diagnosis is easier. Very comminuted fractures of the radial head, or a decrease in the space where the radial head should be, ought to arise suspicion too (*lost space* sign).

In cases where there is suspicion, it is recommended plain X-rays of the wrist, AP, lateral and in pronation with full grip-load to evaluate the distal radioulnar joint but can be normal.

With normal X-rays and big suspicion, MR or ultrasound (*hernia* sign) are recommended.

In the operating room, while treating a radial head injury is always recommended to explore the stability of the distal radioulnar joint and the longitudinal stability of the radius with the pull test and joystick test. The pull test is considered positive when a > 3 mm proximal migration of the radius is observed after applying manual traction to the radius via a bone tenaculum suggesting a possible IOM tear, while a proximal migration of > 6 mm indicates injury to both triangular fibrocartilage and the membrane strongly suggesting longitudinal instability.

As it is frequently misdiagnosed, the most typical presentation in clinic is a chronic injury, frequently with ulnar impingement in the wrist after a failed radial head reconstruction, arthroplasty or direct plain resection. The patient can refer pain in the wrist, elbow or forearm and/or grip loss, or a combination of them all.

Concerning treatment, because of its low healing potential, it is discussed if the membrane has to be reconstructed in acute cases besides repairing the triangular fibrocartilage complex and the radial head, but in chronic cases the recommendation is reconstructing the central band of the membrane.

This procedure can be done using different kind of grafts and synthetic systems but there is not enough data to recommend one over the others.

Case presentation:

We present the case of a 60 year old man, with hypertension as only known pathology, with a left forearm chronic injury of the interosseous membrane.

He had an unknown remote injury in his elbow after a fall, treated with radial head resection. In the last years he refers increasing pain in his forearm, grip strength weakness and lack of the final supination.

Plain X-rays show a proximal migrated radial stump, and dorsally subluxated and distally migrated ulna. (Image 1). He had a positive hernia sign in the ultrasound studies and an unstable distal radioulnar joint. ROM was 30-130º for flexoextension, full pronation and 80º of supination. Grip test was mildly painful.

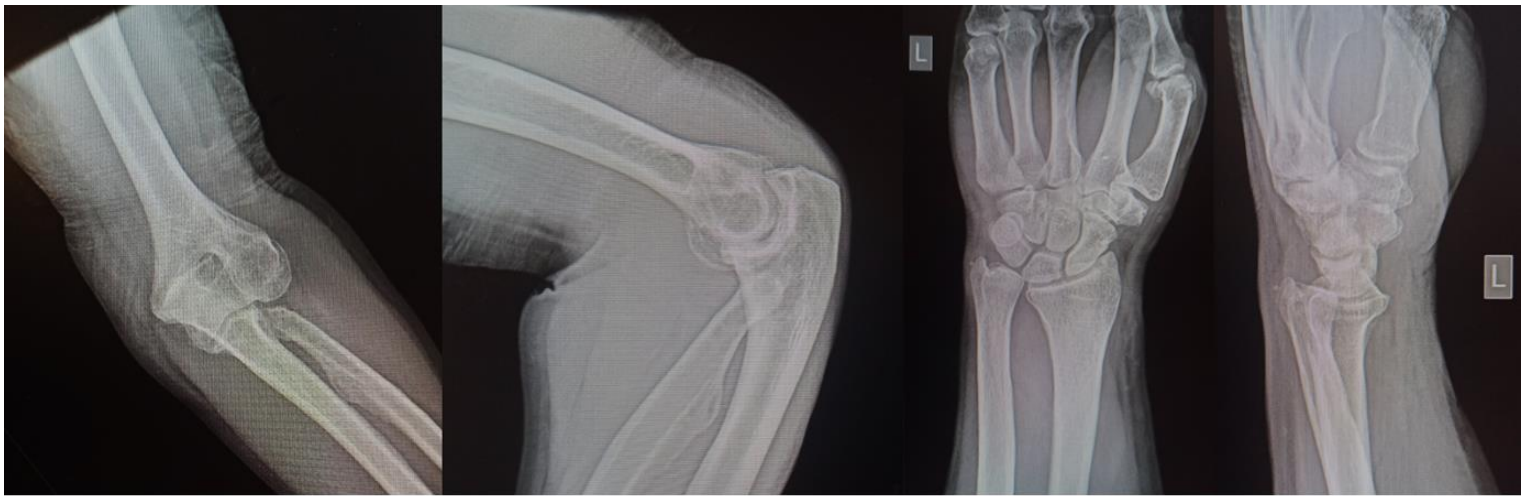

Image 1. Its noticeable the shortened radial stump and the distal ulnar impingement. Courtesy Prof. A. Watts

After explaining the suspicion and explain the possibilities, the patient consented to a reconstruction of the central band of the interosseous membrane and a radial head replacement if possible or an Achilles tendon interposition if not.

Under general anaesthesia, the elbow joint was explored through the former posterior incision confirming a longitudinal instability, reductible almost completely (as seen image 2) and it was proceeded to the reconstruction with a LARS synthetic ligament suspended on two endobuttons, anatomically placed in the most reducted position possible. As there was no possibility of implanting a radial head arthroplasty, the planned Achilles interposition was done besides a repair of the lateral collateral ligamentary complex. ROM before closure was checked, confirming a slightly improved supination.

Image 2. The correction under distally directed longitudinal pushing of the radial stump is clear. Courtesy Prof. A. Watts

The forearm was placed in a sling and the patient discharged from hospital the same day.

No immobilization was used, only a sling for confort, allowing immediate light flexoextensión over the head in supine position various times a day and on a table in neutral position, progressing in ROM as tolerated by the patient. Pronosupination was recommended to be avoided the first weeks and carrying weights too.

Physiotherapy began the same week of the surgery, without forcing the ROM neither causing pain.

A clinic control was made two weeks after the surgery, showing good progression and satisfactory X-Rays.

After six weeks, strengthening exercises begin, and it is expected recovery for usual live in 4 months, with completely, or almost full, painfree grip strength.

Discussion:

Interosseous membrane injuries lead to longitudinal instability of the forearm. As it is not a common injury, and in the beginning the instability of the distal radioulnar joint in not obvious, it´s easily misdiagnosed with bad consequences to the function of the forearm in terms of pain, grip strength an ROM. It is also common in these patients having received other surgeries erroneously treating the distal impingement shortening the ulna, worsening the shortening of the radius, as the injury of the membrane hasn´t been identified.

As mentioned, it is a rare injury but potentially invalidating and results are better with acute treatment as the chronic changes and limitations have not yet appeared. So it is really important to be trained in its diagnosis as it can be challenging.

The best clinical tests seem to be the *hernia sign* in ultrasound, instability test for the wrist, pain assessment of the forearm and wrist in the context of a radial head injury, and intraoperative pull test of the radius. Apart from the obvious cases with a dislocated radial head or distal radioulnar joint, in the X-rays, it´s very suggestive of longitudinal instability a burst fracture of the radial head with no space for the head under the capitellum (*lost space* sign)

Reconstruction of the central band of the membrane is a procedure that seems to be a good solution, returning a painfree forearm with almost normal grip. There are different ways of doing it with good results but further studies have yet to be done to recommend one instead of the others.

Aknowledgments:

I am grateful to the members of the Upper Limb Unit of Wrightington Hospital and its fellows, especially Prof. A. Watts. Each of them shared unconditionally their knowledge and made me feel comfortable.

References:

1. Sabo MT, Watts AC. Longitudinal Instability of the Forearm: Anatomy, Biomechanics, and Treatment Considerations. Shoulder & Elbow. 2012;4(2):119-126. doi:10.1111/j.1758-5740.2011.00172.x
2. Sabo MT, Watts AC. Reconstructing the interosseous membrane: a technique using synthetic graft and endobuttons. Tech Hand Up Extrem Surg. 2012 Dec;16(4):187-93. doi: 10.1097/BTH.0b013e3182634ce4. PMID: 23160548.
3. Wegmann K, Dargel J, Burkhart KJ, Brüggemann GP, Müller LP. The Essex-Lopresti lesion. Strategies Trauma Limb Reconstr. 2012 Nov;7(3):131-9. doi: 10.1007/s11751-012-0149-0. Epub 2012 Oct 25. PMID: 23096260; PMCID: PMC3482440.
4. Masouros PT, Apergis EP, Babis GC, Pernientakis SS, Igoumenou VG, Mavrogenis AF, Nikolaou VS. Essex-Lopresti injuries: an update. EFORT Open Rev. 2019 Apr 29;4(4):143-150. doi: 10.1302/2058-5241.4.180072. PMID: 31057951; PMCID: PMC6491950.