Guided Chin Repositioning: A Retrospective Study on Accuracy.

Luis Fernando de O. Gorla* - Department of Diagnosis and Surgery, São Paulo State University (UNESP), School of Dentistry, Araraquara, São Paulo, Brazil.

Marisa Aparecida Cabrinni Gabrielli - Department of Diagnosis and Surgery, São Paulo State University (UNESP), School of Dentistry, Araraquara, São Paulo, Brazil.

José Cleveilton dos Santos - Department of Diagnosis and Surgery, São Paulo State University (UNESP), School of Dentistry, Araraquara, São Paulo, Brazil.

Muzzammil Nusrath - Department of Oral and Maxillofacial Surgery, Royal Hallamshire Hospital, Sheffield, UK

Nicholas J. Lee - Department of Oral and Maxillofacial Surgery, Royal Hallamshire Hospital, Sheffield, UK

*Corresponding author.

E-mail address: fernando.gorla@gmail.com

Abstract - Gorla LFO. Guided Chin Repositioning: A Retrospective Study on Accuracy. [Research Project Concluded].

Genioplasty is a commonly employed surgical technique aimed at correcting chin deformities. It involves an osteotomy of the inferior border of the mandible, enabling three-dimensional movement and repositioning of the chin. Various methods are utilized to determine the osteotomy line and guide the movement of the distal osteotomized chin segment. This study aims to evaluate the accuracy of results achieved using a set of surgical guides, comprising three components: a dentosupported drilling guide, a cutting guide and a repositioning guide. For this retrospective study, data from 15 adult patients undergoing orthognathic surgery to correct dentofacial deformities will be analyzed. All patients underwent virtual planning preoperatively. Surgical outcomes will be measured and compared with virtual planning to assess the positional and rotational accuracy of three-dimensional planning. The guided technique demonstrated effectiveness in achieving clinically acceptable accuracy in all directions and rotations, except for pitch: 3.26° (IQR2.06 – 5.20°). Despite suboptimal pitch outcomes, these guides assist surgeons in avoiding contact with surrounding noble anatomical structures, such as dental roots and the mental nerve. Furthermore, the design allows for minor incisions and less dissection during genioplasty, eliminating the need for repeated intraoperative measurements and visual assessments. This makes it feasible for less clinically experienced surgeons to achieve more ideal surgical outcomes, presenting a viable option for genioplasty. To ensure the advantages offered by the guides and accuracy in all rotations, we recommend further research involving guides made of more rigid materials, as well as customized implants.

Key words: Genioplasty, three-dimensional printing, computer-assisted surgery.

The chin, positioned prominently within the facial structure, plays a crucial role in contributing to facial symmetry and harmony[1]. Factors such as the size, shape, position, and proportion of the chin in relation to other facial elements significantly influence the overall harmony of the facial profile[2, 3].

Genioplasty, a widely utilized surgical technique for addressing chin deformities, entails osteotomy of the mandible's inferior border, allowing for three-dimensional chin movement to achieve the desired new position. Since its initial description by Trauner and Obwegeser in 19574, genioplasty has undergone substantial improvements. Meticulous surgical planning is essential for optimal outcomes, as the location of the osteotomy and manipulation of the bony segment directly impact surgical results[5].

Various methods can be employed in genioplasty to determine the position of the osteotomy line during surgery and to assess and guide the movement of the distal osteotomized chin segment[6, 7]. In the past, genioplasty heavily relied on the surgeon's experience, and preoperative two-dimensional measurements were limited[8].

Currently, surgeons can create highly effective surgical plans using computer-aided surgical simulation (CASS) technology[9, 10]. With rapid advancements in this technology, surgeons can preoperatively design surgical guides, which can be accurately transferred to the patient in the operating room, aligning with the planned movements made on the computer[11, 12].

This study aims to evaluate the accuracy of results achieved using a set of surgical guides, comprising three components: a dentosupported drilling guide, a cutting guide, and a repositioning guide.

MATERIALS AND METHODS

Ethics

This work was performed following the rules laid down by resolution 466/12 of the National Health Council of the Brazilian Ministry of Health and was referred to by the Committee of ethics in research of the São Paulo State University (UNESP), School of Dentistry, Araraquara, under protocol number 69751123.1.0000.5416.

Sample

Through non-probability convenience sampling, data were collected from the tomographic (CT) examinations of 30 adult patients who underwent orthognathic surgery, including genioplasty, to correct dentofacial deformities between 2019 and 2023. Among these patients, 15 had undergone genioplasty without the assistance of surgical guides, while the repositioning of the chin in the remaining 15 was achieved using the proposed guides. Notably, these patients had not undergone any prior surgical procedures in the maxillofacial region, such as Le Fort I osteotomies, sagittal osteotomies, surgeries for trauma treatment, or interventions for maxillofacial pathologies. It is crucial to emphasize that the type of chin deformity and the magnitude of the surgical movements performed were not standardized. A total of 30 selected CT scans in "Digital Imaging and Communications in Medicine" (DICOM) format were employed for analysis. Each patient contributed two CT scans to the study: one preoperative tomography obtained between the 15th and 45th day before the surgical procedure for surgical planning, and the other an immediate postoperative tomography obtained between the 1st and 3rd day after the surgical procedure.

Surgical Planning and Surgery

The DICOM data from preoperative CT and stereolithographic data (STL) from surface scanning of the dental arch (3Shape, Copenhagen, Denmark) were obtained to construct a composite skull model with accurate dentition. Dolphin Imaging 11.95 Premium (Dolphin Imaging and Management Solutions, Chatsworth, CA) was used for the segmentation of CT images and the virtual surgical simulation after a comprehensive 3D evaluation of the patients' dentofacial deformities, generating stereolithography models (STL) on segments in a planned position. Surgical templates were designed based on data from virtual surgical simulation in Materialise 3-matic 17.03 (Materialise, Leuven, Belgium) and fabricated by printing using Anycubic Mono-X (Anycubic, Shenzhen, China) with biocompatible resin Prizma Bio Guide (Makertech Labs, Tatuí, SP, Brazil). The surgeries were performed by different surgeons from a single center (Oral and Maxillofacial Surgery and Traumatology Service of the School of Dentistry, Araraquara – São Paulo State University).

Guides design

To position the guides precisely without requiring a large bone contact area, our preference is to initially use an occlusal-supported drilling guide (G1). This allows for minimizing incisions and dissection. The drills performed by G1 facilitate the adequate positioning of the cutting guide (G2), which is secured in place by two screws in the inferior holes to prevent rotation. This method eases the osteotomy process and preserves vital structures. After completing the osteotomies, the positioning guide (G3) is employed to reposition the chin segment by inserting two screws in each segment using the pre-drilled holes. Once the final position of the genioplasty is achieved, a 2.0 titanium plate is used to secure the chin segment while the positioning guide (G3) is still in place. This set is illustrated in Figure 1,2 and 3 respectively.

Methodology to analysis of chin positioning accuracy

The accuracy of the genioplasty was evaluated by comparing 3D virtual surgical planning (3D VSP) with the postoperative outcomes. Initially, a voxel-based application15 was used to superimpose the areas that was not moved by surgery, i.e. the distal mandibular region above the osteotomy of the genioplasty, in both pre and postoperative CT. Thus, postoperative DICOM files were also segmented originating a postoperative STL models. Planned and postoperative outcome STL of mandible and chin were imported into Materialise 3-matic 17.03 (Materialise, Leuven, Belgium) to quantify the linear and angular differences between planning and outcomes.

To avoid the observer bias, 3 reference points were initially digitized on the chin segment of the planned model: The Pogonion and 2 points located at the right and left lower borders of the chin segment, and a “reversed” routine developed by Xia et al.[8] and Hsu et al.[11] was used to ensure the correspondence of these points between the planned and the postoperative.

Calculate Differences

To measure the differences, the centroid of the chin was calculated. The centroid coordinates (xc, yc, zc) are the mean of the coordinates to the reference points created in both STL surfaces, 3D VSP and postoperative[11].

Differences in the x (transversal), y (sagittal), and z (vertical) directions between the planned and postoperative centroid positions were computed. Rotational differences also were computed, as discrepancies in pitch, roll, and yaw. Pitch was defined as the rotation around the x axis, roll as the rotation around the y axis, and yaw as the rotation around the z axis. All data were presented as absolute values.

Statistical Analysis

Initially, we ensured that the minimum number of individuals to guarantee the reliability of the research was met through a sample size calculation performed using an online tool available at: http://calculoamostral.bauru.usp.br/calculoamostral. The data regarding accuracy, tabulated in the Microsoft Excel software (Microsoft Corporation. Microsoft Excel [Internet]. 2018, were subjected to statistical analysis using IBM SPSS Statistics 20 (SPSS Inc., Chicago, IL, USA). The positional and rotational absolute data, were underwent the Kolmogorov-Smirnov normality test to assess their distribution for each of the six variables related to accuracy (transversal, sagittal, vertical, roll, pitch, and yaw). In the event of non-normal distribution in any of these variables, all data were presented with timely descriptive statistics and non-parametric tests. Intra-class correlation coefficient (ICC) tests were performed with 20% of the total sample (6 individuals) to assess inter-and intra-observer reliability, where <0.50 = low reliability; 0.50-0.75 = moderate reliability; 0.75-0.90 = good reliability; > 0.90 = excellent reliability. Accuracy was assessed using Tukey-Hinges interquartile ranges (IQR) to determine if the technique achieved results within the limits described in the literature as clinically acceptable.

RESULTS

The intra-class correlation coefficient (ICC) was applied to assess inter and intra-observer reliability over a 95% confidence interval, demonstrating excellent reliability (>0.90) for all variables.

To aid in the interpretation of accuracy measurement results for the chin, some authors have deemed positional differences smaller than 2 mm and orientation differences smaller than 4° to be clinically insignificant[16-18]. Table 1 presents the linear and angular variances between the planned and postoperative chin segments, along with their interquartile range. It is noteworthy that, concerning translational assessment, the measured values remained clinically acceptable (<2mm) in all directions. However, in terms of rotational accuracy, the guided sample exhibited an interquartile range that exceeded the acceptable limits for pitch, measuring 3.26° (IQR 2.06 – 5.20°). Roll and yaw rotations remained within acceptable limits (<4°).

To interpret the differences obtained between the planned and achieved outcomes more specifically, differences were also measured considering the direction of the error, as illustrated in a box-plot graphic (Figures 4 and 5). It is important to note, however, that these values were not used to determine the accuracy of the techniques but rather to ascertain the error trend.

DISCUSSION

The chin repositioning is an important technique to achieve facial balance. However, some features of the surgery can difficult make adequate repositioning of the chin difficult, such as bone density, adequate visualization, and difficult bone repositioning[19].

The use of a surgical guide obtained through 3D-printing technologies has the potential to enhance intervention outcomes through three-dimensional simulation. Several researchers have published case reports and technical notes regarding guides for achieving an optimal chin position[19-25].

It is important to emphasize that there are two ways to analyze positional and rotational differences between planned and achieved bone segments. Results can be presented considering the direction of displacement (negative and positive values) or in absolute terms. It is crucial to note that, when analyzing only the directional mode, positive values could cancel out negative values, underestimating differences and potentially influencing the results. Thus, to assess the accuracy of a certain technique, it makes more

sense to use absolute values, reserving directional values solely to determine the trend of the error.

In this study, the guided proposal technique only displayed difference values exceeding accuracy limits in its pitch rotation, measuring 3.26° (IQR 2.06 – 5.20°), while all other directions and rotations were within the expected range ensured by the technique. When we examine the error trend, the direction of movement also indicate that the chins experienced a greater counterclockwise rotation than intended.

The increased imprecision in pitch, even with the use of guides, is consistent with previous findings. Li et al, in 2017[13], discussed two hypotheses for this. The first hypothesis to explain this phenomenon is that the repositioning guides are only applied to the buccal side of the chin segment. The retraction force of the soft tissue (mainly from the suprahyoid depressor muscles) is considerably large, causing the slim-designed repositioning guides slightly deformed. Although visually unnoticeable, the deformation of the repositioning guides may directly result in an unexpected posterior displacement and pitch rotation of the chin segment before the rigid fixation is applied. The second hypothesis is that the titanium genioplasty plate is not rigid enough to resist the retraction force from the suprahyoid depressor muscles after patient wakes up from general anesthesia. In addition to these two hypotheses, suboptimal pitch outcomes could potentially be influenced by factors such as internal bone contacts or the use of onlay bone grafts. To address this issue, guides made of more rigid materials or patient-specific implants could be utilized and tested.

Despite the slightly better results in achieving translational position and the suboptimal outcomes regarding pitch, the advantages offered by the use of guides should not be limited solely to accuracy. These guides assist the surgeon in avoiding contact with surrounding noble anatomical structures such as dental roots and the mental nerve. The design allows for minor incisions and less dissection to perform genioplasty, and the elimination of the need for repeated intraoperative measurements and visual assessments makes it possible for a less clinically experienced surgeon to achieve more ideal surgical outcomes.

CONCLUSIONS

The guided technique proved effective in achieving clinically acceptable accuracy in all directions and rotations except for pitch. To ensure the advantages offered by the guides and guarantee accuracy in all rotations, we suggest further research involving guides made of more rigid materials, as well as customized implants.

REFERENCES

1. Ward JL, Garri JI, Wolfe SA. The osseous genioplasty. Clin Plast Surg. 2007 Jul;34(3):485-500. doi: 10.1016/j.cps.2007.05.009. PMID: 17692706.
2. J.G. McCarthy, H.K. Kawamoto Jr., B.H. Grayson, et al. Surgery of the jaws. J.G. McCarthy (Ed.), Plastic Surgery, W.B. Saunders, Philadelphia (1990), pp. 1188-1200.
3. González-Ulloa MD. Quantitative principles in cosmetic surgery of the face (profileplasty). Plast Reconstr Surg Transplant Bull. 1962 Feb;29:186-98. doi: 10.1097/00006534-196202000-00006. PMID: 13900238.
4. Trauner R, Obwegeser H: The surgical correction of mandibular prognathism and retrognathia with consideration of genioplasty. I. Surgical procedures to correct mandibular prognathism and reshaping of the chin. Oral Surg Oral Med Oral Pathol 10(7): 677e689, 1957 contd.
5. 5. Oth O, Durieux V, Orellana MF, Glineur R. Genioplasty with surgical guide using 3D-printing technology: A systematic review. J Clin Exp Dent. 2020 Jan 1;12(1):e85-e92. doi: 10.4317/medoral.56145. PMID: 31976049; PMCID: PMC6969968.
6. Lee S, Kim BK, Baek RM, et al: Narrowing and lengthening genioplasty with pedicled bone graft in contouring of the short and wide lower face. Aesthetic Plast Surg 37:139, 2013.
7. Keyhan SO, Khiabani K, Hemmat S, et al: Zigzag genioplasty: A new technique for 3-dimensional reduction genioplasty. Br J Oral Maxillofac Surg 51:e317, 2013.
8. Wang LD, Ma W, Fu S, Zhang CB, Cui QY, Peng CB, Li M. Design and manufacture of dental-supported surgical guide for genioplasty. J Dent Sci. 2021

Jan;16(1):417-423. doi: 10.1016/j.jds.2020.07.017. Epub 2020 Aug 22. PMID: 33384829; PMCID: PMC7770303.

9. Xia JJ, Gateno J, Teichgraeber JF, Christensen AM, Lasky RE, Lemoine JJ, Liebschner MA. Accuracy of the computer-aided surgical simulation (CASS) system in the treatment of patients with complex craniomaxillofacial deformity: A pilot study. J Oral Maxillofac Surg. 2007 Feb;65(2):248-54. doi: 10.1016/j.joms.2006.10.005. PMID: 17236929.

10. Gateno J, Xia JJ, Teichgraeber JF, Christensen AM, Lemoine JJ, Liebschner MA, Gliddon MJ, Briggs ME. Clinical feasibility of computer-aided surgical simulation (CASS) in the treatment of complex cranio-maxillofacial deformities. J Oral Maxillofac Surg. 2007 Apr;65(4):728-34. doi: 10.1016/j.joms.2006.04.001. PMID: 17368370.

11. Hsu SS, Gateno J, Bell RB, et al. Accuracy of a computer-aided surgical simulation protocol for orthognathic surgery: a prospective multicenter study. J Oral Maxillofac Surg 2013;71:128e42.

12. Li Y, Jiang Y, Zhang N, Xu R, Hu J, Zhu S. Clinical feasibility and efficacy of using virtual surgical planning in bimaxillary orthognathic surgery without intermediate splint. J Craniofac Surg 2015;26:501e5.

13. Li B, Wei H, Zeng F, Li J, Xia JJ, Wang X. Application of A Novel Three-dimensional Printing Genioplasty Template System and Its Clinical Validation: A Control Study. Sci Rep. 2017 Jul 14;7(1):5431. doi: 10.1038/s41598-017-05417-7. PMID: 28710459; PMCID: PMC5511285.

14. Kang SH, Lee JW, Lim SH, Kim YH, Kim MK. Validation of mandibular genioplasty using a stereolithographic surgical guide: in vitro comparison with a manual measurement method based on preoperative surgical simulation. J Oral Maxillofac Surg. 2014 Oct;72(10):2032-42. doi: 10.1016/j.joms.2014.03.002. Epub 2014 Mar 13. PMID: 24780609.

15. Cevidanes LH, Bailey LJ, Tucker GR Jr, Styner MA, Mol A, Phillips CL, Proffit WR, Turvey T. Superimposition of 3D cone-beam CT models of orthognathic surgery patients. Dentomaxillofac Radiol. 2005 Nov;34(6):369-75. doi: 10.1259/dmfr/17102411. PMID: 16227481; PMCID: PMC3552302.

16. Shaheen E, Shujaat S, Saeed T, Jacobs R, Politis C. Three-dimensional planning accuracy and follow-up protocol in orthognathic surgery: a validation study. Int. J. Oral Maxillofac. Surg. 2019; 48(1): 71–6.

17. Li B, Zhang L, Sun H, Yuan J, Shen SG, Wang X. A novel method of computer aided orthognathic surgery using individual CAD/CAM templates: a combination of osteotomy and repositioning guides. Br J Oral Maxillofac Surg. 2013; 51(8): e239-44.

18. Stokbro K, Aagaard E, Torkov P, Bell RB, Thygesen T. Surgical accuracy of three-dimensional virtual planning: a pilot study of bimaxillary orthognathic procedures including maxillary segmentation. Int J Oral Maxillofac Surg. 2016; 45(1): 8-18.

19. Arcas A, Vendrell G, Cuesta F, Bermejo L. Advantages of performing mentoplasties with customized guides and plates generated with 3D planning and printing. Results from a series of 23 cases. J Craniomaxillofac Surg. 2018 Dec;46(12):2088-2095. doi: 10.1016/j.jcms.2018.09.018. Epub 2018 Sep 21. PMID: 30316655.22. Li B, Shen SG, Yu H, Li J, Xia JJ, Wang X. A new design of CAD/ CAM surgical template system for two-piece narrowing genioplasty. Int J Oral Maxillofac Surg. 2016;45:560 6.

20. Liu SY, Huon LK, Zaghi S, Riley R, Torre C. An Accurate Method of Designing and Performing Individual-Specific Genioglossus Advancement. Otolaryngol Head Neck Surg. 2017 Jan;156(1):194-197. doi: 10.1177/0194599816670366. Epub 2016 Oct 22. PMID: 28045634.

21. J, Fu X, Gui L, Girod S, Lee GK, Niu F, Liu J. Computer Image-Guided Template for Horizontal Advancement Genioplasty. J Craniofac Surg. 2016 Nov;27(8):2004-2008. doi: 10.1097/SCS.0000000000003093. PMID: 28005743.

22. Yamauchi K, Yamaguchi Y, Katoh H, Takahashi T. Tooth-bone CAD/CAM surgical guide for genioplasty. Br J Oral Maxillofac Surg. 2016 Dec;54(10):1134-1135. doi: 10.1016/j.bjoms.2016.03.012. Epub 2016 Mar 26. PMID: 27025234.

23. Oth O, Orellana MF, Glineur R. The Minimally Invasive-Guided Genioplasty Technique using Piezosurgery and 3D printed surgical guide: An innovative technique. Ann Maxillofac Surg. 2020 Jan-Jun;10(1):178-181. doi: 10.4103/ams.ams_78_19. Epub 2020 Jun 8. PMID: 32855936; PMCID: PMC7433983.

24. Macedo DV, Monnazzi MS, de Almeida MS, Claus JDP. A novel guide for minimally invasive genioplasty. Oral Maxillofac Surg. 2022 Jul 23. doi: 10.1007/s10006-022-01102-w. Epub ahead of print. PMID: 35869351

25. Aragón-Niño Í, Moreiras-Sanchez ÁD, Del Castillo-Pardo de Vera JL, Pampín-Martinez MM, Barajas-Blanco M, Cebrián-Carretero JL. 3D designed in-house positioning and cutting guide system for genioplasty surgery. Technical note and case report. J Clin Exp Dent. 2023 Oct 1;15(10):e870-e873. doi: 10.4317/jced.60896. PMID: 37933394; PMCID: PMC10625682.

TABLES

Table 1

Table 1 – Chin Accuracy. UK, 2023

Delta	Axis	Median	Minimum	Maximum	IQR
Linear (mm)	Transversal	0,43	0,01	1,70	0,23 – 0,68
	Sagital	1,24	0,07	3,11	0,36 – 1,65
	Vertical	0,85	0,10	3,20	0,46 – 1,90
Angular (**°**)	Roll	1,16	0,13	4,61	0,84 – 1,95
	Pitch	3,26	0,61	11,10	2,06 – 5,20
	Yaw	2,40	0,25	3,87	1,29 – 3,39

IQR: Turkey's Hinges interquartile range

FIGURES

Figure 1

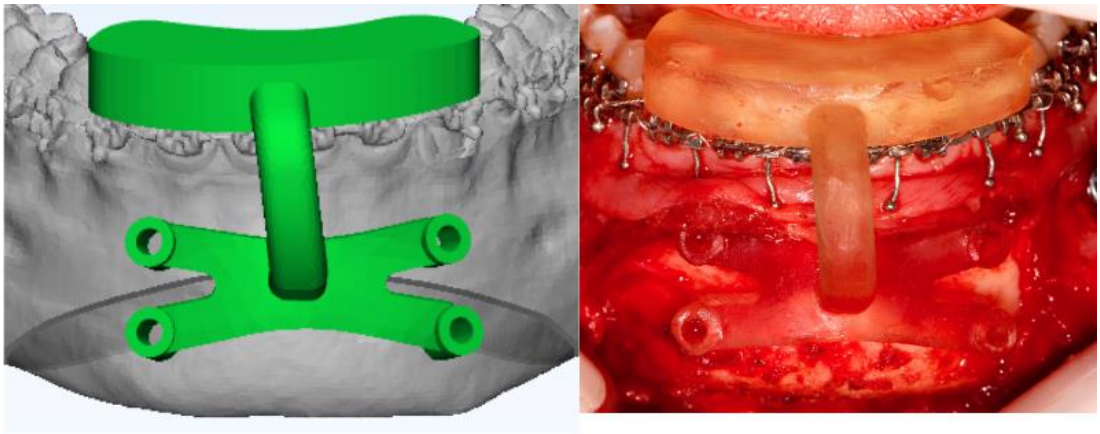

Fig1.: Drilling guide, design and surgical application.

Figure 2

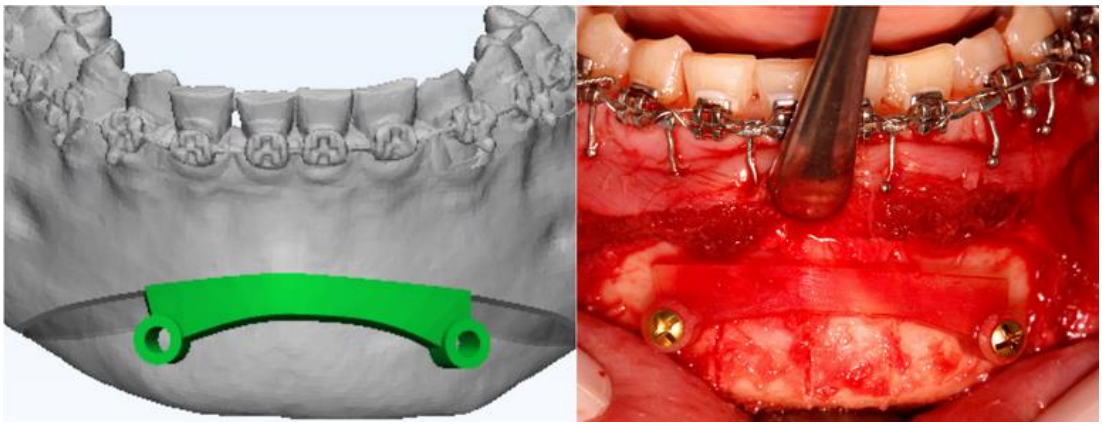

Fig1.: Cutting guide, design and surgical application.

Figure 3

Fig3.: Positioning guide, design and surgical application.

Figure 4

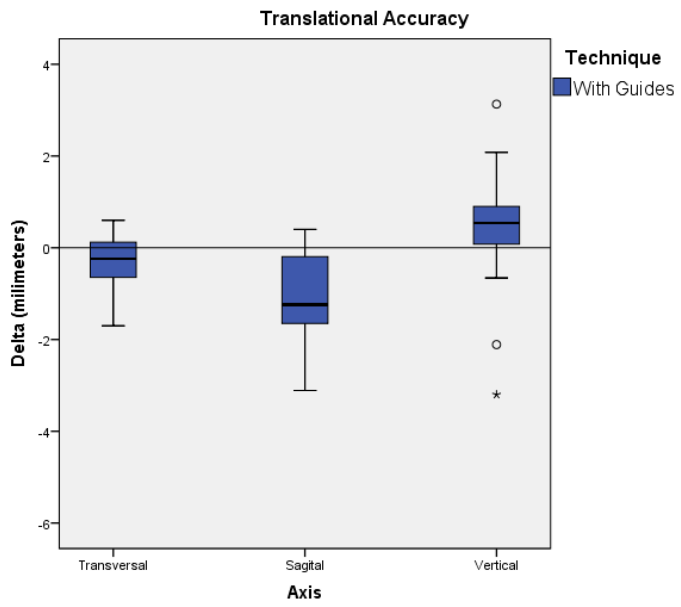

Fig. 4: Box-plot graphic showing trend error of translational accuracy through unsigned analysis.

Figure 5

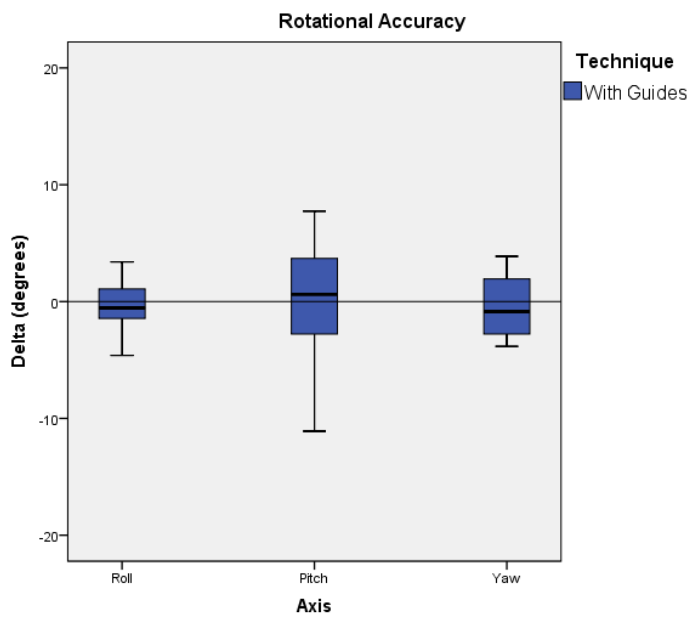

Fig. 5: Box-plot graphic showing trend error of rotational accuracy through unsigned analysis.