IBRA case study

Arthroscopically assisted open reduction and internal fixation (AORIF) of ankle fractures

Authors

Dr. Patrick Pflüger, Prof. Dr. Dr. Victor Valderrabano

Keywords

Ankle fractures, ORIF, arthroscopy, deltoid ligament, syndesmotic injury

Summary

Ankle fractures are one of the most common skeletal injuries in adults. In unstable fractures open reduction and internal fixation (ORIF) is performed to restore ankle function and preventing post-traumatic osteoarthritis (PTOA). However, the functional long-term results after ORIF of unstable ankle injuries are often not satisfactory despite an anatomical reduction. Concomitant pathologies such as syndesmotic injuries, cartilage lesions, and deltoid ligament damages can significantly worse patient outcome. Arthroscopically assisted open reduction and internal fixation (AORIF) of ankle fractures allows the diagnosis and treatment of these concomitant injuries.

Introduction

Ankle fractures are one of the most common skeletal injuries and an operative treatment is usually indicated in displaced, unstable fractures [1]. Open reduction and internal fixation (ORIF) is performed to restore the anatomy and ankle joint function, aiming to prevent post-traumatic osteoarthritis (PTOA) [2, 3]. However, the functional long-term results after ORIF of unstable ankle injuries are often not satisfactory despite an anatomical reduction [4]. In particular, ankle fractures that involve the posterior malleolus and/or have concomitant syndesmotic and cartilage injuries may result in inferior outcomes [2, 5-10]. Preoperative imaging with computed tomography (CT) and magnetic resonance imaging (MRI) can visualize exact fracture configuration and ligamentous status respectively. But the sensitivity of an MRI to detect chondral lesions of the ankle joint is only moderate and its practical use limited due to costs and convenience [11]. In contrast, cartilage lesions or lose intra-articular bodies are

common in ankle sprains with syndesmotic injuries and are present in up to 91% of all unstable ankle fractures [7, 12].

Arthroscopically assisted open reduction and internal fixation (AORIF) of ankle fractures allows the diagnosis and treatment of these concomitant injuries [13]. The ligamentous status can be assessed during stress tests, osteochondral lesions can be visualized, the reduction evaluated (e.g. following syndesmotic fixation) and the intra-articular hematoma rinsed [14]. Despite the potential benefits of AORIF there are only a few studies demonstrating superiority of the arthroscopically assisted surgery [7, 15]. Further studies are necessary to provide more evidence in which cases AORIF is beneficial for the outcome and to derive a treatment algorithm.

Case Presentation

A 70-year-old male patient was referred to the outpatient clinic for further treatment of a distal fibular fracture. The patient reported that he had stepped into a hole on a stage and twisted his left ankle. After confirming the diagnosis, a lower leg walking boot and crutches with partial weight bearing was prescribed by the local doctors.

In the clinical examination, five days after trauma, the soft tissue swelling already declined. A hematoma was present at the lateral distal fibula as well as on the medial side. Palpation revealed pain at the distal fibular and deltoid ligament. The range of motion was limited due to pain. The x-ray and computed tomography (CT) showed a displaced trans-syndesmotic fibular fracture (Weber type B) with a widened medial clear space (Fig. 1). Due to the fracture configuration and patient's functional demand (active, professional musician) operative treatment was indicated.

Management and Outcome

Surgery was performed six days after trauma in regional anesthesia. Patients was placed in supine position and a femoral tourniquet was applied. Diagnostic arthroscopy was performed first to evaluate the syndesmotic complex, deltoid ligament and chondral status. The portal was placed between tibialis anterior and extensor hallucis longus tendon. After blunt extension of the portal, the trocar was inserted in dorsal extension. There was no acute osteochondral lesion (OCL) of the ventral talocrural joint. The medial ligamentous apparatus was injured with a corresponding hematoma (Fig. 2A-C). On the lateral side, the displaced fibula fracture and hematoma were visible. Dynamic testing (syndesmosis test; varus/valgus stress test; drawer test) confirmed medial ankle joint instability during eversion stress test.

After diagnostic arthroscopy, a lateral approach to the fibula was performed. The fibular fracture was displaced and shortened. Anatomic reduction and temporary fixation were accomplished with a with small pointed reduction forceps. A 3.5 lag screw was inserted anterior to posterior for compression of the fracture. Afterwards, an anatomically preformed, polyaxial-locking plate was placed on the lateral side of the distal fibula (Trilock distal fibula plate 2.8/3.5, Medartis, Basel, CH). The plate position, screw length and reduction were verified with intraoperative fluoroscopy. After thoroughly rinsing the lateral wound was closed and a medial approach to the medial ligamentous apparatus with arthrotomy was performed. The deltoid ligament complex showed a lesion of the ventral upper part. An absorbable suture (Vicryl 2.0) was used for the ligament repair (Fig. 2D-E). Final examination showed a good medial tension and stability with a recentered talus in intraoperative fluoroscopy.

The patient was advised to partially weight-bear with crutches for six weeks in a walking boot. Routine postoperative clinical and radiographic control showed a satisfactory result after six weeks (Fig. 3).

Discussion

Arthroscopy as adjunct procedure to ORIF offers additional diagnostic and treatment options to improve outcome. In the presented case study arthroscopy was used to verify the clinically and radiographically suspected deltoid lesion as well as to confirm medial instability. Furthermore, the cartilage and syndesmotic complex was assessed to rule out concomitant injuries that can influence outcome.

Intra-articular pathologies are common in ankle fractures and involve injuries to the syndesmotic complex, cartilage damages, deltoid ligament tears and lose bodies [16, 17]. In preoperative imaging conventional radiographs cannot reliably predict syndesmotic injuries [18]. MRI allows the best non-invasive assessment of the syndesmotic complex with a high sensitivity and specificity, but there are some practical limitations in clinical application. Weight-bearing CT is another option, if available and tolerated by the patient in acute injuries [18]. Arthroscopy offers the possibility to serve as a diagnostic tool and furthermore to evaluate directly the quality of reduction intraoperatively [17]. In particular, since intraoperative fluoroscopy lacks to reliably asses syndesmotic reduction and a malreduction can significantly worse functional outcome [19, 20].

Stufkens et al demonstrated in 288 ankle fractures, that a cartilage damage is an independent predictor of the development of PTOA [2]. In unstable ankle fractures cartilage lesions are present in up to 91% of all patients [8]. The sensitivity of an preoperative MRI to detect

chondral lesions of the ankle joint is moderate and there are limitations in its practicality because of cost and convenience [11]. Arthroscopy provides a reliable assessment of osteochondral lesions of the ankle joint and depending on the type of OCL an immediate therapy or postoperative regimen adjustment [17]. Besides the direct lesion to the cartilage, initial inflammatory response may lead to synovial catabolism and cartilage degradation over time, resulting in a short latency between intra-articular fracture and PTOA [21, 22]. During arthroscopy the joint is thoroughly rinsed, removing the intra-articular hematoma and possibly contributing to a better recovery.

Lesions of the deltoid ligament complex are common among ankle fractures and can occur especially in trans-syndesmotic fibular fractures [23]. The deep layer of the deltoid complex is an important stabilizer of the loaded ankle, restraining the talus from external rotation [24]. Diagnosis of medial ligament injuries can be challenging and there are several diagnostic modalities [25]. Clinical signs such as ecchymosis and tenderness are not reliable indicators for deep deltoid ruptures [26]. Gravity stress radiography or weight-bearing radiographs are easy, widely used and more reliable methods to assess medial instability. Arthroscopy can be of value by directly visualizing the deep layers of the deltoid ligament complex and therefore confirming the diagnosis in cases of doubt [25]. The optimal treatment of deltoid lesions in acute ankle fractures is discussed controversially and there is no accepted guideline [27, 25]. Patients with high fibular fractures or concomitant syndesmotic injuries may benefit from repair by suture of the deltoid ligament, but future studies need to provide more evidence to derive clear indications [27].

Arthroscopically assisted open reduction and internal fixation (AORIF) offers potential benefits for the operative treatment of ankle fractures, but the indication for arthroscopy in ankle fracture treatment is still surgeon dependent. Especially due to the regular occurrence concomitant injuries in ankle fractures, patients can benefit from arthroscopy as an adjunct procedure.

Acknowledgements

I would like to thank IBRA for supporting my fantastic visit to Prof. Valderrabano and his team at the SWISS ORTHO CENTER Basel as well as the Privatklinik Obach.

References

1. Court-Brown CM, Caesar B. Epidemiology of adult fractures: a review. Injury. 2006;37(8):691-7.

2. Stufkens SA, Knupp M, Horisberger M, Lampert C, Hintermann B. Cartilage lesions and the development of osteoarthritis after internal fixation of ankle fractures: a prospective study. JBJS. 2010;92(2):279-86.
3. Bugler K, White T, Thordarson D. Foot & Ankle: Focus On Ankle fractures. JBJS. 2012;94:1107.
4. Stufkens SA, van den Bekerom MP, Kerkhoffs GM, Hintermann B, van Dijk CN. Long-term outcome after 1822 operatively treated ankle fractures: a systematic review of the literature. Injury. 2011;42(2):119-27.
5. Rammelt S, Bartonícek J. Posterior Malleolar Fractures: A Critical Analysis Review. JBJS reviews. 2020;8(8):e19.
6. Toth MJ, Yoon RS, Liporace FA, Koval KJ. What's new in ankle fractures. Injury. 2017;48(10):2035-41.
7. Baumbach SF, Urresti-Gundlach M, Braunstein M et al. Propensity Score–Matched Analysis of Arthroscopically Assisted Ankle Facture Treatment Versus Conventional Treatment. Foot Ankle Int. 2020:1071100720969609.
8. Braunstein M, Baumbach SF, Urresti-Gundlach M, Borgmann L, Böcker W, Polzer H. Arthroscopically assisted treatment of complex ankle fractures: intra-articular findings and 1-year follow-up. The Journal of Foot and Ankle Surgery. 2020;59(1):9-15.
9. Fuchs DJ, Ho BS, LaBelle MW, Kelikian AS. Effect of arthroscopic evaluation of acute ankle fractures on PROMIS intermediate-term functional outcomes. Foot Ankle Int. 2016;37(1):51-7.
10. Leontaritis N, Hinojosa L, Panchbhavi VK. Arthroscopically detected intra-articular lesions associated with acute ankle fractures. JBJS. 2009;91(2):333-9.
11. Regier M, Petersen JP, Hamurcu A et al. High incidence of osteochondral lesions after open reduction and internal fixation of displaced ankle fractures: medium-term follow-up of 100 cases. Injury. 2016;47(3):757-61.
12. Rellensmann K, Behzadi C, Usseglio J et al. Acute, isolated and unstable syndesmotic injuries are frequently associated with intra-articular pathologies. Knee Surg Sports Traumatol Arthrosc. 2021;29(5):1516-22.
13. Braunstein M, Baumbach S, Böcker W, Mutschler W, Polzer H. Arthroscopically assisted treatment of ankle fractures. Der Unfallchirurg. 2016;119(2):92-8.
14. Williams CE, Joo P, Oh I, Miller C, Kwon JY. Arthroscopically Assisted Internal Fixation of Foot and Ankle Fractures: A Systematic Review. Foot & ankle orthopaedics. 2021;6(1):2473011420950214.
15. Duramaz A, Baca E. Microfracture provides better clinical results than debridement in the treatment of acute talar osteochondral lesions using arthroscopic assisted fixation of acute ankle fractures. Knee Surg Sports Traumatol Arthrosc. 2018;26(10):3089-95.
16. Howard S, Hoang V, Sagers K, Brady C, Eudy A, Watson TS. Identifying Intra-Articular Pathology With Arthroscopy Prior to Open Ankle Fracture Fixation. Arthroscopy, sports medicine, and rehabilitation. 2021;3(1):e177-e81.
17. Chan KB, Lui TH. Role of ankle arthroscopy in management of acute ankle fracture. Arthroscopy: The Journal of Arthroscopic & Related Surgery. 2016;32(11):2373-80.
18. Krähenbühl N, Weinberg MW, Davidson NP et al. Imaging in syndesmotic injury: a systematic literature review. Skeletal Radiol. 2018;47(5):631-48.
19. Gardner MJ, Demetrakopoulos D, Briggs SM, Helfet DL, Lorich DG. Malreduction of the tibiofibular syndesmosis in ankle fractures. Foot Ankle Int. 2006;27(10):788-92.
20. Sagi HC, Shah AR, Sanders RW. The functional consequence of syndesmotic joint malreduction at a minimum 2-year follow-up. J Orthop Trauma. 2012;26(7):439-43.
21. Swärd P, Struglics A, Englund M, Roos HP, Frobell RB. Soft tissue knee injury with concomitant osteochondral fracture is associated with higher degree of acute joint inflammation. The American journal of sports medicine. 2014;42(5):1096-102.

22. Pham TM, Frich LH, Lambertsen KL, Overgaard S, Schmal H. Elevation of inflammatory cytokines and proteins after intra-articular ankle fracture: a cross-sectional study of 47 ankle fracture patients. Mediators Inflamm. 2021;2021.
23. Hintermann B, Regazzoni P, Lampert C, Stutz G, Gächter A. Arthroscopic findings in acute fractures of the ankle. The Journal of bone and joint surgery British volume. 2000;82(3):345-51.
24. Michelson JD, Waldman B. An axially loaded model of the ankle after pronation external rotation injury. Clinical Orthopaedics and Related Research®. 1996;328:285-93.
25. Stufkens SA, van den Bekerom MP, Knupp M, Hintermann B, van Dijk CN. The diagnosis and treatment of deltoid ligament lesions in supination–external rotation ankle fractures: a review. Strategies in trauma and limb reconstruction. 2012;7(2):73-85.
26. DeAngelis NA, Eskander MS, French BG. Does medial tenderness predict deep deltoid ligament incompetence in supination-external rotation type ankle fractures? J Orthop Trauma. 2007;21(4):244-7.
27. Dabash S, Elabd A, Potter E et al. Adding deltoid ligament repair in ankle fracture treatment: Is it necessary? A systematic review. Foot Ankle Surg. 2019;25(6):714-20.

Figures

Fig. 1. AP and lateral weightbearing X-ray of the patient's left ankle showing the displaced trans-syndesmotic fibular fracture (Weber type B).

Fig. 2. Intraoperative Images. (A) Arthroscopic view of the injured medial ligamentous apparatus with a corresponding hematoma. (B) Medial approach showing the injured deltoid ligament (left side of the picture → medial malleolus/proximal). (C) After removing the superficial layer the lesion of the ventral upper part of the deltoid complex was visible. (D) Ligament repair with an absorbable suture (Vicryl 2.0). (E) Final result after direct ligament repair with good medial tension.

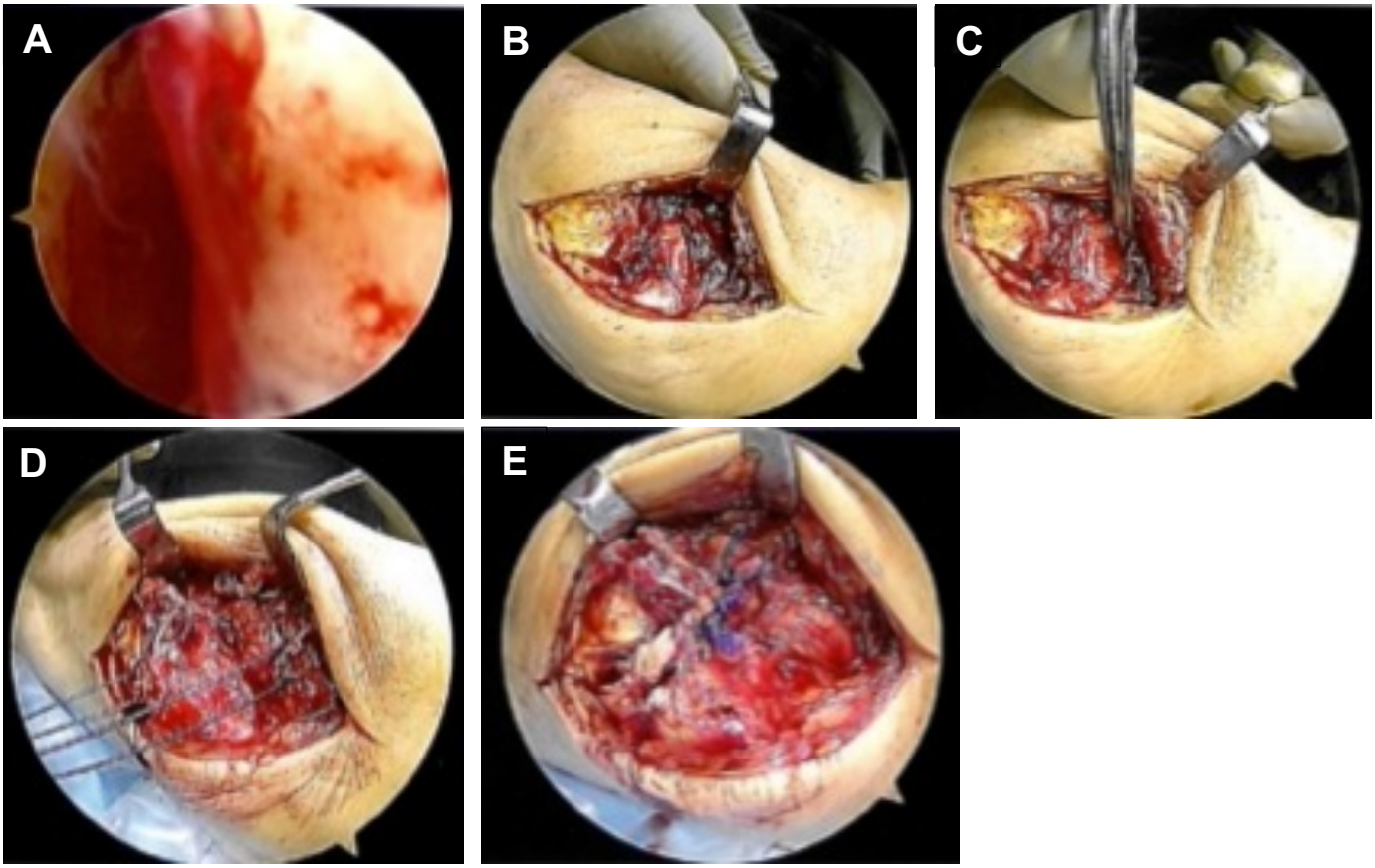
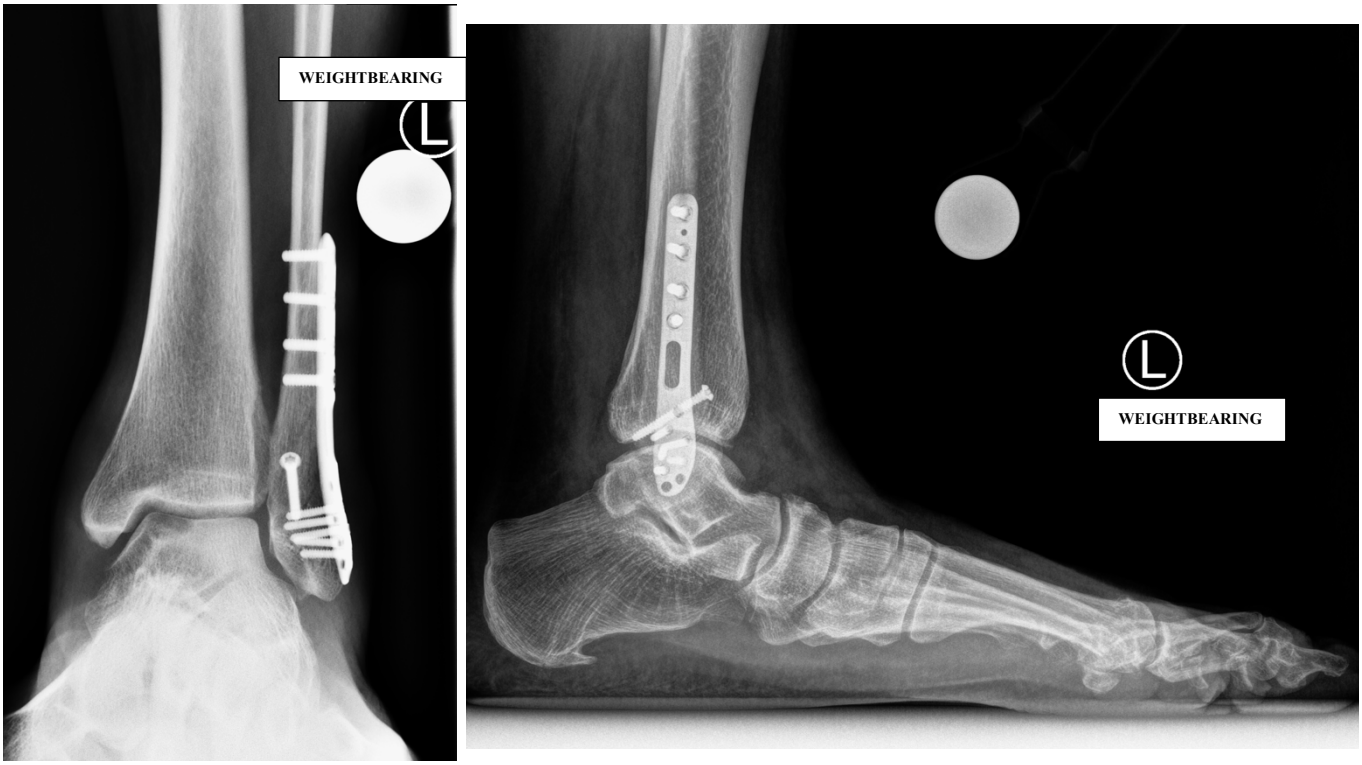
Fig. 3. Postoperative x-rays six weeks after surgery showing a satisfactory result with stable anatomic reduction and correct positioning of the plate.