Radiological parameters outcomes in open reduction and internal fixation of distal radius fractures. A case series study.

Rodríguez, Estanislao M.D.[1]; Badia, Alejandro M.D.[2]

[1] Dr. Rodriguez, Estanislao M.D. from Argentina, actually in 3rd year of Orthopedics and traumatology residency, at "Hospital Provincial Centenario", Rosario city, Argentina.
Scholar during IBRA 2019 scholarship program for clinical residential stay at Badia Hand to Shoulder Center, Doral, FL, US.

[2] Dr. Badia, Alejandro M.D, F.A.C.S. hand and upper limb surgeon. Creator and founder of Badia Hand to Shoulder Center, Doral, FL, US.

Background: Distal radius fractures represent a frequent orthopedic injury, 20% of the fractures seen in the emergency room. Regardless of the treatment choice, the basis for enhanced outcomes are the restoration of wrist anatomy, stable fixation, bone fragments vascularity preservation and promote early mobilization. The objective of this study is to analyze the radiographic parameters achieved through volar plating in distal radius fractures, in order to understand the reliability of this method in the restoration of normal morphology.

Method: In this case series, preoperative and postoperative radiological parameters of 7 patients with distal radius fracture were measured, analyzed and compared. Radial inclination, ulnar variance and radial tilt were considered. All patients underwent surgery for open reduction and internal fixation with locking volar plates.

Results: 81% of the parameters were improved and reached the normal values after surgery. 19% of the measurements were not restored to normal ranges due to significant preoperative alterations and probably anatomic variation.

Conclusions: Till nowadays the treatment continues to evolution, with a wide range of options for the fracture stabilization. Radial inclination, ulnar variance and radial tilt were restored after open reduction and internal fixation with locking volar plates. This technique warranties a safer option in the management and restoration of the distal radius anatomy.

I N T R O D U C T I O N

The fractures of the distal radius are one of the most frequent traumas, and represent a 20% of the fractures seen in the emergency room.

Due to multifactorial etiology, incidence appears to be raising in the lasts years in all ages[1]: in young population it is mostly related to car accidents; while in the elderly people, some of the principals responsible factors are longer life expectancy, activity increase and bone mineral density changes [2].

These injuries have been studied for more than 200 years, even before of radiology advent, since Claude Pouteau (1783), Abraham Colles (1814), Rhea Barton (1838), Robert Smith (1847) and Dupuytren (1847) classical descriptions, where distal radius fractures were expected to present acceptable outcomes, independently from the treatment method [3,4]. Till nowadays the treatment continues to evolution, with a wide range of options for the fracture stabilization: Nonoperative treatment, K-Wires, external fixation, open reduction and internal fixation and a broad range of implants [5,6,7,8].

From volar plate appearance onward and posterior volar angular stable plate osteosynthesis and locking screws development, open reduction with internal fixation has raised its popularity between surgeons as it allows early mobilization, reports low complication rates and reaches better anatomic and functional outcomes [9,10,11].

Plates are intended for osteosynthesis of intra-articular and extra-articular fractures of the distal radius on the volar side. The aim of osteosynthesis is the reconstruction of the articular surface, stable fixation of fragments, and restoration of radial length and angle.

Regardless of the treatment choice, the bases for enhanced outcomes are the restoration of wrist anatomy, stable fixation, bone fragments vascularity preservation and promote early mobilization. It seems vital to avoid vicious consolidation with angular alterations and shortening as it would result in multiple functional disorders [12].

Anatomy

The distal forearm may be thought of in terms of three columns, that supports the carpal bones and the hand (Figure 1):
First, a radial column that comprise the lateral side of the bone, including the radial styloid process and the scaphoid facet; Second, the intermediate column conformed by the ulnar side of the radius, including lunate facet and sigmoid notch; Finally, the third column is the ulnar column integrated by the ulnar head, the triangular fibrocartilage complex (TFCC) and the ulnar aspect of the distal radioulnar joint [13].

Distally at the wrist joint, the radial column articulates with the scaphoid and the intermediate column articulates with the lunate and axial loads are 80% distributed in the radius and 20% in the ulnar side [14].

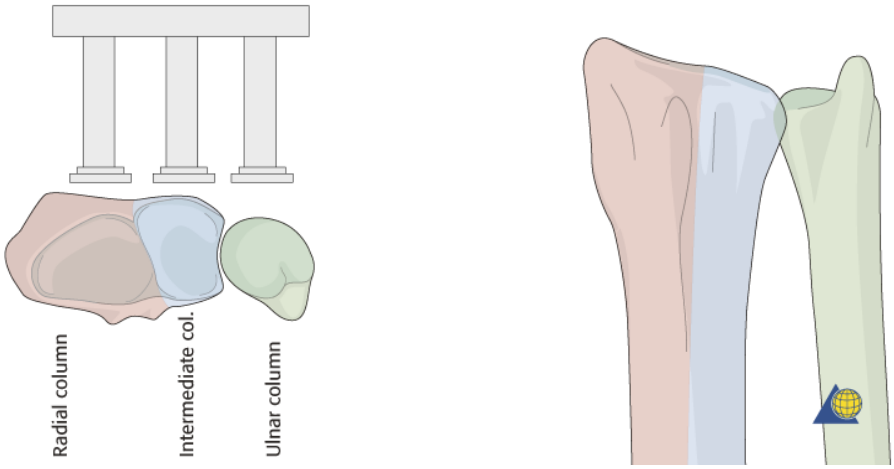

Figure 1. Columns of the distal radius. (Extracted from https://www2.aofoundation.org/)

There are many reports in the literature on the relationship between radiographic variables and their influence on the final outcome of distal radius fractures. Most authors report that a good functional result depends on anatomical restoration of the articular surface and extra-articular alignment. Radial length is considered as an important prognostic factor[15, 16] because its shortening can cause painful range of motion limitation due to distal radioulnar joint incongruence, TFCC impactation and ulnar head subdislocation, therefore, increasing risk of ulnocarpal osteoarthritis[17].

Radiological measurements

Radial tilt / palmar tilt (RT)

Radial tilt is measured on a lateral radiograph. The radial tilt represents the angle between a line along the distal radial articular surface and the line perpendicular to the longitudinal Axis of the radius at the joint margin. The normal palmar tilt averages 11-12 degrees and has a range of 2-20 degrees (Figure 2).

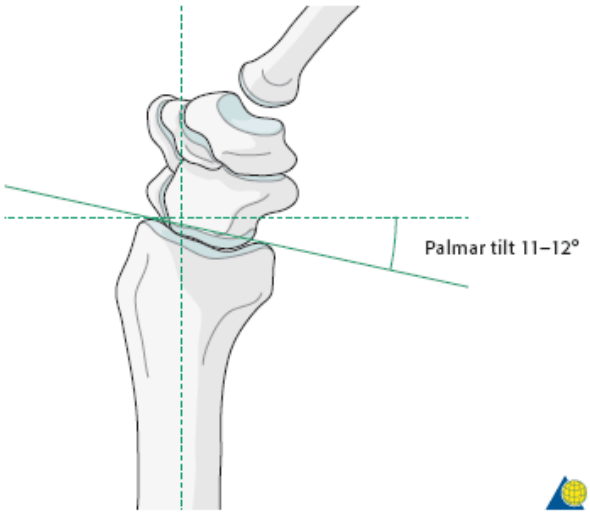

Figure 2. Radial tilt. (Extracted from https://www2.aofoundation.org/

Radial inclination or angle (RI)

Radial inclination represents the angle between one line connecting the radial styloid tip and the ulnar aspect of the distal radius and a second line perpendicular to the longitudinal axis of the radius. The radial inclination averages between 21 and 25 degrees and has a range of 15-35 degrees. Loss of radial inclination will increase the load across the lunate (Figure 3).

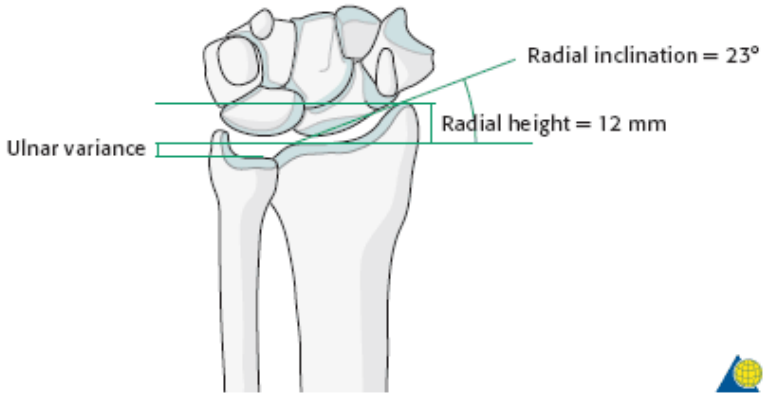

Figure 3. Radial inclination, ulnar variance and radial height. (Extracted from https://www2.aofoundation.org/).

Radial length or height

Radial length is measured on the PA radiograph as the distance between one line perpendicular to the long axis of the radius passing through the distal tip of the radial styloid. A second line intersects distal articular surface of ulnar head. This measurement averages 10-13 mm (Figure 3).

Ulnar variance (UV), also known as **Hulten variance**

Ulnar variance	
Neutral	0 +/- 2mm (length difference < / = 2mm)
Positive (ulna projects distally)	> 2mm
Negative (ulna projects proximally)	< 2mm

Table 1. Ulnar variance values.

Ulnar variance refers to the relative lengths of the distal articular surfaces of the radius and ulna (Figure 3). Variance is independent of the length of the ulnar styloid process. It results from the distance between two perpendicular lines to the long axis of the radius. On the radial side a perpendicular line to the long axis is drawn through the ulnar limit of the radius. To do that, a middle point between the dorsal and palmar limit of the ulnar edge of

the radius is set. On the ulnar side, a perpendicular line to the radial long axis is drown at the level of articular surface of the ulnar head [18, 19].

Malalignment determines range of motion limitation [20], loss of fist strength, changes in loads distribution [21], midcarpal instability [22] and a major risk of radiocarpal post traumatic osteoarthritis. Moreover, anatomical reduction and stabilization of intrarticular fractures are essential because of the functional implications of the involvement of the distal radioulnar joint.

Accordingly, it keeps continuing awaking interest to study the anatomy and the effectiveness of the different treatment methods. As said, nowadays ORIF appears to be the most trending option for the distal radius fracture management. Thus the aim of this study is to analyze the radiographic parameters achieved through volar plating in distal radius fractures.

M E T H O D

This case series is an observational, descriptive, cross-sectional, retrospective study performed in the context of an observership, during a three month scholarship taken place in an upper limbs center in Miami, FL, USA; from October 2019 to January 2020.

Radiographic outcomes of distal radius fractures treated with volar plates were measured in this study. All distal radius fractures turned up in the time of the observership were evaluated.

The following criterion was considered for the recruitment:

Inclusion criteria:

- Over 18 years old.
- Distal radius fractures.
- Intrarticular and extrarticular fractures.
- Patients who accomplished X-rays follow up.
- Patients treated with open reduction and internal fixation with a volar plate for distal radius fracture.

Exclusion criteria:

- Under 18 years old.
- Open fractures.

Accordingly to this criterion, 7 patients were included, and following variables were taken into account:

- Gender: Female / Male
- Age: over 18 years old.
- Etiology: mechanism described by the patient.
- Fracture type: AO / OTA classification was considered (Table 2) [23]
- Preoperative (PRE) and postoperative (POP) X-ray measurements: A-P and lateral incidences were performed before and after surgery in the same X-ray room, located at the upper limbs center. Radial inclination, radial tilt and ulnar variance were measured.
- Time interval between injury and surgery: measured in days. All surgeries were performed by the same upper limbs surgery specialist in the same operating room located at the same building as the clinic.

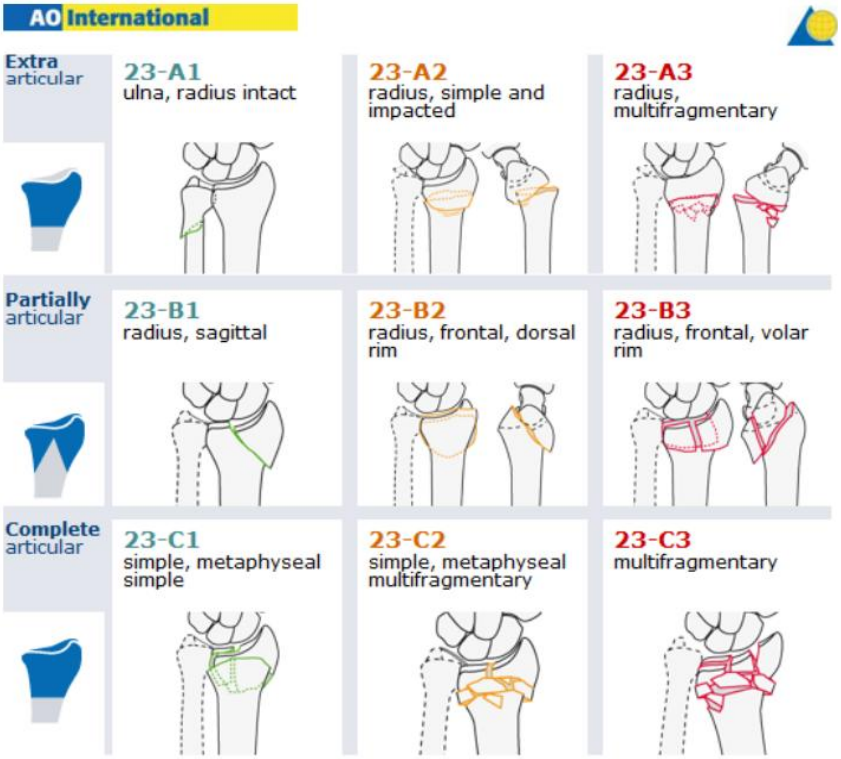

Table 2. AO distal radius classification (Extracted from https://www2.aofoundation.org/).

Technique *Open reduction and internal fixation (ORIF)*

With the patient in supine position under regional block, a non sterile pneumatic tourniquet is used, with the forearm extended in the hand table. Complete imaging assistance with fluoroscopy was carried on during the surgery.

Following the modified Henry approach the fracture was exposed. Surgical gestures for soft tissues and technique pearls are not described for the actual article. Reduction was performed under direct vision and assisted with fluoroscopy. Then, the locking volar plate is positioned suitably 2mm proximal to de watershed line, and secured to the proximal fragment while distal is reduced to it with traction and direct manipulation. This maneuver facilitates obtaining the correct volar tilt [24]. A different strategy is to attach the plate to the distal fragment first and then lever the distal fragment into correction relying on the variable angle fixation. Plate size, placement, screw length and subcondral positioning is checked under fluoroscopy.

Figure 4. Modifyed Henry approach

Figure 5. Lateral view control with fluoroscopy

Once intraoperative assessment is satisfactory, washing and wound closure is followed to finish the procedure.

Post operative cares, immobilization and rehabilitation is not taken into account in this study, as it is focused in the early anatomy restoration after ORIF.

The implant options run from volar locking plate with variable angle or fixed angle. Decision lays down on surgeon preference and it is made depending on fracture morphology and technical issues.

Figure 6. Distal Radius Volar Plate (Extracted from https://www.medartis.com/)

R E S U L T S

Of 7 patients, 2 were male (29%) and 5 female (71%). The average age found was 64 years old (from 54 to 79).

Regarding etiology, 4 (58%) were due to fall from own height, 2 (28%) from one step height and 1 (14%) for fall from bicycle. All of those were interpreted as low to mid energy mechanism according to how the patients described the moment of injury.

According to AO fracture classification, 5 patients (71%) presented type “A” extra articular fractures and 2 patients (29%) presented “C” complete articular fractures (Table 3).

As expected, both complex and complete articular fractures correspond to higher energy trauma, one falling from the first step of a stair and the other falling from a bicycle.

Patient	Gender	Age	Etiology	Days waited for surgery	AO Classification
1	F	79	Own height	5	2R3 A2,1
2	M	66	Own height	4	2R3 A3,3
3	F	73	Own height	1	2R3 A2,3
4	F	63	Fall from 1st stair step	1	2R3 A2,1
5	F	64	Own height	2	2R3 A2,1
6	F	54	Fall from bicycle	5	2R3 C1,2
7	M	55	Fall from 1st stair step	1	2R3 C1,2

Table 3. Fractures classification and epidemiology.

The average interval between trauma and surgery was 2,7 days (range from 5 to 1 day).

Radiographic outcomes

Preoperative and postoperative radiographic measurements were accomplished in all patients and are shown in the Table 4, which permitted to analyze the average values.

Patient	RI PRE	RI POP	UV PRE	UV POP	RT PRE	RT POP
1	16	26	-3,3	-2	9	6
2	9	16	3,2	0	-25	11
3	4	18	4	2	1	1
4	21	25	1,5	1	3	11
5	20	20	1,2	0	4	1
6	14	17	-3	-2,9	-15	3
7	28	25	-3	-2,7	-7	1

Table 4. Preoperative (PRE) and postoperative (POP) radiographic measurements. (Radial inclination, RI; Ulnar variance, UV; Radial tilt, RT)

The average magnitude of the correction for RI was of 5° where the biggest correction in this topic was of 10°. UV average was improved in 1,2 mm. Two patients with significant UV alteration did not reach normal ranges, remaining 0,9mm and 0,7mm extra variance. The best correction scored 3,2 mm. Finally, average correction of the RT was 9°, with its biggest correction in patient n°2 who was improved from -25° to 11° (Table 5).

Average measurements	Normal values	Preoperative (PRE)	Postoperative (POP)	Correction
Radial inclination (RI)	23	16	21	5
Ulnar variance (UV)	0	2,74	1,5	1,24
Radial tilt (RT)	11	-4,2	4,8	9

Table 5.Outcomes: Average measurements.

81% of parameters were found between acceptable ranges after surgery, from which 72% were enhanced from major alterations and 9% were maintained in the same acceptable values presented before surgery, not requiring further alignment. Not restored parameters

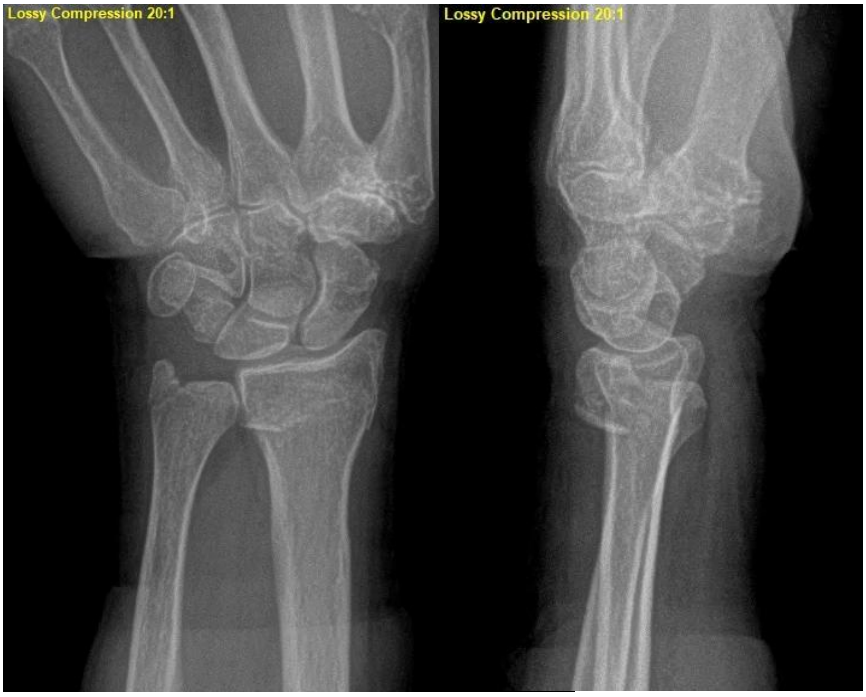

Figure 7. Preoperative X-Rays

Figure 8. Post operative X-Rays

represent a 19%, and it includes 2 UV and 2 RT with significant improvements, but still not reaching the normal range due to excessive preoperative alteration and maybe to anatomical variances as well. RI parameter was within the normal range in 100% of postoperative measurements (Table 6).

Restoration	RI	UV	RT	TOTAL	Average restoration
Yes	6	5	4	15	72%
No changes	1	0	1	2	9%
Insufficient	0	2	0	2	9%
No	0	0	2	2	9%
Acceptable	100%	72%	72%	17	81%
Not acceptable	0%	28%	28%	4	19%

Table 6. Shows the numer of X-ray parameters that were changed in surgery. YES: When restoration to normal values was made; NO CHANGES: When the was no changes on the parameter but was within the normal ranges; INSSUFFICIENT: Values were improved but still under acceptable ranges. NO: the parameter was not improved. ACCEPTABLE: Measurements withing the normal range (YES + NO CHANGES) NOT ACCEPTABLE: Measurements outside normal range (INSSUFFICIENT + NO)

D I S C U S S I O N

There is currently no definitive consensus about which is the best treatment for each type of distal radius type[25]. However, there was a paradigm shift since volar plates introduction and its progressive evolution [26].

K-wire fixation is a classic option that continues to offer accessible and quick solutions for wrist fractures, with the advantage of fast widespread availability of the material for early solution. Additionally, K-wires means a cheap alternative as it is considered a low cost material. Ambulatory surgery and no need to reoperate the patient to retire the wire would help to determine it as a cheap treatment option.

However this traditional method carries its own complications like 21% risk of K-wire infection reported by Lakshmanan et. Al. [27] and 34% described by Hargreaves et. Al.[28]

One of the priorities of treatment, regardless the employed method, is to restore the distal radius anatomy. Brady et. Al. [29] analyzes the radiologic behavior and demonstrated significant recurrence of dorsal angulations and radial shortening in fractures treated with K-wires. Geatting and Bishop also have reported deformity recurrence after pin removal [30].

A methaanalysis showed that Patients treated with volar locking plates had slightly better function than did patients treated with K-wires as measured by their DASH scores at 3 months, but did not found notorious differences in radiographic outcomes as many other studies [31, 32, 33] In this case series all measurements were took back into normal values for anatomic restoration.

Another benefit of ORIF is early mobilization that could lead to better functional outcomes and suppose less days of inactivity and earlier reincorporation.

Results of a retrospective study report the persistence of articular step-off in 35.3% of patients, normal radial inclination restored in 74.5% of patients; normal radial height restored in 66.6% of patients; normal volar tilt was achieved in 90.2% of patients; and normal ulnar variance restored in 86.3% of patients. This study suggests that ulnar variance and volar tilt are the most important radiographic parameters to be restored to obtain good functional outcome in distal radius fracture [34].

C O N C L U S I O N S

Distal radius fractures represent a frequent orthopedic injury, more common in females and easily found in old patients, related with low energy trauma.

Radial inclination, ulnar variance and radial tilt were restored after open reduction and internal fixation with locking volar plates. This technique warranties a safer option in the management and restoration of the distal radius anatomy.

The actual tendency between surgeons, in accordance with the bibliography, continues to be treating wrist fractures with volar plate, in view of enhancing the outcomes and prevent further complications.

A C K N O W L E D G E M E N T S

I am most thankful for the *International Bone Research Association* that has provided support for this paper. Being included in the Scholarship program for clinical residence, allowed me, as intern resident, to achieve one of most fruitful experiences of my professional training.

This paper and the research behind it would not have been possible without the exceptional support of my supervisor, Alejandro Badia, M.D. His hospitality, enthusiasm, knowledge and exacting attention to detail have been an inspiration and kept my work on track from the beginning.

B I B L I O G R A P H Y

1. Nellans et al. Epidemiology of Distal Radius Fractures. Hand Clin (2012); 28:113–125.

2. Oyen J, Brudvik C, Gjesdal CG, et al. Osteoporosis as a risk factor for distal radial fractures: a case control study. J Bone Joint Surg Am (2011); 93:348–56.

3. Putnam MD, Seitz WH: Fracturas distales del radio. Cap 20, en: Bucholz RW. Rockwood & Green's. Fracturas en el adulto. Tomo 2. Madrid, 2003.

4. Fernandez D, Wolfe S: Fracturas del extremo distal del radio. Cap 16, en: Green´s Cirugia de la Mano. Tomo 1. Madrid, 2007.

5. Simic PM, Weiland AJ. Fractures of the distal aspect of the radius: changes in treatment over the past two decades. Instr Course Lect (2003); 52:185–195

6. Catá & cols. Fracturas inestables extraarticulares del radio distal. Rev Asoc Argent Ortop Traumatol (2011); 5-13.

7. Obert L. et al. Fixation of distal radius fractures in adults: A review. Orthopedics & Traumatology: Surgery & Research (2013); 99:216—234.

8. David M. Lichtman, MD, et al. Treatment of Distal Radius Fractures.J Am Acad Orthop Surg (2010); 18:180-189.

9. Kenneth J. Koval et al. Fractures of the Distal Part of the Radius The Evolution of Practice Over Time. Where's the Evidence. J Bone Joint Surg Am. (2008); 90:1855-1861.

10. Maria K T Wilcke, Henrik Hammarberg, and Per Y Adolphson. Epidemiology and changed surgical treatment methods for fractures of the distal radius. Acta Orthopaedica 2013; 84 (3): 292-296.

11. Ville M. Mattila et al. Significant Change in the Surgical Treatment of Distal Radius Fractures: A Nationwide Study Between 1998 and 2008 in Finland. J Trauma. (2011);71: 939-943

12. Cooney WP, Dobyns JH, Linscheid RL. Complicationsof Colles' fractures. J Bone Joint Surg [Am] (1980); 62:613-19.

13. D. A. Rikli, P. Regazzoni. Fractures of the distal end of the radius treated by internal fixation and early function. J Bone Joint Surg [Br] (1996);78-B:588-92.

14. Palmer AK, Glisson RR, Werner FW. Ulnar variance determination. J Hand Surg (1982); 7: 376-379

15. Aro HT, Koivunen T. Minor axial shortening of the radius affects outcome of Colles' fracture treatment. J Hand Surg Am (1991);16:392-8

16. Melone CP Jr. Articular fractures of the distal radius. Orthop Clin North Am (1984);15(2):217-36.

17. Hagert CG. Distal radius fracture and the distal radioulnar joint: anatomical considerations. Handchir Mikrochir Plast Chir (1994); 26:22-6

18. Simone Waldt, Matthias Eiber, Klaus Wörtler. Métodos de Medición y Clasificación en Radiología Musculoesquelética. 2013. Editorial Médica Panamericana.

19. Kristesen SS, Thomassen E, Christensen F. Ulnar variance determination. J Hand Surg 1986;11B:255-257

20. Fernandez DL. Reconstructive procedures for malunion and traumatic arthritis. Orthop Clin North Am (1993);24:341-63

21. Short WH et al. A biomechanical study of distal radial fractures. J Hand Surg [Am] (1987); 12-A: 529-34.

22. Taleisnik J et al. Midcarpal instability caused by malunited fractures of the distal radius. J Hand Surg (Am) (1984);9:350-7

23. Fracture and Dislocation Classification Compendium—2018 J Orthop Trauma, Volume 32, Number 1 Supplement, January 2018

24. Badia, Alejandro & Touhami, A.. (2006). Volar Plating of Distal Radius Fractures. 11. 137-148. 10.1016/j.ahc.2006.07.001.

25. American Academy of Orthopaedic Surgeons. The treatment of distal radius fractures: guideline and evidence report. 2009. Available at: http://www.aaos.org/research/guidelines/drfguideline.pdf

26. Kenneth J. Koval et al. Fractures of the Distal Part of the Radius The Evolution of Practice Over Time. Where's the Evidence. J Bone Joint Surg Am. (2008); 90:1855-1861.

27. Palaniappan Lakshmanan, et al. Infection rate of percutaneous Kirschner wire fixation for distal radius fractures. Journal of Orthopaedic Surgery (2010); 18(1):85-62010; 18(1):85-6.

28. Hargreaves DG, Drew SJ, Eckersley R. Kirschner wire pin tract infection rates: a randomized controlled trial between percutaneous and buried wires. J Hand Surg Br. (2004); 29:374-376.

29. Brady O, Rice J, Nicholson P, Kelly E, O'Rourke SK. The unstable distal radial fracture one year post Kapandji intrafocal pinning. Injury (1999); 30(4):251-255

30. Geatting M, Bishop A. Intrafocal (Kapandji) pinning of unstable fractures of the distal radius. Orthop. Clin. N. Am. (1993); 24:301±7

31. Franceschi F, Franceschetti E, Paciotti M, Cancilleri F, Maffulli N, Denaro V. Volar locking plates versus K-wire/pin fixation for the treatment of distal radial fractures: a systematic review and quantitative synthesis. 2015 Sep;115(1):91-110.

32. Chaudhry H, Kleinlugtenbelt YV, Mundi R, Ristevski B, Goslings JC, Bhandari M. Are Volar Locking Plates Superior to Percutaneous K-wires for Distal Radius Fractures? A Meta-analysis. Clin Orthop Relat Res. 2015 Sep;473(9):3017-27.

33. Costa ML, Achten J, Rangan A, Lamb SE, Parsons NR .. Percutaneous fixation with Kirschner wires versus volar locking-plate fixation in adults with dorsally displaced fracture of distal radius: five-year follow-up of a randomized controlled trial. Bone Joint J. 2019 Aug;101-B(8):978-983.

34. Perugia, Dario et al. Is it really necessary to restore radial anatomic parameters after distal radius fractures? Injury, Volume 45, S21 - S26