IBRA fellowship report after visiting
Hand and Microsurgery department
in Tampere University Hospital in Finland,
from 06. 01. 2009 to 03. 04. 2009

In Tampere University Hand and Microsurgery department is working 6 hand surgeons and 3 to 4 specializing doctors. They are having around 500 elective cases, 600 emergency cases and 5000 visits in outpatient clinic per year. In elective surgery all fields of hand surgery is covered including congenital hand problems and brachial nerve plexus treatment. Emergency cases involve from common fractures, tendon injuries to replantation and emergency microvascular reconstruction after trauma.

At first we made together with prof. Vilkki a plan of my stay. We had a discussion, what are my aims and what are the possibilities. So I had a chance to see the work of many hand surgeons with different interests.

Every morning there was a ward round, all the patients were discussed. It included short overview of the problem, treatment until the moment and plan for further treatment. Physiotherapist and occupational therapist were taking part of the ward round. Additionally on Tuesday and Thursday mornings the problematic outpatient clinic cases data including imaging diagnostics were discussed before ward round and preference for treatment were proposed. On Wednesday mornings was a “journal club”, one problematic article were prepared and presented by one specializing doctor and after that was an open discussion.

On Mondays I went with dr. Havulinna to outpatient clinic. He is more focused to wrist and ante-brachium surgery. So I saw many different wrist problems, what were already treated or came to the first visit. It was very useful to see the first examination and the way to decision, what kind of treatment would be optimal. Also I saw some complicated cases, e.g. partial arthrodesis which were not fused or still painful.

On Monday afternoons there were so called problematic outpatient clinic. Cases which had diagnostic errors or making decisions for treatment needed more complex handling were called for that time. All doctors who had no other duties were attending on that outpatient clinic. The patient was questioned and examined by one of the specializing doctors and then he/she presented it to others. After that additional questions were asked from patient, some more tests were made and finally consensus were found and some more studies were planed or treatment decision were made.

Tuesdays were reserved for operating theater. Long lasting microvascular reconstructive cases were mostly operated on Tuesdays. I had a chance to assist almost on all cases in that period. There were toe-to-hand reconstruction after traumatic loss of fingers and for radius aplasia (so called Vilkki procedure), some extended lateral arm flaps, anterolateral thigh flap, Schwanoma in brachial plexus, some hypoplastic thumbs, partial pectoralis major transfer for elbow flexion on arthorgrypotic patient, these mentioned ones are most interesting cases from Tuesdays in operating theater (see appendix of photos).

Prof. Vilkki had his outpatient clinic on Wednesdays mornings and I took part of that. Most of the patients were with congenital hand problems to plan the treatment or post-op visit and further treatment planning (see appendix of photos). Also were there cases for or after secondary reconstruction after severe upper extremity trauma, e.g. toe-to-hand reconstruction, brachial plexus reconstruction.

Afternoons of Wednesdays I spent with dr. Paavilainen who run the outpatient clinic for children with Erb paresis. The patients age started from 1 months. They were examined for suspicion of brachial plexus injury, which come up during complicated birth. Additional studies were made for making decision to operate or not. Also already operated or older partially recovered non-operated patients visited that outpatient clinic for getting advise for their physiotherapy and to be followed about late complications (e.g. with shoulder) and if possible proposed for surgery to improving upper extremity function.

Thursdays were quite variable. It depend more about exact cases, it was possible to attend in day-surgery unit for wrist surgery including arthroscopy and CMC procedures. Other option was to join with dr. Viljakka for shoulder surgery (e.g. osteosynthesis, arthroplasties, corrective osteotomies). Also were there some elbow arthroscopies.

Friday mornings started with lectures made by specializing doctors. Those were about some special field of hand surgery. On two Fridays were there some guests who gave their lectures, one was dr. Moran from Mayo Clinic, he talked about proximal row carpectomy compared with scaphoidectomy and four-corner arthrodesis. Second one was dr. Hettiaratchy from Guy's and St. Thomas hospital from London, he lectured about first CMC joint osteoarthritis and he gave also an extra lecture about immunology in hand transplantation.

After lecture I joined with dr. Paavilainen in outpatient clinic or if there were interesting cases in day-surgery unit I went to assist on those if possible.

Additionally to the regular clinical work I took part of emergency calls in hand surgery. If there were some interesting case, what needed microsurgical reconstruction, the doctor on call informed me and I could join with she/he in operating theater. It was also possible on weekends and in night time. The most interesting cases in which I could assist were reconstruction, revascularization of traumatic partial, transmetacarpal amputation, thumb avulsion amputation (see appendix of photos).

Also I got overview about rehabilitation system and protocols. One day I joined with physiotherapist for that.

The whole team was friendly and open for discussion. They kindly answered to my questions and explained things what remained unclear for me at first sight.

Kristo Kask
IBRA grantee

Appendix of photos

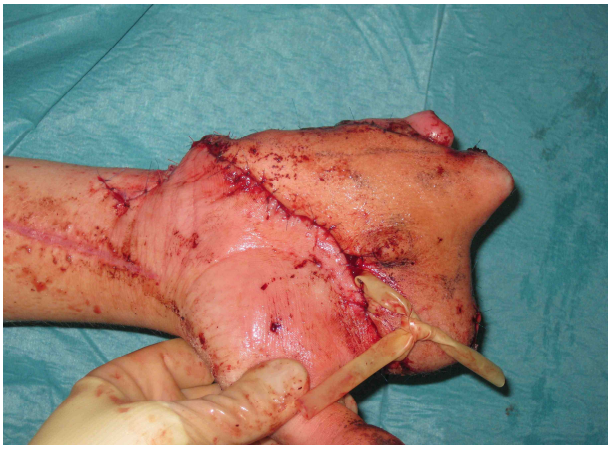

Patient with degloving injury, which was at first replanted, but did not succeed.
Secondary was performed revision and covering with extended lateral arm flap.

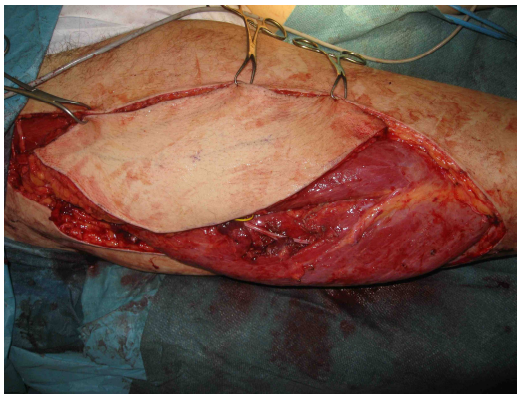

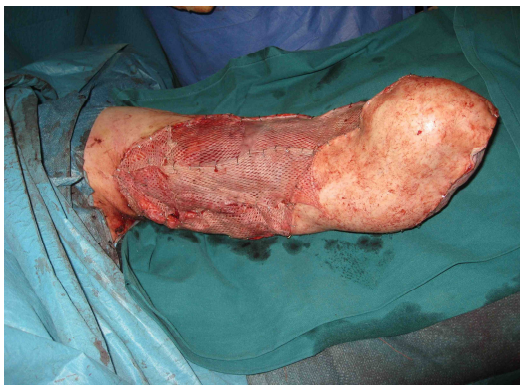

Patient with traumatic amputation from lower arm and degloving of upper arm.
Reconstruction of the stump with anterolateral thigh flap.

Patient from prof. Vilkki outpatient clinic.
Congenital deformity, three months after toe-to-finger trasnfer.

One emergency case, traumatic partial amputation on metacarpophalangial joint level.
Revascularaized and reconstructed.