Prof. Dr. Johannes Kleinheinz
Chairman IBRA Education Commitee Head

IBRA Scholarship Program B
November 2009 – April 2010

REPORT ON FELLOWSHIP IN THE DEPARTMENT OF ORAL AND MAXILLOFACIAL SURGERY OF TSURMI HOSPITAL, YOKAHAMA – JAPAN

by Cyrille Tison
Resident in the department of oral and maxillofacial surgery of Lille – France

I want to thank the International Bone Research Association (IBRA) for financial assistance it provided me and allowed me to prepare more serenely six months in Japan.

I also thank Professor Hamada, and the staff of Tsurumi hospital, for their warm welcome and valuable knowledge that they bring me.

SUMMARY

I- INTRODUCTION

II- OBJECTIVES

III- TEMPOROMANDIBULAR JOINT DISORDERS

1- PHYSIOPATHOLOGY

2- ALGORITHM OF PATIENT MANAGEMENT

3- VISUALLY GUIDED IRRIGATION

4- OPEN SURGERY

5- BIOLOGICAL RESEARCH

IV- JAPANESE HEALTHCARE

1- GLOBAL JAPANESE HEALTHCARE

2- PART OF ORAL AND MAXILLOFACIAL SURGERY

V- TSURUMI HOSPITAL

VI- JAPANESE CULTURE

VII- CONCLUSION

I- INTRODUCTION

I am fortunate to have a teacher who has travelled a lot.

Professor Ferri, my teacher, has indeed made many meetings during his studies in Nantes, but also subsequently integrating several teams, such as the United States, Canada or Switzerland.

I have benefited from it two levels. First the transmission of the experience he has accumulated during these trips. Then by transmitting the desire to discover my turn to other cultures, other teams in order to draw specific lessons, a different view from what I had before.

In seeking a service where I could turn to my new experience, I first put my main objective : to improve my knowledge and gain experience in a field I really enjoy, the temporomandibular joint disorders. This framework is in fact quite common disease, but the management is often discussed, which makes it difficult to understand for students. Professor Ferri submitted my application for an internship in the department of Professor Hamada, who has extensive experience in this field.

I then did an internship for one semester within the group of Professor Hamada, in the department of oral and maxillofacial surgery at the hospital of Tsurumi, Yokohama - Japan, between November 2009 and May 2010.

I will speak in this report of the objectives of the internship, detailing specifically what I learned from temporomandibular joint disorders, then I will address the structure of the Hospital of Tsurumi and Japanese culture.

I am very honored to have been accepted into this team that brought me a lot.

I hope one day to honor my Masters in transmitting this knowledge I have inherited.

Cyrille Tison

II- OBJECTIVES

1- Main objective : <u>study of the temporomandibular joint disorders</u>

I was fortunate to learn from Professor Hamada, a leading expert on these diseases and who was kind enough to send me some of his knowledge.

I divide this chapter beginning with the general management and then detail the arthroscopy and open surgery. I finally talk about Professor Hamada's work on the study of cytokines in the synovial fluid.

2- Secondary objective : <u>discovery of the japanese healthcare</u>

We learn much from others, and it seemed interesting to study the Japanese system to ask me questions about the way in France.

I will first speak of the system in his global nature, then I will state what is the part of Oral and Maxillofacial Surgery.

III- TEMPOROMANDIBULAR JOINT DISORDERS

1- PHYSIOPATHOLOGY

The Japanese education typically teaches that temporomandibular joint disorders are classified into five categories:

-Muscular disorders
-Capsulo-tendinous disorders
-Internal derangements
-Osteoarthritis
-Other disorders

This grading system gives the false impression that unfortunately these entities are distinct and represent different pathological settings.

In fact, the vast majority of these disorders affect patients with muscular parafunction with bruxism, which eventually causes an overload of the temporomandibular joint, thereby inducing an inflammatory reaction within the joint. This causes a synovitis and osteoarthritis. It can then continue to evolve with the formation of osteophytis, with internal derangement.

We then see that it is no different diseases, but different states, may change from one to another through a chronic mode, thus bringing the disease in a vicious circle.

2- ALGORITHM OF PATIENT MANAGEMENT

1- Check-up

First, before a patient showing symptoms of dysfunction of the masticatory system, eliminate an emergency (an alteration of general condition, a swelling evoking a malignant tumor) and a differential diagnosis (auricular disorder...).

It then assesses the clinical impact of this dysfunction:
- Limitation of mouth opening
- Painless range of mouth opening
- Pain (rated on a visual analogical scale from 0 to 100)

The paraclinical examination, in the absence of specific clinical signs (suspected tumor, connective tissue disorder...), include only a panoramic view.

2- Set up of the initial treatment

Then put in place a symptomatic therapy that is non-invasive.
It includes:
- **Relaxation**, to reduce muscle tension during sleep;
- **Dietary education**, with eviction of hard food and chewing gum;
- **Auto-physiotherapy**, with multiple daily massages muscle;
- **Stretching**, to help even the muscle relaxation;
- **Medication**, as required by analgesics, muscle relaxants;
- An **occlusal splint**, to reduce the tension of the joint during sleep.

This treatment must be followed for three months, rigorously.

3- First clinical control

The criteria for treatment success are :
-The increase of the maximum mouth opening;
-A painless mouth opening-up of more than 38mm;
-Visual analogical pain is than 20, or decreased by 60%.
All these criteria must be present to certify the success.

If case of good outcome, relaxation as well as dietary education are to be retained. The rest of the initial treatment is to return in case of recurrence of symptoms.

In cases of poor outcome at three months, an MRI is then performed. At the same time, irrigation of the TMJ is performed under local anaesthesia, combined with arthroscopy. It is call visually guided irrigation.

MRI is performed to study the articular disc in search of a dislocation or lesions. It also looks up a joint effusion, the intensity of the signal may be predictive of clinical outcomes after irrigation treatment, according to a study by Professor Hamada's department bearing on fifty-six patients.

Irrigation TMJ is therapeutic. It also performs a sampling of synovial fluid has the opportunity to study the pro-and anti-inflammatory cytokines, which allows a prognostic assessment rate.

The arthroscopy does not improve symptoms by lysis of fibrous adhesions, as has been proven the work of Professor Hamada. It permits, however, a clinical study of the joint, easily reproducible which is useful in following up the disease.

The initial treatment course is held in place for a period of three months.

4- Second clinical control (when poor outcome at the first control)

In case of good outcome, as the first clinical control, relaxation as well as lifestyle modifications are to be retained. The rest of the initial treatment is to return in case of recurrence of symptoms.

In case of poor outcome, a CT scan is performed, the search for bone lesions in type of osteophytis or lose bodies.

If such elements are present, an open surgery of the temporomandibular joint is programmed.

The initial treatment measures are also maintained.

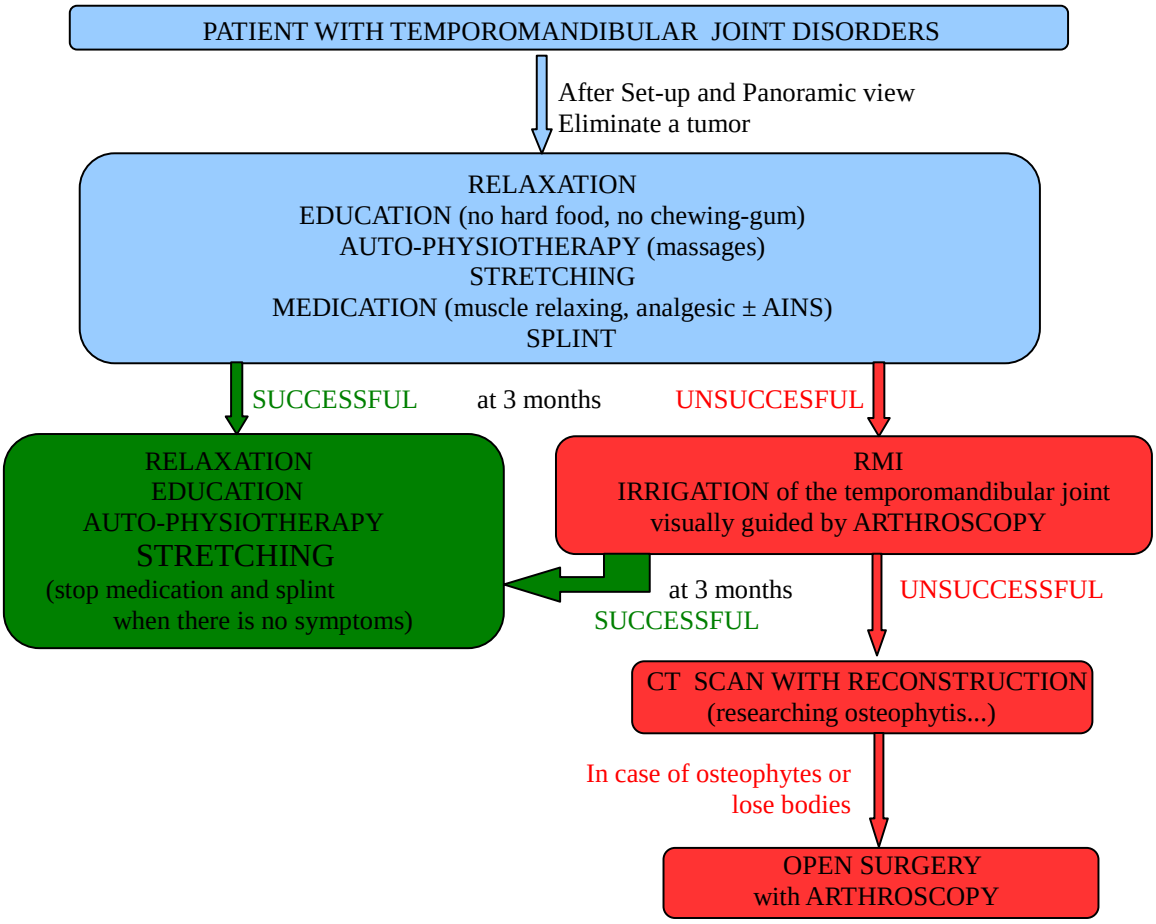

This therapeutic strategy in place in the team of Professor Hamada, permit the successful treatment about 58 of 61 (95%) patients refractory to adequate non-surgical treatment.

References :

Nakaoka K, Hamada Y. et al. The changes of joint effusion on MRI and arthroscopic findings after visually guided TMJ irrigation correlated to the clinical outcome. Oral Surg Oral Med Oral Patho Oral Radiol Endod 2009

Hamada Y et al. One-year clinical course following visually guided irrigation for chronic closed lock of the temporomandibular joint. Oral Surg Oral Med Oral Patho Oral Radiol Endod 2006;101:172-6

3- VISUALLY GUIDED IRRIGATION

Arthroscopy of the temporomandibular joint has been presented for the first time by Onishi in 1975.

It is used in the team of Professor Hamada in the exploration of dysfunction of the masticatory system after a failed first-line treatment, if properly conducted during three months.

A therapeutical irrigation of the joint is performed in the same time. This is known as visually guided irrigation.

Initial treatment is continued, and a reassessment is made even three months later.

During this visually guided irrigation are made arthroscopic scores, based on the arthroscopic findings obtained.

There are :

-Articular Surface score :	0- normal
	1- fibrillation
	2- bone exposure and/or disc perforation
-Synovial Lining score :	0- normal
	1- hypervascularity and/or limited hyperplasia
	2- more expended lesions
-Fibrous Adhesion score :	0- no adhesion
	1- single « band-like » fibrous adhesion
	2- prononced fibrous adhesion

This score allows to quantify changes in intra-articular pathology between two irrigations.

In case of treatment failure in the checking clinic three months after irrigation, a new visually guided irrigation can be made, possibly at the first stage of surgery to open the joint.

Details of the different times of visually guided irrigation :

1- Marking of the mandibular's condyle and the zygomatic arch, with his articular eminence

2- Local subcutaneous anaesthesia with 2mL of Xylocaïne, without vasoconstrictor (to avoid intra-articular modification)
Three injections :
-postero-lateral part of the TMJ
-antero-lateral part of the TMJ
-on the auriculotemporal nerve route (behind and underneath the mandibular's condyle)

3- Serum injection in the joint, through the postero-lateral approach, making pumping with the liquide, for :
-stretching of the joint, to facilitate the arthroscopy
-and take a sample of the synovial fluid

4- Postero-lateral approach
Passing through the plans by pointed trocar till the capsule, then use the smooth trocar.
Once in the joint, take in place of the arthroscope, in the superior joint space (the only correctly visible).
Then insertion of a needle in the anterior part of the joint, to evacuate the irrigation bring by the arthroscope (permit stretching of the joint and then move apart the different elements who become visible).

5- Antero-lateral approach
Useful to introduce tools.
This step is not use when an open surgery is programmed in the same time.

6- Cutaneous closure

Visually guided irrigation of the joint can be clinically effective in patients refractory to appropriate non-surgical treatment, and is also useful as a tool for clinical research.

The work of Professor Hamada also show that fibrous adhesions are not a major factor influencing symptoms. Indeed, they may worsen despite clinical improvement between two arthroscopies.

Similarly, intra-articular inflammation may persist despite clinical improvement, which encourages continuous follow-up and education of auto-physiotherapy to induce relaxation of the muscles of mastication.

References :

Hamada Y et al. Visually guided temporomandibular joint irrigation in patients with chronic closed lock: Clinical outcome and its relationship to intra-articular morphologic changes. Oral Surg Oral Med Oral Patho Oral Radiol Endod 2003;95:552-8

Hamada Y et al. Influence of arthroscopically observed fibrous adhesions before and after joint irrigation on clinical outcome in patients with chronic closed lock of the temporomandibular joint.Int. J. Oral Maxillofac. Surg. 2005;34:727-732

Hamada Y et al. One-year clinical course following visually guided irrigation for chronic closed lock of the temporomandibular joint. Oral Surg Oral Med Oral Patho Oral Radiol Endod 2006;101:172-6

Hamada Y et al. Severity of arthroscopically pathology and levels of inflammatory cyrokines in the synovial fluid before and after visually guided temporomandibular joint irrigation correlated with the clinical outcome in patients with chronic closed lock. Oral Surg Oral Med Oral Patho Oral Radiol Endod 2008;106:343-9

4- OPEN SURGERY

Surgery of the temporomandibular joint, in the temporomandibular joint disorders, occurs with a **new treatment failure after three months** after irrigation of the joint associated with arthroscopy. A CT scan is done before, to search **for foreign bodies or osteophytis**, which will motivate the indication of this surgery.

The goal of intervention is then correct the internal derangement by simple rxcision of osteophytis.

However, no repositioning is done on the articular disc, to avoid any problems that may induce scar decreased range of motion. We shall just possibly a simple reshaping of the articular disc.

Reference :
Kondoh, Hamada et al. Simple Disc Reshaping Surgery for Internal Derangement of the Temporomandibular Joint: 5-Year Follow-Up Results. J Oral Maxillofac Surg 61:41-48, 2003

Detail of the different times of open surgery :

1- Marking along the entire anterior length of the ear.
Then subcutaneous infiltration by local anaesthesia with vasoconstrictor

2- Opening along the ear.
Dissection along the anterior part of the tragus, with meticulous advanced, and haemostasis step by step.

3- Dissection till the superficial layer of the temporalis fascia
Marking of the superficial temporal vein, that we follow till the media temporal vein.
The media temporal vein is ligatured, to facilitate the approach of the TMJ.

4- Dissection to the TMJ
Arriving on the tendinomuscular structures surrounding the condyle and the zygomatic arch.
Clearing of those tissues, with rugine and scissors.

5- Superior joint space approach
Sub-periostal incision along the external border of the glenoid fossa and the anterior part of the articular eminence.
Then we rugine and cautiously enter in the superior joint space while dissection with scissors, to avoid articular disc lesion.

6- Stretching of the superior joint space, to facilitate the exploration.

7- Approch of the lower joint space while cautiously dissection with scissors, to avoid articular disc lesion, and without sub-periosteal incision, to avoid articular cartilage lesion.

8- Arthrotomy
Resection of possible osteophytis with osteotome, bur and rasp.

9- Functional tests
Check of the results by :
-mouth opening measurement
-verification of good kinetic of the TMJ during mobilisation

10- Closure
Closure of the lower joint space.
Injection of 2mg Dexacortisone in the lower and superior joint space.
Closure of the superior joint space.
Draining.
Subcutaneous and cutaneous closure.

5- BIOLOGICAL RESEARCH

The work of Professor Hamada and his team on cytokines found in synovial fluid, have to prove that a detectable level of cytokine **IL-10** is a predictor of good outcome.

In contrast, a detectable level of **IL-6** and **IL-8** would be a preacher of poor outcome.

Furthermore, the rate of **VEGF** (vascular endothelial growth factor) seems to correlate with the clinical status of patients. This molecule may then be a promising target for future chemotherapy in temporomandibular disorders.

The success criteria in relation to these studies are the same as those presented earlier in this chapter (2 - Algorithm).

The synovial fluid is taken from the same time that irrigation, just before it.

References :

Hamada Y et al. Inflammatory cytokines correlated with clinical outcome of temporomandibular joint irrigation in patients with chronic close lock. Oral Surg Oral Med Oral Patho Oral Radiol Endod 2006;102:596-601.

Hamada Y et al. Cytokine and Clinical Predicators for Treatment Outcome of Visually Guided Temporomandibular Joint Irrigation in Patients With Chronic Closed Lock. J Oral Maxillofac Surg 66:29-34, 2008.

Kumagai K, Hamada Y et al. The levels of vascular endothelial growth factor in the synovial fluid correlated with the severity of arthroscopically observed synovitis and clinical outcome after tmeporomandibular joint irrigation in patients with chronic closed lock. Oral Surg Oral Med Oral Patho Oral Radiol Endod 2010;109:185-190

IV- JAPANESE HEALTHCARE

1- GLOBAL JAPANESE HEALTHCARE

The health system in Japan is based on universal social insurance (since 1961).
It is organized around three main actors : patients, healthcare providers and insurers.
The system is financed by employee contributions, employer contributions of direct self-employed and inactive.

The Japanese government plays three roles in this system:
-Regulator, by regulating the health system and regulating health insurance;
-Insurer, managing several health insurance;
-Provider, with its own hospitals, representing 18% of hospital and 30% of hospital beds.

There are two main modes of coverage :
-Shakai-hoken for the employees of a company with more than five employees. The coverage is 80% for medical expenses, and 70% for family members (spouse and children).
-kokumin kenko hoken (or national welfare) for other people. The coverage of medical expenses is 70%.
Membership in the health insurance program is automatic and depends on the workplace or home. Children are automatically insured by the insurer of their parents.

The remainder of medical costs can of course be supported by insurance.

The patient has the free choice of provider.
On the other hand, the practitioner has the free choice of his installation and prescription.

Since 2000, there is a specific system of insurance for long-term care.

This system is much interest from other OECD countries.
Indeed, despite universal coverage, covering many services, the price is modest co-payments, although the population is older than the average for OECD countries, and this with a spending level in reasonable health.

The system suffers, moreover, a lack of doctors, exacerbated by poor spatial distribution. There are in fact two doctors per 1,000 inhabitants, against an average of three in other more advanced countries.
The lack of doctors affects mostly paediatrics and obstetrics.

Patients, however, seem satisfied with the service they receive.
Some evidence suggests that improving health is significant in Japan, but it is difficult to link it with only the healthcare system, because other factors come into play, such as diet or social conditions.

The reforms of recent years are mainly a response to an aging population, with a special system of insurance for long-term care, a rebalancing of supply dependency care to nursing homes and home care services.

Some figures :
-Total population (July 2009) : 127,078,679
-GDP per capita (2004) : U.S. $ 30,039
-Life expectancy at birth m / f (2004) : 79.0/86.0 years

-Total health expenditure per capita (2003) : U.S. $ 2,244
-Public health expenditure per capita : U.S. $ 1,818
-Total expenditure as% of GDP (2003) : 7.9
-Public expenditure as% of total health expenditure (2003) : 81
-Private expenditure as% of total health expenditure (2003) : 19

References :
-GIPS PSI
-Hyoung-Sun Jeong and Jeremy Hurst. An assessment of the performance of the japanese health care system. Organisation for Economic Co-operation and Development 2001
-The Asahi Shimbun

2- PART OF THE ORAL AND MAXILLOFACIAL SURGERY

The Oral and Maxillofacial Surgery is mainly performed by practitioners from a dental curriculum in Japan. However, it remains accessible to medical student.

The dental school begins with common six years after an entrance examination, after which the student takes a national examination.

If successful, he becomes resident, and then passes a year in a hospital.

He obtained a license and then may settle as a dentist, or taking the competitive specialty.

The competition is conducted locally, and each student can spend on several sites. The student gives an order of preference, then a convergence of results with the choice is made at the national level. Several specialties are available, such as the Oral and Maxillofacial Surgery, anaesthesia, biology, radiology...

Several university degrees are available in specialty. The assumption of these degrees varies depending on the specialty and the university.

The three levels are:

-Certificate, which may require such at least three years of training, an article published and twenty patients undergoing general anaesthesia;

-Specialist, often needed to settle;

-Supervisor.

It is very interesting to see that very different university systems, such as France and Japan, offer equally good care for patients.

Indeed, maxillofacial surgery in France is only available for medical students, and if a merger with a dental course is considered by some it remains highly controversial.

We then see that although these courses lead to different sensitivities, it is finally time to experience the real entry into the specialty that is important for the quality of services rather than belonging to a medical curriculum dental.

Summary of academic record for the japanese oral and maxillofacial surgery :

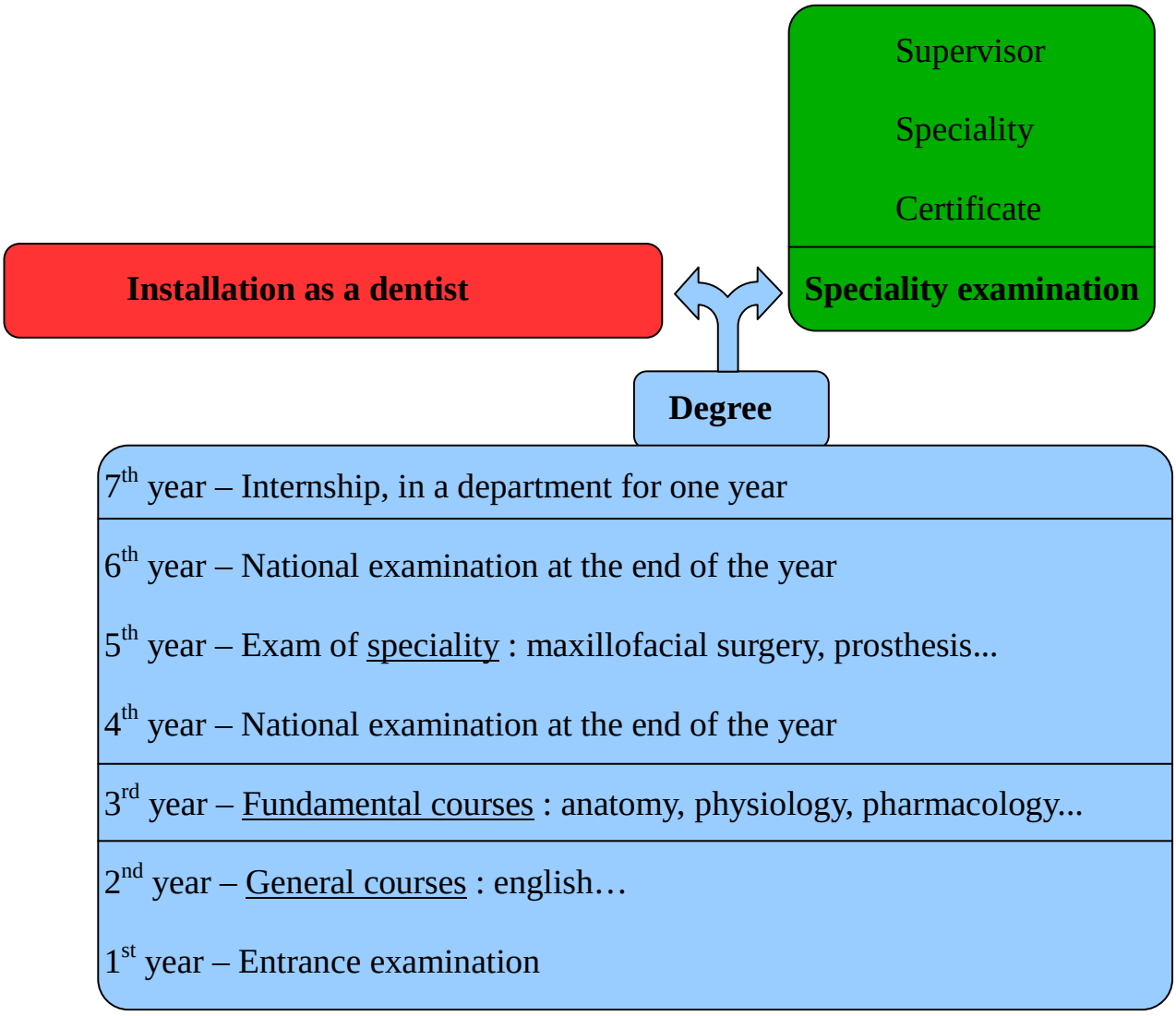

VI- TSURUMI HOSPITAL

In Japan, there are three types of universities :
-National ;
-Public ;
-Private.
There are many private hospitals in Japan (82%).
This is for the hospital in Tsurumi, part of Sōji Temple, a Buddhist temple in the Tsurumi district in the city of Yokohama, just south of Tokyo.

The site consists of the temple, so one hand, and hospital and dental school and university of literature, on the other.
This is a dental hospital, associated with a dental school in the heart of the temple Sōji.
The hospital is built on five ploor, which are department of general dentistry, orthodontics, periodontics, pediatric dentistry, geriatric dentistry, dental care, disability, dental hygiene, oral and maxillofacial surgery, laboratory, radiology and a special department, where among other treats xerostomia and sleep apnea syndromes.
There are also two medical doctors in the facility: a cardiologist and an ophthalmologist.
The students were part of the hospital adapted for practical work.

A second building home office services, medical offices, laboratories, lecture halls for courses and symposium.

The department of oral and maxillofacial surgery many patients home for problems:
-Impacted Teeth;
-Orthognathic surgery;
-Cancer;
-Temporomandibular disorders.

My place in the team of Professor Hamada allowed me to follow the consultation, particularly in relation to temporomandibular disorders and the operating units, including open surgery of the joint (for resection of osteophytis and synovial chondromatosis) and arthroscopy, osteotomy of Obwegeser altered by Dalpont, cancer surgery and reconstruction with free flaps.

Entrance of Tsurumi hospital

Sōji temple

VII- JAPANESE CULTURE

Japan is a country that offers a very traditional culture alongside the modernity of the most impressive.

On the one hand, Buddhist and Shinto traditions has left a great legacy, with many temples and Zen gardens.
These are some really impressive, but especially when you know they express the duality that we can really appreciate.
I had the pleasure of visiting two cities rich in temples, Kyoto and Kamakura.
The traditional side also offers fine restaurants, with completely different culinary traditions of Western countries, and surprising kabuki theaters.

On the other hand, the modern Japanese can be just as impressive.
Tokyo offers an architecture full of skyscrapers, each with their own styles, often with a panoramic view of the city to offer, like Ginza or Odaiba.
There are of course, fashion dress, surprisingly, that one meets in the districts of Shibuya and Harajuku.

What impressed me the most in Japan is a culture of respect, coupled with a lack of aggressiveness. Indeed in France, the stressful situations of everyday life regularly trigger aggression. In Japan, however, a more measured approach is often adopted, which makes the relationship between people less difficult.
For me, culture shock was mostly there in the peaceful within modernity.

VIII- CONCLUSION

Those months spent in Japan gave me a lot, both professionally and culturally.

Professionally, I discovered a different but equally effective as mine. And this is really interesting experience to see that we can have good results by different routes. I also had the pleasure of following Professor Hamada and thus benefit from his vast experience, which will probably be very favorable for me in the future, and I will be in the future to work on this topic.

Furthermore, I discovered a fascinating culture, I discover that my turn to those around me. It allowed me to see my surroundings in a new light, and thus understand new things.

I will stay marked by the months in the country of the Rising Sun, surrounded by charming people and a wonderful legacy.

« Who learn a new language acquires a new soul » Juan Ramon Jimenez