IBRA International Bone Research Association

FLASH 2021

Editor's Message

Since our 15th anniversary two years ago, IBRA membership has doubled and we now enjoy members from more than 60 countries. This increase is due in part to the introduction of our Basic Membership. This option is open to all employees in the healthcare sector and is a great way to get to know IBRA.

Another milestone in IBRA's strategic development is the establishment of local representation in the United States. This move allows us to keep our finger on the pulse of the region and respond quickly to local needs, as well as learn about new ideas and novel approaches from members in North America.

IBRA's presence in Asia and Australia has also been strengthened in recent years. The main contributing factors to this have been IBRA opening new Training Centers, participating in selected regional congresses, and running several courses in the region. In addition, IBRA's Educational Afternoon at FESSH 2020 was broadcast live to China, where it was watched by more than two thousand viewers.

On the scientific side, we were very pleased to co-sponsor the publication of Hintringer et al. on 3D classification and treatment methods for distal radius fractures. The study has met with very great interest. As a result, it has been presented in several webinars and virtual courses and will be presented more frequently at our face-to-face meetings in the future.

In March 2021, the IBRA Virtual Campus was launched. Through this online learning platform, all our members worldwide have free access to recorded webinars and virtual courses, educational videos and professional articles. The Virtual Campus perfectly rounds out our existing medical education and training offerings and is an important component in IBRA's continued expansion. Until we can meet our members in person again, our series of digital offerings will continue and also expand. Information on this is available on our website, as well as on LinkedIn and in IBRA's newsletter.

We look forward to seeing you soon and are happy to provide further information or answer any questions.

The IBRA Administration Team

© 09/2021 - IBRA, Basel, Switzerland

Table of Contents

IBRA – General Information

Editor's Message, Table of Contents	2 – 3
Presentation of the IBRA Virtual Campus	4
New REC Members & new IBRA regional organizational chart	5
New collaboration with the Journal of Clinical Medicine	6
The future of medical education and congresses	7 – 9
IBRA Scholarship at the Department of Oral and Maxillofacial Surgery Faculdade de Odontologia,UNESP, Araraquara, Brazil	10 – 11
IBRA Training Centers 2021	12

Technical Reports

13 – 15	***Lower Limbs*** Biomechanical evaluation of midfoot fixation *L. Claaßen*
16 – 18	***Head*** Management of mandible fracture using a three-dimensional (3D) miniplate System *L. Bohner, F. Beiglboeck, J. Kleinheinz, S. Jung*
19 – 21	***Upper Limbs*** Surgical treatment of chronic anterior radial head dislocations in missed Monteggia lesions in children: A rationale for treatment and pearls and pitfalls of surgery *L. C. Langenberg, D. Eygendaal*
22-– 24	***Upper Limbs*** Dorsal transosseous reduction and a locking plate fixation for intraarticular middle phalanx base fracture *Ji Hun Park, Geun Woo Park, In Cheul Choi, Young Woo Kwon, Jong Woong Park*
25 -– 29	***Upper Limbs*** Volar plate fixation of unstable scaphoid nonunion - is stability key? *P. M. J. Schormans, P. F. W. Hannemann*
30 -– 35	***Upper Limbs*** RSL arthrodesis: indications and mid-term follow-up results *M. Corain, F. Zanotti, M. Giardini, L. Marcucci*
36 -– 39	***Upper Limbs*** Biomechanical Considerations on a CT based treatment-oriented classification in radius fractures *W. Hintringer, R. Rosenauer, S. Quadlbauer*

Presentation of the IBRA Virtual Campus

Beside hands-on training and other live events, IBRA provides e-learning materials through its Virtual Campus. Access is for members only, allowing for communication in a familiar and secure environment.
The materials available include a growing number of recorded webinars, webcasts and online courses, as well as a library of scientific articles, case discussions and instructional videos.

IBRA International Bone Research Association

Virtual Campus

Virtual Courses, Webcasts & Webinars

IBRA offers a wide range of training courses led by our expert faculty. Courses range from short webinars and webcasts to complex courses with multiple modules.

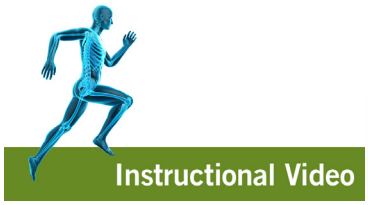

Instructional Videos & Recordings

Our Instructional Videos offer recorded surgeries with commentary from our expert faculty.

Scientific Articles & Other Resources

Our growing library offers selected scientific articles and other resources for further continuing medical education.

New REC Members & new IBRA regional organizational chart

IBRA North America is the first regional section of our association. The goal of our regional structure is to have full-time availability for our members living all over the world. Additionally, they provide our members with more decision-making opportunities of relevance to their respective continent(s). The regional Research and Education Committees consist, therefore, of representatives from our country clusters.

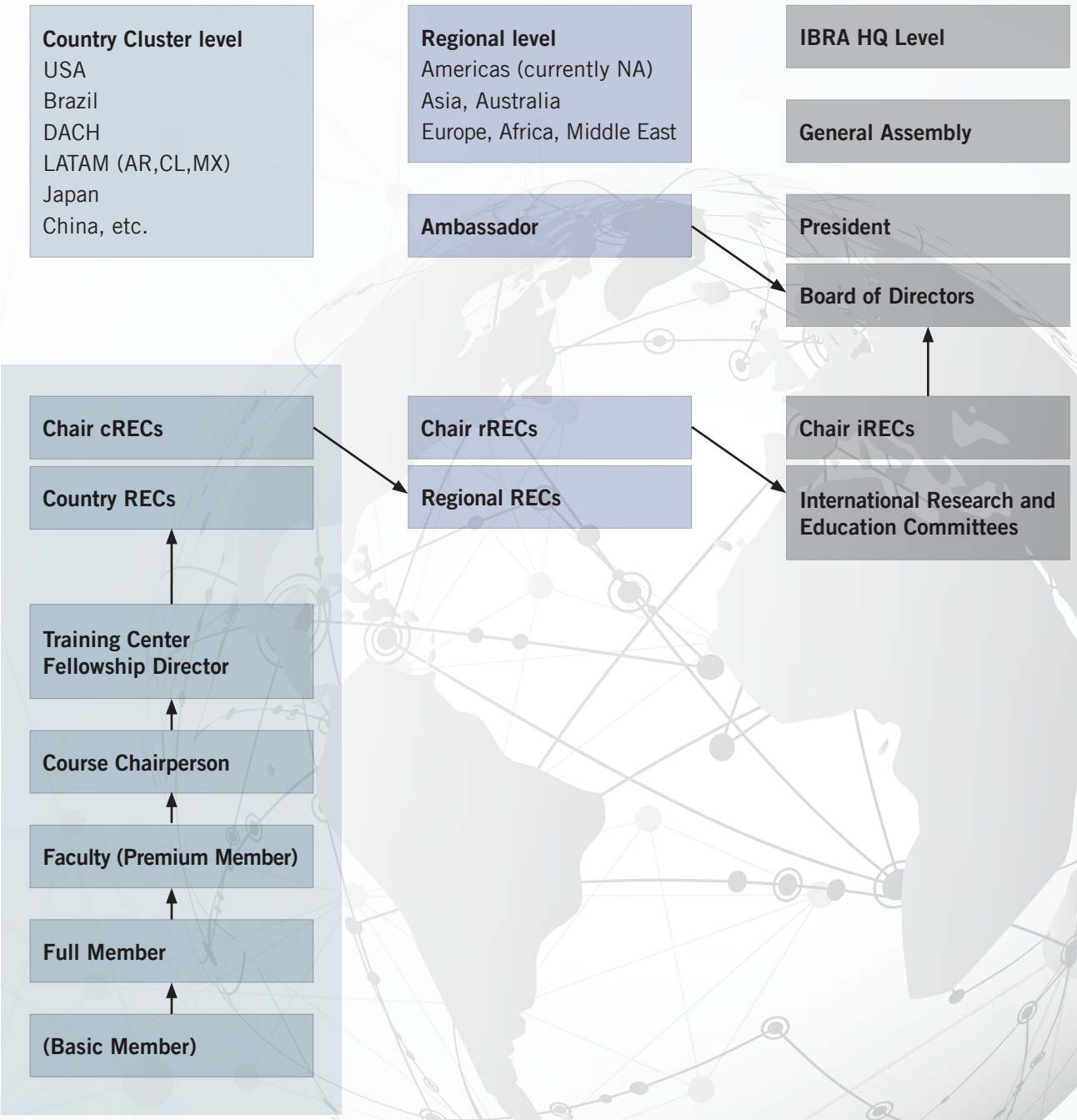

New collaboration with the Journal of Clinical Medicine

Journal of
Clinical Medicine
an Open Access Journal by MDPI

The Journal of Clinical Medicine (ISSN 2077-0383), an international, peer-reviewed, open access journal that provides a platform for news about advances in healthcare/clinical practice, observational studies of patients, and general medical research. This multi-disciplinary journal is aimed at a wide audience of medical researchers and healthcare professionals.

The subject areas include (but are not limited to):

- Clinical Laboratory Diagnosis and Treatment in Internal Medicine
- Traumatology and Precise Surgical Techniques
- Genomics, Proteomics, and Bioinformatics in Clinical Cancer Research
- Epidemiology
- Neurological and Psychiatric Disorders
- Advanced Research in Dermatology and Venereology
- Ophthalmology and Otolaryngology
- Medical Imaging and Nuclear Medicine
- Rehabilitation Medicine and Physiotherapy
- Sports Medicine
- Pediatric and Geriatric Emergency Care
- Women's Health

For further information about the journal, please see: https://www.mdpi.com/journal/jcm and follow the journal on Twitter (@JCM_MDPI)

IBRA Members receive a discount on article processing charges. For more information and to take advantage of the discount, please log in to our Member Area and go to the section "Promotion".

IBRA RESIDENT COURSE

Osteosynthesis of the Hand & Wrist

Recommended for senior residents and physicians in subspecialty training.
The course offers the basics in clinical diagnostics, treatment and follow-up.
The focus is on state-of-the-art surgical techniques

January 27-28, 2022
Zurich, Switzerland

More information at: https://www.ibra.net/Events



The future of medical education and congresses

Interview with

Intercongress was founded in Germany in 1992. Today, the organisation has 35 employees and manages around 50 medical and scientific congresses per year, such as the IFSSH-IFSHT Congress 2019 in Berlin or the annual congress of the German Society for Hand Surgery. The past year has turned the event industry upside down. Thomas Miltz and Nicole Lange agreed to share their experiences and expert tips with us on how to organise successful medical congresses and events in this new normal.

What major changes have you noticed in the planning and implementation of medical education events and congresses in the past 12 months?

Nicole Lange:
Maybe it's easier to say what hasn't changed (laughs). But seriously: the entire events sector, like many other sectors, was turned upside down last year. The initial moment of shock caused by the banning of events and the huge uncertainty about when large-scale gatherings would be possible again was followed by an enormous developmental boost in the digital arena. This began with small things: Organizational meetings that were conducted in person before COVID-19 can now be tackled quite easily using video calls, thus creating enormous flexibility and saving resources of all involved parties.
The most critical change for us as event organizers was most definitely developing digital formats that are an adequate substitute for our cancelled in-person congresses—and doing so in a very short space of time.

Thomas Miltz:
A most exciting aspect has been the conceptual planning of online events, their academic character while also offering better opportunities for interactions between the audience and corporate partners. We had a steep learning curve here and were able to greatly expand our service portfolio, particularly with regard to the integration of the companies. The technical implementation has also been a challenge because we wanted to maintain our high quality standards in the digital environment as well. Fortunately, we have long-established relationships with experienced technology partners who optimally contribute their individual expertise.

What solutions has Intercongress found for its events (medical congresses and training courses) due to the changed circumstances? How are these accepted by the target group?

Thomas Miltz:
At the start of the pandemic, we were strongly focused on postponing congresses - like many other event organizers. In the long term, that was not a viable solution. We therefore developed concepts for online events and hybrid congresses and were able to very successfully adapt these for our individual customers.

Nicole Lange:
Our online events are characterized by their very clear focus, usually with a single topic, and they take place in the afternoons or evenings and have a maximum session length of 60 minutes. Interactions with the audience are also provided by live voting, Q&A sessions, and occasional downstream "Meet the expert" units. The fast and lively format is well received by the target group, and the professional technical implementation is also positively highlighted in the evaluation. What must not be neglected with medical continuing education is patronage by various expert associations as well as certification by the

responsible medical association. We offer a very attractive solution for the target group because recordings of the live events are usually certified for 12 months and the learning outcomes assessment can thus be subsequently carried out at any time.
During the short phase with low case numbers in October 2020, we have been able to gather experience with the hybrid congress format, which enables both in-person and online participation. It is great to see how smooth the transition from real-life to digital participation is: For example, we had some delegates who attended the first, very early session in the morning from their hotel and then later in the day joined us in the congress centre.

What tips can you share for making the transition from an in-person event to a hybrid or online experience as smoothly as possible?

Nicole Lange:
We recommend thinking of different scenarios right from the start or to opt for a hybrid or digital model directly. What must be considered is the lead time, which should be at least three months as a matter of principle for all formats, so that time pressure is not an issue.
Intercongress plans for three different event types for its customers right from the start: In-person, hybrid, and digital. This means that our congresses are on a secure footing for all possible realities, regardless of what COVID-19 throws at us.

Thomas Miltz:
Of course, the organizational effort increases enormously as a result. There is no planning certainty, the organization is difficult to grasp. It is difficult for all those involved to think about and plan for the three options. For us as event organizers, this means keeping an overview across all three scenarios and ensuring close communication with customers, participants, and exhibitors so that we can bring them along with us on this exciting journey in the current congress environment.

Many people have become a little tired of virtual events. What recommendations can you give to make them as interesting and interactive as possible for the participants?

Nicole Lange:
The experiences over the past few months have shown us that digital events benefit from professional tools that work with interactive elements to enable participants to be actively involved. Professional studio conditions and experienced camera teams also create an atmosphere that is a world apart from dull video formats.
Simply shifting an in-person format 1:1 to a digital format is not attractive. The proven limited attention span of participants looking at screens demands a snappy, streamlined, and diverse programme. A well developed production plan is very helpful here.
Naturally presented, short lectures with the speaker looking into the camera, a rhetorically experienced pair of moderators from the particular discipline, and a question and answer session bring the format to life, making it exciting and interesting.

Thomas Miltz:
By positioning a product segment in the planned programme, companies can provide a diversion, present their innovations, and generate very important leads through interactions with their on-screen clientele.

With the success of the worldwide vaccination programmes, the first in-person events will soon take place again. From your point of view, what should be considered when planning and hosting such an event in the second half of 2021 and spring of 2022?

Thomas Miltz:
Despite all the progress that has been made, COVID-19 will be with us for a while yet. When planning in-person events, it is important to find out early about the latest regulations and the hygiene concepts required for the individual venues and to find a suitable location that enables the provisions

to be implemented. Cooperation between event organizers, the venue, and local health authorities is essential.
The additional costs associated with hygiene requirements and COVID-19 protection measures must also be taken into account: Providing sufficient disinfection, masks, rapid testing, and so on are just some of the key points.
The safety of every event is the top priority and is critical for its implementation and success!



How do you see the future of congresses and continuing medical education? Which trends do you think will prevail or even develop further?

Nicole Lange:
The pandemic boosted the trend toward digital continuing education formats.
At the same time, it made it abundantly clear to us how important interpersonal relationships are and how much we long for personal encounters in these times when contact between people is restricted.

We believe that the future will be characterized by hybrid meetings that satisfy all the various needs. Participants who do not want to travel to a congress can connect digitally and manage their continuing education account using professional tools. For the event, this additional format may represent a boost in participant numbers.

Thomas Miltz:
For companies, the type of patronage they provide for congresses is currently being reconsidered. For them, it is necessary to design attractive digital products. For larger congresses it is recommended, for example, to construct a streaming platform on which all videos and sessions are transmitted directly as well as being recorded. The audience chooses between the live experience or the on-demand contents. Virtual stands, break-out sessions, and different banner placements are already trends that are increasingly in use.
The future will no doubt have many exciting formats and challenges in store for us.
Despite all the changes and uncertainties, one trend is sure: We'll meet again!

ABOUT THE AUTHORS

Nicole Lange
Intercongress
Teamleitung Marketing/Head of Marketing

Thomas Miltz
Intercongress
Teamleitung Industrie/Head of Industry

IBRA Scholarship at the Department of Oral and Maxillofacial Surgery, Faculdade de Odontologia,UNESP, Araraquara, Brazil

Fellowship Director: Prof. Mario Gabrielli MD, DMD

Scholarship Program C from October 14, 2018 to January 14, 2019

Dr. Dr. Daniel Holzinger
Medizinische Universität Wien
Universitätsklinik für Mund-, Kiefer- und Gesichtschirurgie
Vienna
Austria

This document aims to provide information and insight into my IBRA internship at UNESP Faculdade de Odontologia in Brazil, that I participated in at the end of the year 2018.

Why Brazil, Why IBRA?

As a specialist in oral and maxillofacial surgery, I had been looking to participate in a scientific scholarship program that would develop my knowledge and skills in orthognathic surgery, oral rehabilitation and facial esthetics.
I am grateful to Prof. Emeka Nkenke, who made me aware of the IBRA scholarship program in Brazil. I got in touch with Prof. Mario Gabrielli and received the grant for my stay at the UNESP, Department of Oral and Maxillofacial Surgery Araraquara, Brazil.

14th COPAC-Congresso Paulista de Chirurgia e Traumatologia Buco-Maxilo-Facial

In October, Prof. Mario Gabrielli invited me to the COPAC congress in Ribeirão Preto, which is a national scientific congress of OMF professionals. The 4 days at COPAC were an excellent forum for collecting and sharing knowledge on techniques in oral and maxillofacial surgery with colleagues from all around the São Paulo state.

Santos Day Hospital, SP

At the end of November, I visited Santos Day Hospital to learn about esthetic and facial esthetic surgical procedures. In Santos, I was also involved in the planning of orthognathic surgical procedures in Prof. Fued's office, which was a very fascinating and enriching experience.

Working in the Outpatient Department of the UNESP

Research and Lectures

In December, I returned to Araraquara and attended a course on Botox, Fillers and Facial Harmonization. This well-organized practical training course was focused on the use of minimally invasive techniques in facial esthetics.

Besides regular team discussions about surgical cases, lectures on the diagnostic and surgical techniques in oral and maxillofacial surgery took place at UNESP every Friday, which improved my in-depth knowledge of this field.

In cooperation with some of my UNESP colleagues, I have started some very promising research projects to be finalized and published in 2019/2020, part of them under the prerequisite of follow-up meetings on-site.

I would like to take the opportunity to kindly thank the IBRA Scholarship Committee, as well as Prof. Mario Gabrielli and his team for all their support and for giving me the opportunity to take part in this exceptional experience!

Working in the OR with Prof. Gabrielli in Santa Casa Hospital

São Paulo State University

São Paulo, Brazil
Dental School at Araraquara, SP
Fellowship Director: Mario F. R. Gabrielli

The Division of Oral and Maxillofacial Surgery (Department of Diagnosis and Surgery) at Araraquara, São Paulo, is based at the São Paulo State University (UNESP). Ambulatory surgical activities are developed at the Dental School, whereas emergency and hospital surgical procedures are performed mainly at three hospitals:
Santa Casa, Beneficência Portuguesa and Hospital São Paulo.
Our division is based at Araraquara, which has a population of 200,000 people; however, it receives patients from a wide area within the São Paulo State in south-eastern Brazil, with a population of about 2 million, as well as from other states. Procedures performed include:

- General oral surgery procedures in general
- Osseointegrated implants and associated reconstructions
- Craniofacial traumatology
- Orthognathic surgery
- TMJ surgery
- Treatment of benign tumours and associated reconstructions
- Treatment of maxillofacial infections

For short-term fellowships of 1 to 3 months, our division is most suitable for clinical training in the fields of facial traumatology and orthognathic surgery. Longer fellowship periods, up to 18 months, require specific documentation and thus should be planned 12 months in advance. In such a case, participation in a research project in the areas of biomaterials or bone healing of the craniofacial skeleton can be made available.

A dense global grid of training centers provides an interesting range of options for scholarship applicants

Upper Limbs

Argentina
Hospital Italiano, Buenos Aires
ClimBA, Buenos Aires

Australia
John Hunter Hospital, Newcastle
Dandenong Hospital, Melbourne

Austria
Unfallkrankenhaus Lorenz Böhler, Vienna
Medical University of Innsbruck

Brazil
Instituto Nacional de Traumatologia e Ortopedia, Rio de Janeiro
Beneficência Portuguesa Hospital, São Paulo
Medical School of University of São Paulo
Albert Einstein Israelite Hospital, São Paulo
Instituto Vita, Department of Hand, Wrist & Microsurgery Surgery and Department of Shoulder & Elbow Surgery, São Paulo

Chile
Santa Maria Clinic, Santiago

Colombia
Medellín Health Centers, Medellín

Germany
Elisabeth Hospital Ravensburg
Universiy Hospital Cologne
University of Würzburg
Klinikum rechts der Isar, Munich

Italy
Policlinico of Modena
Policlinico GB Rossi, University Hospital Verona
Galeazzi Hospital - Hand Surgery Unit, Milan

Netherlands
Maastricht University Medical Center

South Korea
Seoul National University Bundang Hospital
Korea University Medicine Anam Hospital

Spain
Centro Medico Teknon, Barcelona

Switzerland
Kantonsspital of St. Gallen

United Kingdom
Wrightington Hospital
Guy's and St Thomas' NHS Foundation Trust, London

USA
Badia Hand to Shoulder Center, Miami
Banner Good Samaritan Medical Center, Phoenix

For detailed information, please visit our website.

Lower Limbs

Argentina
Austral University Hospital, Orthopedic and Traumatology Department, Buenos Aires

Australia
John Hunter Hospital, Newcastle
Nepean Hospital, Orthopaedic, Kingswood

Brazil
Paulista School of Medicine - Federal University of São Paulo
Albert Einstein Israelite Hospital, São Paulo
Instituto Vita, Department of Foot & Ankle Surgery, São Paulo

Chile
Santa Maria Clinic, Santiago

Germany
Medical School at Diakovere Annastift, Hannover

Japan
Laketown Orthopaedic Hospital, Koshigaya

Spain
Hospital Universitario de Canarias, Tenerife

Switzerland
Swiss Ortho Center, Basel
Kantonsspital Winterthur

United Kingdom
Trauma and Orthopaedic Department of the North West Anglia NHS Foundation Trust, Peterborough

Head

Brazil
São Paulo State University
Samaritano Higienópolis Hospital São Paulo

France
University of Amiens
University of Lille

Germany
University of Münster
University Hospital of Giessen and Marburg

Italy
Sapienza Università di Roma

Switzerland
Inselspital University Hospital of Bern

United Kingdom
Sheffield Teaching Hospitals

Biomechanical evaluation of midfoot fixation

Leif Claaßen

INTRODUCTION

Precise anatomic and biomechanical knowledge is crucial [1-4]. Evaluating the effectiveness of different fixation techniques for midfoot fusion from a biomechanical standpoint is important. However, most previous biomechanical studies assessing fixation techniques of the midfoot focused on a single isolated joint (usually the TMT-1 joint), and evaluated maximum load to failure under multiple cyclic loads [5-11]. They have not identified a specific approach as being better [5-7,9-11].
We biomechanically evaluated different fixation techniques simulating midfoot fusion to evaluate the effect of joint fixation on the respective joint and the adjacent joints using locking plate and lag screw constructs.

MATERIAL AND METHODS

We evaluated TMT 1-3 fusion with two different fixation techniques (locking plate with lag screw and crossed lag screws) and NC I-III fusion with three different fixation techniques (locking plate with lag screw, crossed lag screws, and bridging locking plates with lag screw).
The rotation of the NC or TMT joints and IC joints was evaluated using an optical measurement system (Optotrak Certus®, Northern Digital Inc., Waterloo, ON, Canada). The navicular and cuneiform bones or the metatarsal 1-3 bones and the cuneiform bones were equipped with three individual markers each via Kirschner wires. The testing steps for each group consisted of an evaluation of marker position without axial load or tendon pull (step 1) and an evaluation of marker position after application of a 300 N axial load on the shank with foot and 10 N pull force each on the tibialis posterior tendon, both peroneal tendons, and Achilles tendon (Step 2). The primary outcome parameter was the degree of rotation between steps 1 and 2 for each joint. The implant material consisted of locking T-plates and locking wing plates as well as 3.0 and 5.0 cannulated double-threaded lag screws (Aptus® 2.8 and Speedtip® CCS 3.0 and 5.0, Medartis® AG, Basel, Switzerland).

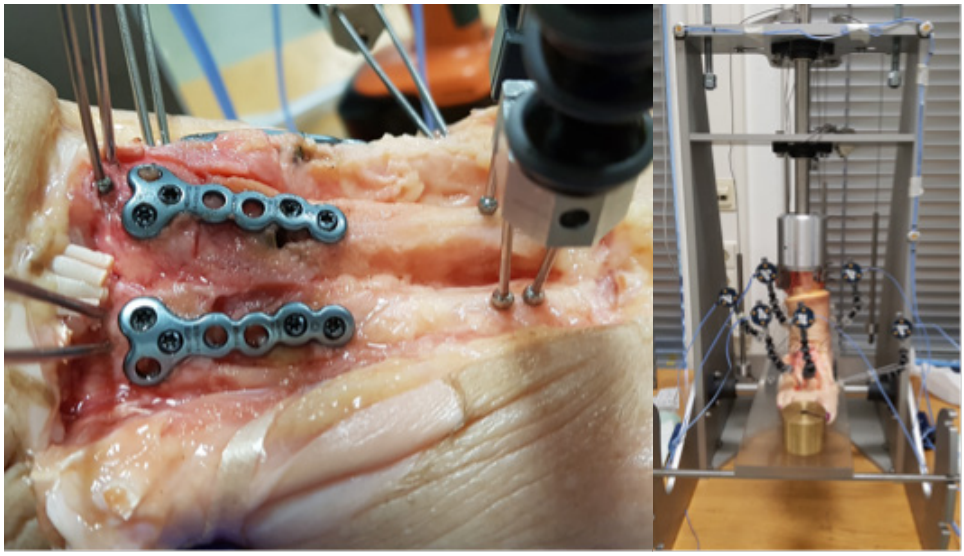

Fig. 1 Experimental setup and exemplary illustrated implants after TMT 2/3 fusion.

RESULTS

Each fixation construct led to a significantly reduced rotation of the respective joint. For TMT joints, locking plate constructs were superior compared to lag screw osteosynthesis. During NC joint fixation, we also evaluated the 3.0 CCS screws, which generally provided comparable stability. While TMT joint fixation has no effect on intercuneiform rotation, fixation of the adjacent NC joints significantly reduces the rotation of the intercuneiform joint.

CONCLUSION

The research carried out provides a biomechanical evaluation of TMT and NC joint fixation using different osteosynthesis techniques. The results showed that all approaches reduced TMT or NC joint rotation. Fixation of NC-1 had no statistically relevant effect on joint rotation of NC-2 or NC-3. Isolated fixation of the NC-2 and/or NC-3 led to a significantly reduced rotation of these joints without requiring NC-1 fixation. The studies showed, more for TMT compared to NC joints, the superiority of locking plate constructs compared to lag screw constructs. Our study regarding NC joints is already published [12].

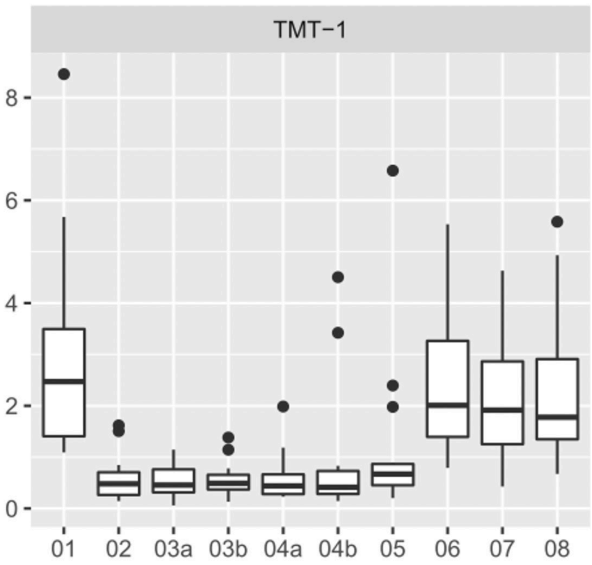

Fig. 2 Biomechanical evaluation of fixation of TMT-1 fixation. Application of locking plate and lag screw significantly reduced rotation of TMT-I, whereas rotation increased again after implant removal.

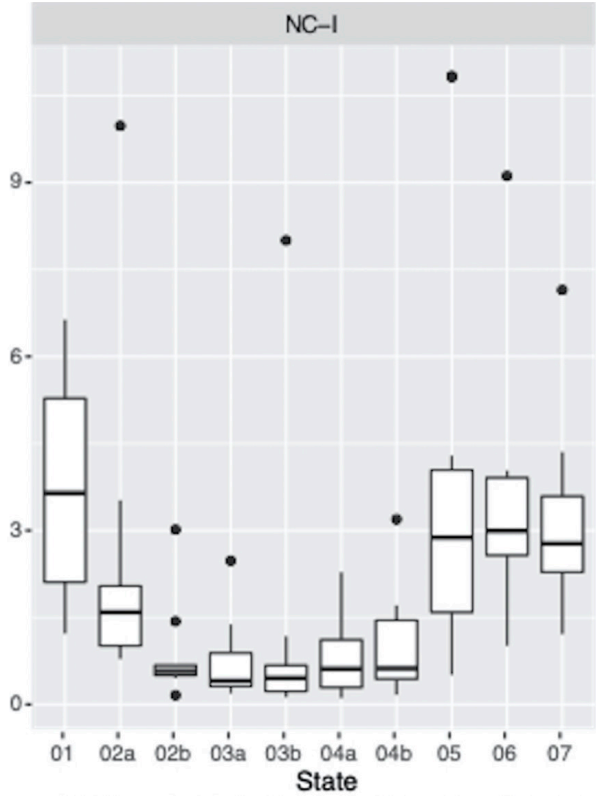

Fig. 3 Biomechanical evaluation of fixation of NC-1 fixation. Application of locking plate and lag screw significantly reduced rotation of TMT-I, whereas rotation increased again after implant removal.

ABOUT THE AUTHOR

PD Dr. Leif Claaßen
DIAKOVERE Krankenhaus gGmbH
Orthopädische Klinik der Medizinischen Hochschule Hannover (MHH) im DIAKOVERE Annastift
Anna-von-Borries-Straße 1-7
30625 Hannover-Kleefeld

REFERENCES

1. *Roling BA, Christensen JC, Johnson CH.*
Biomechanics of the first ray. Part IV: The effect of selected medial column arthrodeses. A three-dimensional kinematic analysis in a cadaver model.
J Foot Ankle Surg. 2002;41(5):278-285.
doi:10.1016/s1067-2516(02)80045-x

2. *Swanton E, Fisher L, Fisher A, Molloy A, Mason L.*
An anatomic study of the naviculocuneiform ligament and its possible role maintaining the medial longitudinal arch.
Foot Ankle Int. 2019;40(3):352-355.
doi:10.1177/1071100718811638

3. *Whittaker EC, Aubin PM, Ledoux WR.*
Foot bone kinematics as measured in a cadaveric robotic gait simulator.
Gait Posture.2011;33(4):645-650. doi:10.1016/j.gaitpost.2011.02.011

4. *Renner K, McAlister J, Galli M, Hyer C*
Anatomic. Description of the Naviculocuneiform Articulation.
J Foot and Ankle Surgery 2017 Jan-Feb;
doi.org/10.1053/j.jfas.2016.09.013

5. *Baxter JR, Mani SB, Chan JY, Vulcano E, Ellis SJ.*
Crossed-screws provide greater tarsometatarsal fusion stability compared to compression plates.
Foot Ankle Spec. 2015;8(2):95-100.
doi:10.1177/1938640014543358

6. *Cottom JM, Baker JS.*
Comparison of locking plate with interfragmentary screw versus plantarly applied anatomic locking plate for lapidus arthrodesis: A biomechanical cadaveric study.
Foot Ankle Spec. 2017;10(3):227-231.
doi:10.1177/1938640016676341

7. *Klos K, Simons P, Hajduk AS, et al.*
Plantar versus dorsomedial locked plating for Lapidus arthrodesis: A biomechanical comparison.
Foot Ankle Int. 2011;32(11):1081-1085.
doi:10.3113/FAI.2011.108113

8. *Prieto-Diaz C, MPH, Anderle M, Brinker L, DPM.*
Biomechanical Comparison of First Tarsometatarsal Arthrodesis Constructs Over Prolonged Cyclic Testing.
Foot & Ankle Orthopaedics. 2019;4(4).
doi:10.1177/2473011419892240

9. *Roth KE, Peters J, Schmidtmann I, Maus U, Stephan D, Augat P.*
Intraosseous fixation compared to plantar plate fixation for first metatarsocuneiform arthrodesis: A cadaveric biomechanical analysis.
Foot Ankle Int. 2014;35(11):1209-1216.
doi:10.1177/1071100714547082

10. *Scranton PE, Coetzee JC, Carreira D.*
Arthrodesis of the first metatarsocuneiform joint: a comparative study of fixation methods.
Foot Ankle Int. 2009;30(4):341-345. doi: 10.3113/FAI.2009.0341

11. *Alberta F, Aronow M, Barrero M, Diaz-Doran V, Sullivan RJ, Adams DJ.*
Ligamentous lisfranc joint injuries: A biomechanical comparison of dorsal plate and transarticular screw fixation.
Foot Ankle Int. 2005;26(6):462-473.
doi:10.1177/107110070502600607

12. *Kuestermann H, Ettinger S, Yao D, Schwarze M, Plaass C, Stukenborg-Colsman C, Claassen L.*
Biomechanical evaluation of naviculocuneiform fixation with lag screw and locking plates.
Foot Ankle Surg. 2021 Jan 16:S1268-7731(20)30279-4. doi: 10.1016/j.fas.2020.12.008.
Online ahead of print.

Management of mandible fracture using a three-dimensional (3D) miniplate System

Lauren Bohner, Fabian Beiglboeck, Johannes Kleinheinz, Susanne Jung

ABSTRACT

The purpose of this study was to evaluate the use of a three-dimensional (3D) miniplate system for the treatment of mandibular fractures. In total, 336 patients and 391 mandibular fractures were assessed. The most common fracture site was the anterior mandible, and 155 cases involved a tooth-bearing area. Minor complications were seen in 8.03% of cases, whereas only 1.49% of patients suffered from major complications. The treatment of mandible fractures using 3D miniplates resulted in fracture reduction with a low complication rate.

Keywords: mandibular fracture; jaw fracture; maxillofacial injuries

EXTENDED ABSTRACT

Extended Abstract

In the management of mandible fractures, a successful osteosynthesis can be achieved with three-dimensional (3D) miniplate systems.[1-5] In comparison to conventional plates, they show improved initial stability and biomechanical behavior by means of simultaneous stabilization of tension and compression areas.[3,5] Previous studies showed a reduction of 58% in post-operative of complications using 3D miniplates.[6,7] In this retrospective study, we assessed the management of mandibular fractures with 3D miniplate systems on patients treated at the University Hospital Münster over 5 years. The inclusion criteria were the presence of mandibular fractures treated with a 3D miniplate system (Trauma 2.0, Medartis, Basel, Switzerland). The use of alternative techniques, condylar fracture and minimal fractures treated with conservative approaches were excluded from this analysis. Patient data, surgical protocol, intra- and post-operative complications were assessed.

The surgical procedure began with an intra-oral vestibular incision and raising of a mucoperiosteal flap. After reducing bone fragments into their anatomical position, intermediate intermaxillary fixation (IMF) was performed using wire ligature or IMF screws to ensure adequate occlusion. Fracture osteosynthesis of the fracture was performed using the 3D miniplate system (Trauma 2.0, Medartis, Basel, Switzerland). Plates were adapted to the bone anatomy and fixed to the cortical bone using monocortical 2.0 mm screws (Fig. 1 and 2). After IMF removal and proof of occlusion, incision closure was performed with 3.0 Vicryl sutures. When necessary, a postoperative IMF was applied to stabilize the occlusion using wire ligature, IMF screws, or head-chin bandages. Patients were hospitalized for 3 to 7 days. During this period, patients received a liquid diet or enteral nutrition, and a soft diet was recommended for the first 30 days after the procedure. Analgesia was prescribed in case of pain, and antibiotic therapy (co-amoxiclav 875/125 mg; in case of penicillin allergy: clindamycin 600 mg) was prescribed for a period of 5–7 days to prevent bacterial infection.

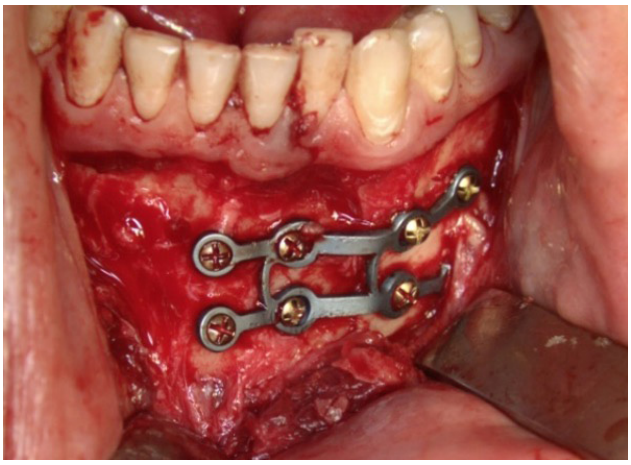

Fig. 1. Internal fixation of the anterior fracture using the M-4484 plate (Medartis Trauma 2.0).

Fig. 2. Double mandibular fracture treated with two grid plates (Modus Trauma 2.0, Medartis).

Over five years, 391 mandibular fractures were treated with a 3D miniplates (Trauma 2.0, Medartis, Basel, Switzerland). In summary, most of the patients were male (73.5%), and the mean age ranged between 21–40 years. Seventy patients presented a medical comorbidity, and 22 of them required some medication. The main causes of fractures were interpersonal violence acts (38.7%) and accidents (35.41%). The most common fracture sites were the anterior mandible, the mandibular angle, and the body of the mandible.

In 87.79% of cases, there was a minor displacement of bone fragments, and the gap between fractured sites was less than 1 mm. Furthermore, in 89.3% of cases, no displacement was seen on panoramic radiography.

Eighty patients experienced no pain (23.8%), whereas 150 suffered only mild pain. Moderate and severe pain were reported by 96 (28.6%) and eight patients (2.4%), respectively. Minor post-operative complications were observed in 8.03% of the patients, which were treated with antibiotic therapy and local procedures. Only 1.48% of the patients presented major complications (Table 1). No plate fracture was reported, and no plate was lost due to complications, although screw loosening occurred in 1.78% of cases. Due to infectious or technical complications, the plate had to be replaced in five patients (1.5%).

Table 1. Minor and major post-operative complications

Post-operative complications		Number of patients (n)
Minor complications		
	Infections	Total: 10
	- Abscess	6
	- Fistula	2
	- Local infiltration	1
	- Osteomyelitis	1
	Dehiscence or healing complications	26
	Plate exposition	2
	Sensibility disturbance	Total: 156
	- Before plate removal	156
	- After plate removal	22
	Screw loosening	6
Major complications		
	Pseudoarthrosis	2
	New plate insertion	5

CONCLUSION

Within the limitations of this study, the treatment of mandible fractures using 3D miniplates resulted in fracture reduction with a low complication rate and an adequate surgical procedure time.

REFERENCES

1. *Moore, E.; Bayrak, S.; Moody, M.; Key, J.M.; Vural, E.*
Hardware removal rates for mandibular angle fractures: Comparing the 8-hole strut and champy plates.
J. Craniofac. Surg. 2013, 24, 163–165.

2. *Höfer, S.H.; Ha, L.; Ballon, A.; Sader, R.; Landes, C.*
Treatment of mandibular angle fractures line obliqua plate versus grid plate.
J. Craniomaxillofac. Surg. 2012, 40, 807–811.

3. *Wusiman, P.; Yarbag, A.; Mijiti, A.; Moming, A.*
Three dimensional versus standard miniplate fixation in management of mandibular fractures: A systematic review and meta-analysis.
J. Craniomaxillofac. Surg 2016, 44, 1646–1654.

4. *Singh, A.; Arunkumar, K.V.*
Standard 3D titanium miniplate versus locking 3D miniplate in fracture of mandible: A prospective comparative study.
J. Maxillofac. Oral Surg. 2016, 15, 164–172.

5. *Hochuli-Vieira, E.; Ha, T.K.L.; Pereira-Filho, V.A.; Landes, C.A.*
Use of rectangular grid miniplates for fracture fixation at the mandibular angle.
J. Oral Maxillofac. Surg. 2011, 69,1436–1441.

6. *Al-Moraissi, E.A.; El-Shawkawy, T.M.; El-Ghareeb, T.I.; Chrcanovic, B.R.*
Three-dimensional versus standard miniplate fixation in the management of mandibular angle fractures: A systematic review and meta-analysis.
Int. J. Oral Maxillofac. Surg. 2014, 43, 708–716.

7. *Al-Moraissi, E.A.; Ellis, E.*
What method for management of unilateral mandibular angle fractures has the lowest rate of postoperative complications? A systematic review and meta-analysis.
J. Oral Maxillofac. Surg. 2014, 72, 2197–2211.

ABOUT THE AUTHORS

Lauren Bohner *,†, [1]

Fabian Beiglboeck †, [1]

Johannes Kleinheinz, [1]

Susanne Jung, [1]

[1] Department of Oral and Maxillofacial Surgery, University Hospital Münster, 48149 Münster, Germany
* Correspondence: lauren.bohner@ukmuenster.de; Tel: +4925183-47004
† Joint first authors

Surgical treatment of chronic anterior radial head dislocations in missed Monteggia lesions in children:

A rationale for treatment and the pearls and pitfalls of surgery

Lisette C. Langenberg, Denise Eygendaal

INTRODUCTION

Children with a chronic radial head dislocation following a Monteggia lesion may develop several complaints in the affected elbow, such as pain, deformity of the joint, loss of range of motion (ROM) and neurological complaints. The ulna is thereby relatively shortened, which may lead to complaints at the level of the wrist and lower arm. Therefore, reduction of the radial head should take place as soon as possible to prevent these long-term harmful effects. Corrective surgery may include debridement of the radiocapitellar joint, ulna osteotomy, annular ligament reconstruction or radiocapitellar K-wire fixation.

MECHANISM OF INJURY AND THE EFFECT OF GROWTH

If a Monteggia fracture occurs, the interosseous membrane ruptures. Consequently, the tension on the radial shaft and radial head is reduced, allowing it to dislocate. This mechanism explains why over 70% of radial head dislocations are in an anterior direction (Bado type I). The annular ligament may rupture or dislocate from the radial head, and migrate into the proximal radioulnar joint, interfering with reduction of the radial head. During growth, ulnar angulation may develop, which may result in persistent dislocation of the radial head. Treatment ideally should address all components of the injury: providing reduction of the radial head, correction of ulnar length and angulation, and reconstruction of the annular ligament (Fig. 1).

PREOPERATIVE WORKUP

Kim et al. described a head–neck ratio (Fig. 2) which may help to assess dysmorphic features. However, the consequences of a higher ratio are unclear, other than that the surgeon has to be aware of more difficult repositioning of the radial head due to anatomical anomalies. It is unknown how surgical outcome is influenced by dysmorphic features of the radial head or by the time between trauma and surgery.

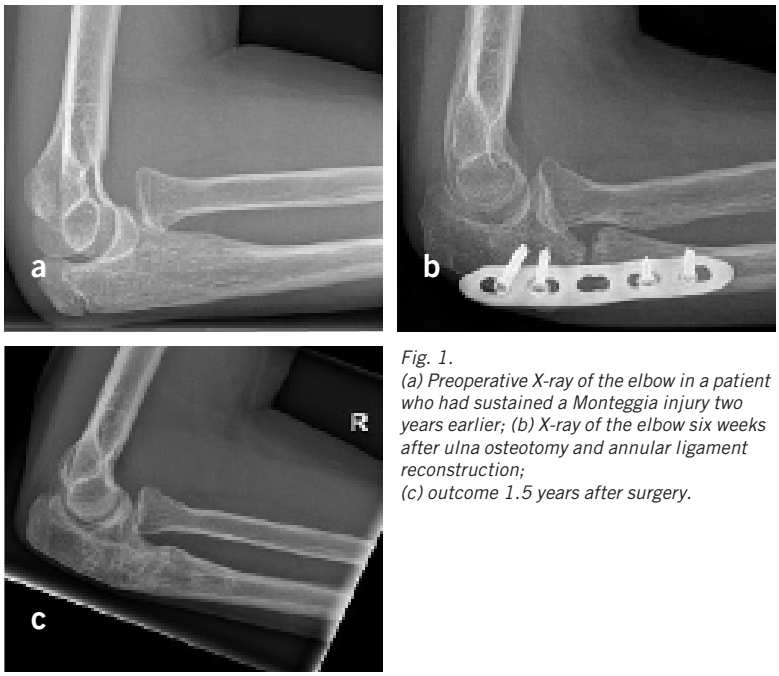

Fig. 1.
(a) Preoperative X-ray of the elbow in a patient who had sustained a Monteggia injury two years earlier; (b) X-ray of the elbow six weeks after ulna osteotomy and annular ligament reconstruction;
(c) outcome 1.5 years after surgery.

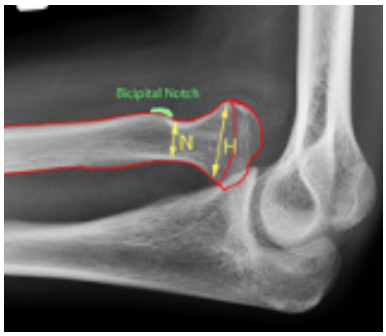

Fig. 2.
Head-neck ratio for the assessment of radial head deformity[22].

RADIOULNAR DEBRIDEMENT

Open reduction of the radial head has several advantages; even in repositioned radial heads, annular ligament remnants may interpose in the radiohumeral joint. In series of cases at our hospital, we noticed that radial head reduction may be hindered by interpositioning remnants of the annular ligament or fibrosis. Thereby, a posterior interosseous nerve (PIN) subluxation or incarceration in the PRUJ or radiocapitellar joint (RCJ) may be identified when performing an open reduction.

ULNA OSTEOTOMY

Many authors described a stable situation following ulna osteotomy, in which subsequent annular ligament reconstruction was not always necessary. The location of the osteotomy should be as proximal as possible. Thus, by increasing interosseous membrane tension, pulling forces on the radius in a reducing direction are increased. In our experience, planning the osteotomy as proximal as possible also yields the advantage of a wider bone diameter in the proximal part of the ulna, resulting in a firmer grip and a larger contact surface. Thereby, metaphysal bone has a higher potency for bone healing than diaphysal bone. Angulation at the metaphyseal level has less effect on reduction, but it allows for more precise adjustment. An osteotomy at the center of rotation and angulation may predispose the site to non-union.

Ulnar lengthening may be considered a key part of surgery. Restoring ulnar length prevents excessive pressure on the radial head and corrects the proximal shift of the radial head. The osteotomy may be planned either straight, oblique or as a Z-lengthening ulna osteotomy. The risk of postoperative redislocation of the radial head is lower following bending and elongating ulna osteotomy than in a simple transverse osteotomy of the ulna, intended only to straighten the ulna. Presumably, this slight “overcorrection” results in extra tension on the interosseous membrane, facilitating reduction of the radial head.

Acute lengthening of up to 1 cm has been advocated despite the risk of delayed union and failure of fixation. In most cases, acute ulnar lengthening of 2 to 5 mm is sufficient and does not delay osseous union. One of the pitfalls when lengthening the ulna is that osteotomy site distraction may lead to ulnar nerve palsy in a high percentage of cases.

ULNA FIXATION TECHNIQUES

One of the advantages of rigid fixation may be that early mobilization is facilitated and postoperative contractures may thus be prevented. A lateral location of the plate for ulna fixation may lead to non-union of the osteotomy. According to the tension band principle, a posterior plate may be preferred.

ANNULAR LIGAMENT RECONSTRUCTION (ALR)

Some surgeons state that ALR is unnecessary and only leads to a more extensive approach and possible additional complications. Some, however, claim that ALR is an important stabilizer in radial head reduction. The consensus seems to be that ALR may contribute to the stability of radial head reduction, but it cannot stabilize the radial head when the forearm is malaligned. If there is persistent radial head instability when the forearm is brought to pronation after ulna osteotomy, ALR may be considered, but we advise an attempt to optimize the ulnar osteotomy in this situation.

ALR has been associated with postoperative loss of pronation, especially if the annular ligament reconstruction is not properly tensioned. Too much annular ligament tension may also result in hourglass deformation of the radial neck. Other complications of ALR are ossification of a portion of the reconstructed annular ligament and osteolytic changes, of which the clinical impact is still uncertain.

TRANSCAPITELLAR/RADIOULNAR KIRSCHNER-WIRES

A transcapitellar K-wire may be considered if persisting instability is suspected after completing ulna osteotomy and annular ligament reconstruction; it may contribute to the postoperative stability of the radial head. There have been cases of re-dislocation following removal of the K-wire. Heterotopic ossification may occur, influencing pronation and supination; material may break, migrate or, on rare occasions, cause infection. Thus, if additional stability is required, we favor radioulnar K-wire fixation, because it has the advantage that no joint surfaces are damaged.

CONCLUSION

We state that ulna osteotomy, adequate ulnar correction by bending and elongating, and rigid ulna fixation are the keys to reducing the radial head, and that reconstruction of the annular ligament or a radioulnar K-wire may contribute to stability. The decision to operate should be weighed in every individual case, informing the patient and their parents well about the benefits of surgery and the potential effects on range of motion, the possibility of redislocation and and the risk of nerve damage, especially to the PIN. A preoperative CT scan may help to assess the degree of radial head deformation, though no certainty may be given about its potential influence on the outcome of surgical treatment.

REFERENCES

1. *Bhaskar A.*
   Missed Monteggia fracture in children: Is annular ligament reconstruction always required?
   Indian J Orthop. 2009 Oct;43(4):389-95

2. *David-West KS, Wilson NI, Sherlock DA, Bennet GC.*
   Missed Monteggia injuries.
   Injury. 2005 Oct;36(10):1206-9.

3. *Goyal T, Arora SS, Banerjee S, Kandwal P.*
   Neglected Monteggia fracture dislocations in children: a systematic review.
   J Pediatr Orthop B. 2015 May;24(3):191-9.

4. *Hui JH, Sulaiman AR, Lee HC, Lam KS, Lee EH.*
   Open reduction and annular ligament reconstruction with fascia of the forearm in chronic monteggia lesions in children.
   J Pediatr Orthop. 2005 Jul-Aug;25(4):501-6.

5. *Kim HT, Park BG, Suh JT, Yoo CI.*
   Chronic radial head dislocation in children, Part 2: results of open treatment and factors affecting final outcome.
   J Pediatr Orthop. 2002 Sep-Oct;22(5):591-7.

6. *Langenberg L, Beumer A, The B, Koenraadt K, Eygendaal D.*
   Surgical treatment of chronic anterior radial head dislocations in missed Monteggia lesions in children: A rationale for treatment and pearls and pitfalls of surgery.
   Shoulder & Elbow. 2020;12(6):422-431.

7. *Nakamura K, Hirachi K, Uchiyama S, Takahara M, Minami A, Imaeda T, Kato H.*
   Long-term clinical and radiographic outcomes after open reduction for missed Monteggia fracture-dislocations in children.
   J Bone Joint Surg Am. 2009 Jun;91(6):1394-404.

8. *Shinohara T, Horii E, Koh S, Fujihara Y, Hirata H.*
   Mid- to long-term outcomes after surgical treatment of chronic anterior dislocation of the radial head in children.
   J Orthop Sci. 2016 Nov;21(6):759-765.

9. *Stragier B, De Smet L, Degreef I.*
   Long-term follow-up of corrective ulnar osteotomy for missed Monteggia fractures in children.
   J Shoulder Elbow Surg. 2018 Nov;27(11):e337-e343.

Publication of the original article:

10. *Langenberg L, Beumer A, The B, Koenraadt K, Eygendaal D.*
    Surgical treatment of chronic anterior radial head dislocations in missed Monteggia lesions in children: A rationale for treatment and pearls and pitfalls of surgery.
    Shoulder & Elbow. 2020;12(6):422-431.
    doi:10.1177/1758573219839225

ABOUT THE AUTHORS

Drs Lisette Langenberg
Orthopedic Surgery Resident
Main focus: Elbow Surgery,
Hand and Wrist Surgery
NoordWest Ziekenhuisgroep, Alkmaar,
Wilhelminalaan 12, 1815 JD Alkmaar, the Netherlands

Prof. Dr. Denise Eygendaal
Consultant Orthopedic Surgeon
Main focus: Elbow Surgery
Erasmus University
Dr Molenwaterplein 40
Rotterdam; the Netherlands

Dorsal transosseous reduction and a locking plate fixation for intra-articular middle phalanx base fracture

Ji Hun Park, Geun Woo Park, In Cheul Choi, Young Woo Kwon, Jong Woong Park

INTRODUCTION

Comminuted intra-articular fractures at the base of the middle phalanx remain challenging to treat[1]. Furthermore, a depressed fragment at the base of the middle phalanx can be an obstacle to achieving congruent reduction and stable fixation. Several surgical and non-surgical treatments and surgical approaches have been devised, including distraction by an external fixator, closed or open internal fixation, and hemi-hamate arthroplasty, but no general consensus has been reached.
Closed reduction is difficult for the reduction and stabilization of the intra-articular depressed fragments[2, 3]. Open reduction and internal fixation through the volar approach is very difficult for handling complex anatomical structures such as tendons, neurovascular structures, volar plate, and joint capsules, and may require advanced proficiency[2, 4, 5].
We have used a dorsal transosseous reduction technique to achieve the congruent reduction of the impacted articular fragment without opening the joint. After the reduction of the intra-articular fragments, dorsal locking plate fixation was combined to buttress the reduced fragment and start early mobilization of the joint.

TECHNIQUE

A midline longitudinal skin incision is made on the dorsal side of the middle phalanx of the PIP joint. After careful dissection between lateral bands and distal to the insertion of central slip, a cortical window ranging from 2 mm to 3 mm in diameter is created with a high-speed burr on the dorsal cortex. The position of the cortical window is determined just distal to the impacted articular fragment under the C-arm. After gentle axial traction of the distal phalanx is applied to allow reduction of the impressed fragment, transosseous reduction is performed by manipulating the impacted fragment under C-arm with a fine-tipped instrument, such as a K-wire or microcurette, through the cortical window. When a large bone defect was created after reduction, small pieces of allogenic bone chips or bone substitutes can be inserted through the window to maintain the reduction. The reduced fracture is stabilized with a 1.5 mm locking plate (gridplate; Medartis, Basel, Switzerland). The plate is reshaped by cutting off any unnecessary parts so that it can be inserted without interfering with the extensor mechanism. Whole plates could be used, but only two rows of the plate are usually required to fix the partial articular fracture during this procedure. After reshaping the plate, the actual implanted locking plate configuration is 3 or 4 holes in most cases. At least one of the two proximal locking screws of the plate is inserted in the subchondral area to buttress the disimpacted articular fragment and grafted bone tamps (Fig. 1).

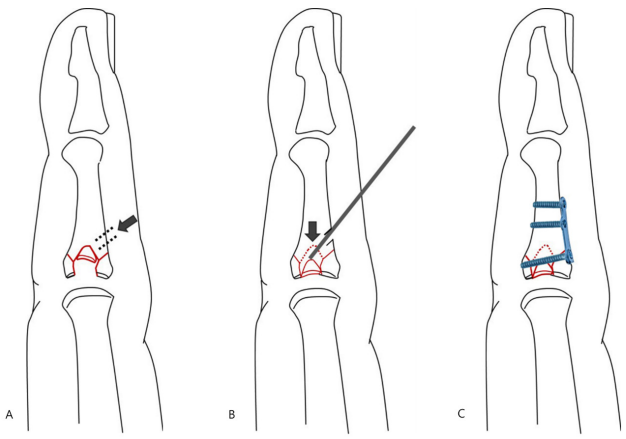

Fig. 1. Schematic drawing of the surgical technique. (A) Creating a dorsal cortical window. (B) A transosseous reduction through the window using blunt tip K-wire or microcurette. (C) 1.5 mm locking plate fixation: proximal screws buttress the reduced articular fragment and distal screw in the plate stabilizes the plate itself.

POST-OP CARE

The finger is maintained in full extension in an aluminum splint. One or two days after, depending on the patient's ability to tolerate pain, active mobilization can be initiated. Gentle passive flexion and extension exercises are added at 2 weeks, but forceful manipulation is avoided until complete union.

CASE

A 45-year-old man involved in a basketball injury sustained a volar lip fracture with a depressed intra-articular intermediate fragment. (A) An impacted fragment was identified on CT scan. (B) A cortical window was created in the dorsal bare area of the middle phalanx and the depressed fragment was reduced using a K-wire. (C) The unnecessary part of the plate was cut off to minimize interference with the extensor mechanism. (D) Postoperative radiographs showed the most proximal screw is inserted as a butressing screw.

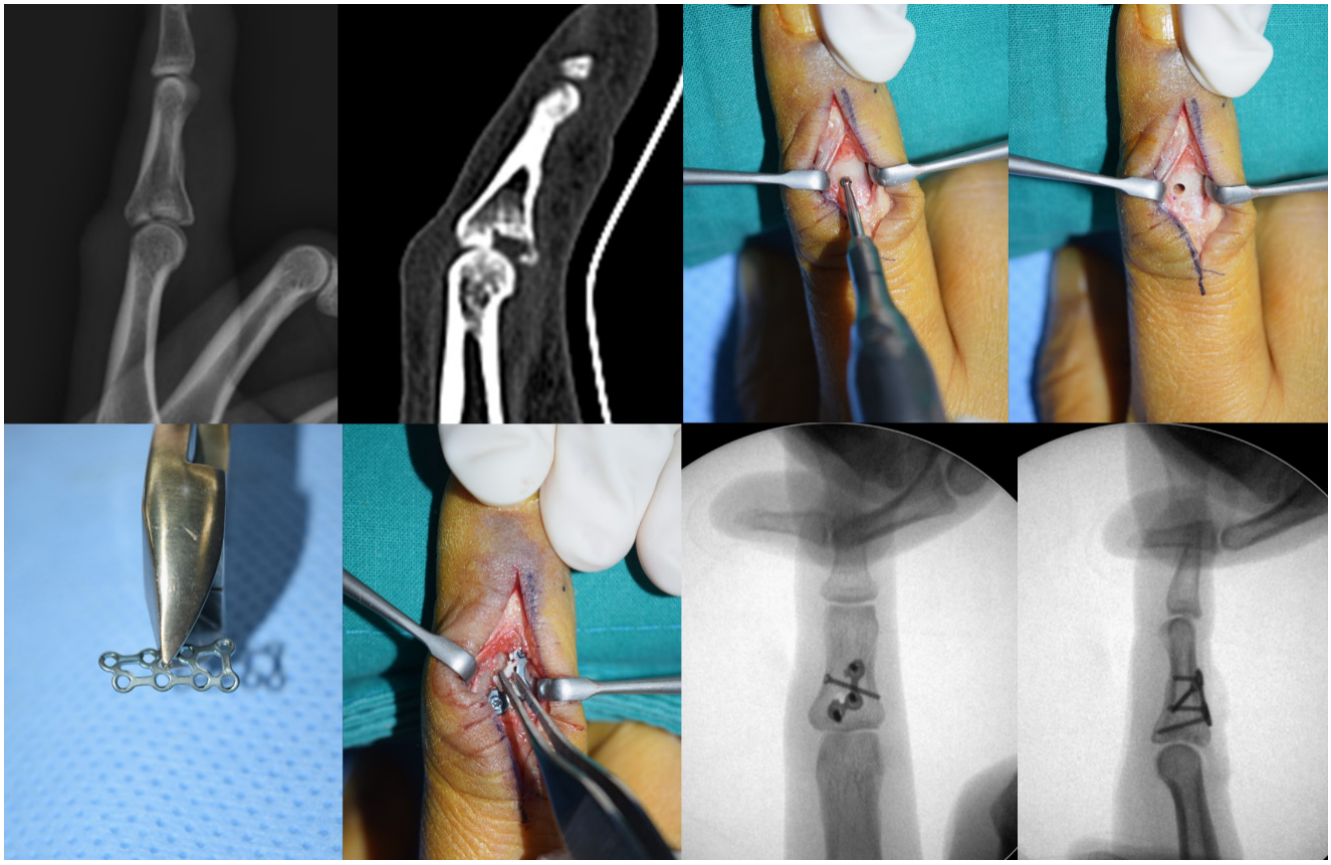

Copyright: Archives of Orthopaedic and Trauma Surgery

DISCUSSION

Surgical treatment of intra-articular fracture of the middle phalanx is often complicated by easy loss of reduction, joint stiffness, and permanent contractures arising from various fixation methods. Several treatment methods have been introduced including traction, external fixation, screw fixation, K-wire fixation, and plate fixation. However, until now, there is no consensus on the optimal treatment of these kinds of fractures.

For the internal fixation in a middle phalanx base intra-articular fracture, the volar, dorsal, or lateral approaches have been used. In the volar approach, the handling of the complex structures including nerves and vessels, FDS, FDP tendons, joint capsule, and volar plate is not easy task for the general orthopedic surgeon. Even after successfully reaching the volar surface of the fracture site, positioning the plate on the stiff and concave bony surface is very sophisticated.

A dorsal approach combined with a transosseous reduction technique is particularly useful because it allows direct control of the smaller fragments without opening the comminuted fracture site. Furthermore, the dorsal cortex of the middle phalanx is relatively flat compared to the volar side and its cortex is strong enough to fix the plate and screw. A locking plate and screws rather than screws alone are more advantageous for early ROM while having a buttressing effect on the impacted articular fragment in addition to direct screw purchase of the volar fragment.

CONCLUSIONS

For the intra-articular fracture of middle phalanx base, dorsal transosseus reduction and a locking plate fixation can obtain reliable articular reduction and early mobilization, while minimizing soft tissue injury. This technique is particularly useful when the fracture shows a depressed articular fragment and attempted closed reduction is unsatisfactory

ACKNOWLEDGMENT

The original article on this method was published in Archives of Orthopaedic and Trauma Surgery, 139(1):141-145, 2019

REFERENCES

1. *Seno N, Hashizume H, Inoue H, Imatani J, Morito Y.* **Fractures of the base of the middle phalanx of the finger. Classification, management and long-term results.** J Bone Joint Surg Br. 1997;79(5):758-63.

2. *Henry M.* **Volar, Dorsal, and Lateral Locking Plate Fixation for Pilon Fractures.** Tech Hand Up Extrem Surg. 2017;21(1):22-7.

3. *Johnson D, Tiernan E, Richards AM, Cole RP.* **Dynamic external fixation for complex intraarticular phalangeal fractures.** J Hand Surg Br. 2004;29(1):76-81.

4. *Cheah AE, Tan DM, Chong AK, Chew WY.* **Volar plating for unstable proximal interphalangeal joint dorsal fracture-dislocations.** J Hand Surg Am. 2012;37(1):28-33.

5. *Singh T, Jayawardhana R, Craigen M, Rajaratnam V.* **Volar Buttress Plating for Unstable Dorsal Fracture-Dislocations of the Proximal Interphalangeal Joint.** J Hand Microsurg. 2019;11(2):106

ABOUT THE AUTHORS

Dr. Ji Hun Park
Korea University Anam Hospital
Seoul, Korea

Dr. Geun Woo Park
Korea University Anam Hospital
Seoul, Korea

Prof. In Cheul Choi
Korea University Anam Hospital
Seoul, Korea

Prof. Young Woo Kwon
Korea University Anam Hospital
Seoul, Korea

Prof. Jong Woong Park
Korea University Anam Hospital
Seoul, Korea
(corresponding author)

Volar plate fixation of unstable scaphoid nonunion - is stability key?

Philip M. J. Schormans, Pascal F. W. Hannemann

INTRODUCTION

In the malunited scaphoid, loss of height, increased flexion and potential dorsal intercalated segment instability will result in alteration of wrist biomechanics with an acceleration of radiocarpal arthritis and impairment of function.[1, 2] Optimal treatment of scaphoid nonunion has been the subject of debate for decades. Many authors have described treatment of scaphoid nonunion using both vascularized and non-vascularized bone grafts in combination with different forms of fixation such as Kirschner wires, screws, and plates. Both the vascularization, especially of the proximal pole, and the stability of the fracture have been thought to influence the chances of union of a scaphoid fracture. Different forms of treatment have focused on improving the vascularization of the proximal pole and the stability of the fracture, or both.[2] From a mechanical point of view, a buttress plate is an alternative form of fixation to conventional compression screws in the treatment of a nonunion or a comminuted fracture. Using a buttress plate is thought to improve the stability of unstable fractures and nonunions, which tend to collapse in a volar direction. In the past few years, there has been rapid growth of experience with this technique.[3-5] This article reflects on the experiences gained with this technique and the functional outcome after follow-up of volar plate fixation with autologous bone grafting.

MATERIALS AND METHODS

Between November 2013 and June 2018, all patients who presented to our tertiary referral center with a clearly established scaphoid nonunion and a proximal pole fragment large enough to accommodate three locking screws were included in a prospective study. A proximal pole length of 5 mm on the sagittal reconstruction of the preoperative CT scans was deemed large enough to accommodate three locking screws. Patients with a scaphoid nonunion advanced collapse beyond stage I were excluded from this study. A total of 49 patients were included. The characteristics of the patients are summarized in Table I. The mean length of duration of nonunion was 3.6 years. Functional assessment consisted of range of motion (ROM), grip strength, and the patient-rated wrist/hand evaluation (PRWHE) questionnaire. For ROM, the total range of active extension and flexion was determined using a handheld goniometer, expressed as a proportion of that of the opposite, unaffected wrist. Grip strength was measured using a JAMAR (dynamometer Sammons Preston Rolyan, Bolingbrook, Illinois, USA) and expressed as a proportion of the strength of the unaffected side. Healing of the nonunion was assessed using multiplanar reconstruction CT scans. We chose to deem a nonunion healed if a minimum of 50% of the width of the scaphoid showed trabecular bridging.[6] In all cases there was an interobserver agreement between the reviewers. The plate was only removed in patients with a functional deficit or pain due to impingement by the plate on the volar lip of the distal radius.

After removal of the plate, the functional outcome was reassessed. All patients with a follow-up of > 12 months (median 31) were re-examined and functional outcome was reassessed to determine the functional outcome. Any deviation from the normal postoperative course without the need for pharmacological or surgical treatment was deemed a minor event. All other events were regarded as major.

SURGICAL TECHNIQUE

The patient was placed in supine position with the affected hand outstretched on an arm table with a tourniquet inflated to 250 mmHg around the upper arm. A modified Henry approach was used to access the radioscaphocapitate ligament. The ligament was opened, and the volar surface of the scaphoid was exposed. The nonunion was debrided, and carpal alignment was corrected using 1.2 mm Kirschner wires (K-wires). In the case of a dorsal intercalated segment instability (DISI) deformity, an extension of the lunate was corrected using a 1.6 mm K-wire. Punctate bleeding of the proximal pole was assessed after the release of the tourniquet, which correlated in all cases with the preoperative MRI. After correction of scaphoid geometry, internal fixation of the scaphoid was performed using a precontoured stable 1.5 mm miniplate (Aptus Hand; Medartis, Switzerland) (Fig. 1).

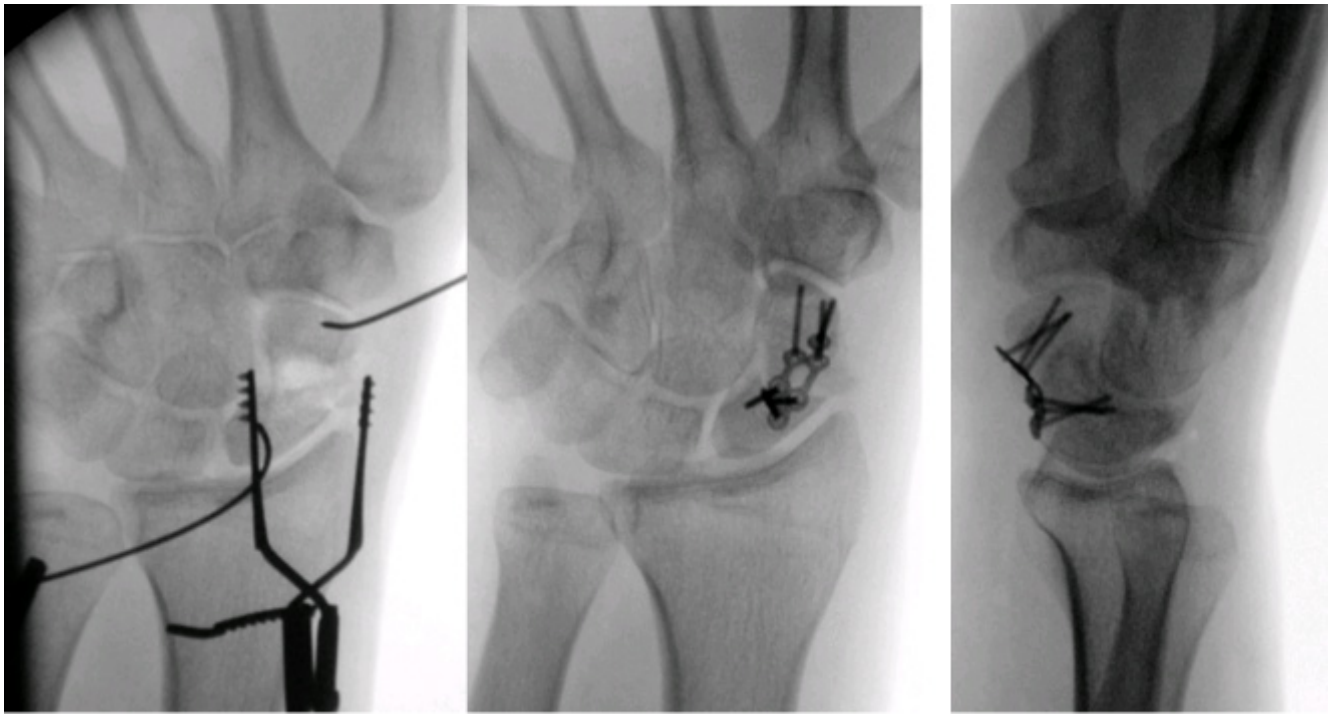

Fig. 1: After correction of the geometry, internal fixation is performed using the 1.5mm miniplate

We aimed to have three variable angled locking screws at either side of the fracture. Following fixation, the autologous cancellous bone graft was added after harvesting from the ipsilateral iliac crest. The position of the plate, scaphoid geometry, and carpal alignment were checked by fluoroscopy. The radioscaphocapitate ligament was restored with a Vicryl 3–0 suture (Ethicon) before closure of the skin. A volar wrist splint was applied postoperatively for 7 to 10 days before starting active wrist movement. After 7 to 10 days of surgery, patients visited the outpatient department to check for early complications. Patients were then submitted to a 3-month interval follow-up regime as previously subscribed.

Table 1 - patient characteristics

n = 49		
Age(years)	31	(16-74)
Sex	46/49 male	(94% male)
Smoking	13/49	(27%)
Duration of nonunion (average, months)	43	(5-192)
Sclerotic nonunion	25/49	(51%)
Proximal pole non-union	14/49	(29%)
Humpback deformity	29/49	(59%)
Avascular proximal pole (MRI)*	6/26	(23%)
DISI	29/49	(57%)
Stage I SNAC	14/49	(27%)
Previous surgery to scaphoid	12/49	(24%)

* Standardized pre-operative MRI was discontinued after 1st published series of 21 patients

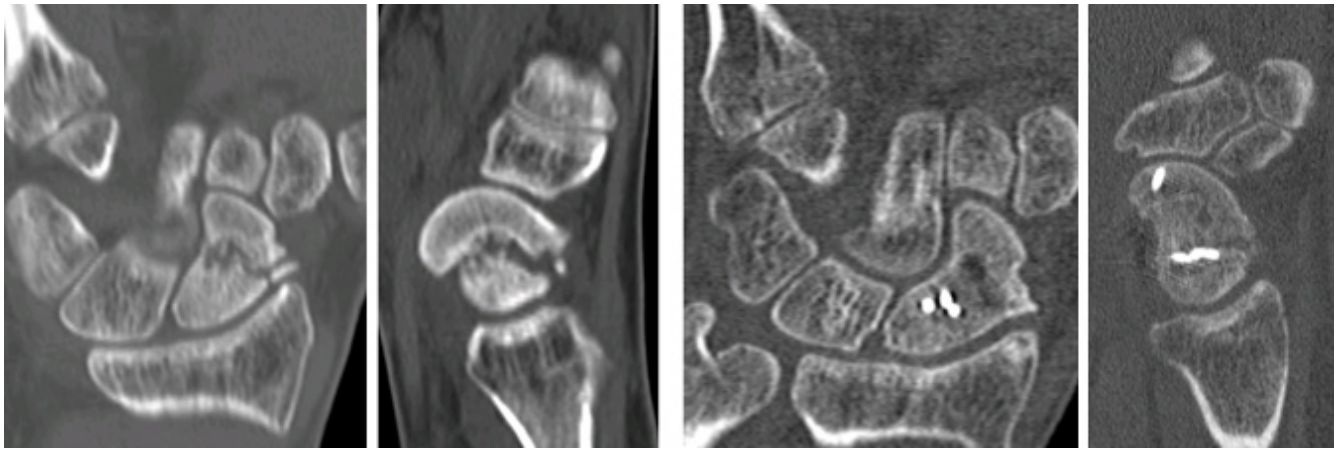

Fig. 2: Assessment of union by CT scan at 3 months after surgery

RESULTS

After a mean time of 4 months, 47 out of 49 nonunions (96%) were found to be united on follow-up CT-scans (Fig 2). Two patients did not achieve union. As for major events (2%), the post-operative scan of one patient showed protrusion of a proximal screw in the radiocarpal joint, for which a revision surgery had to be performed. The plate was eventually removed in eighteen patients (37%) due to functional impairment or impingement on the volar lip of the distal radius.

Table 2 - post-operative outcomes of volar plate fixation for scaphoid nonunion

n = 49		
Union	47/49	96%
Time to union 3 months 6 months 9 months 12 months	 35/49 42/49 45/49 47/49	 71% 86% 92% 96%
Major events	1/49	2%
Minor events	1/49	2%

As for functional outcomes, a total of 34 patients (69.4%) were reassessed for follow-up at a mean of 33 months after surgery. The results are summarized in table 3. The mean flexion-extension ROM improved significantly from 89° preoperatively to 124° at final follow-up. The mean grip strength improved from 52% to 79% at follow-up. The mean PRWHE score improved significantly from 66 points to 17 points at follow-up.

Table 3 - functional outcomes of volar plate fixation for scaphoid nonunion

n = 34	Pre-operative	Follow-up	P-value
Range of motion (degrees) (flexion/extension)	89 (44-45)	124 (59-65)	0.003
Grip strength (%)	52	79	<0.001
PRWHE (pain subscale)	26	7	<0.001
PRWHE (function subscale)	35	8	<0.001

DISCUSSION

In 2011 a new implant for plate fixation was introduced when Leixnering et al. described fixation of scaphoid nonunion by a pre-contoured miniplate, achieving 100% union in eleven patients.[3] In this study, the main indication for plate fixation was limited to scaphoid pseudarthrosis which had been treated unsuccessfully previously by screw osteosynthesis. Since then, a number of small, heterogenous series of volar plate fixation for scaphoid nonunion have been published, with either a pure cancellous or a vascularized bone graft for a broader spectrum of indications, achieving union in 87-100% of cases.[4, 7-12] The union rate in our prospective series (96%) is comparable to the results of small, mostly retrospective series published in the past decade. We present a heterogenous group of consecutive patients with a substantial number of long-lasting nonunions, proximal pole nonunion and avascular nonunions of the scaphoid. The high union rates in our series support the hypothesis that restoring stability is at least as important as restoring the biology of the scaphoid in the management of scaphoid nonunions. In addition, there was no correlation between avascularity of the proximal pole of the scaphoid, as diagnosed on preoperative MRI scans and assessed by means of punctate bleeding, and postoperative nonunions in our series as all six avascular nonunions united unremarkably. Singh et al. reported similar findings and found that enhanced MRI assessment of the vascularity of the proximal fragment of a scaphoid nonunion did not predict the outcome of reconstructive surgery.[13] Furthermore, when examining the trabecular structure of 15 scaphoid nonunions, Qu et al. showed that the bone mineral density of the proximal fragment was higher and trabecular structures were increased compared with the distal fragment, which contradicts avascularity of the proximal pole as a determining factor for poor healing in established scaphoid nonunions.[14] In agreement with Elliot et al., we suggest that most scaphoid nonunions have the biological potential to heal, but fail to do so due to instability causing strain at the fracture site.[15] Thus, we believe that most scaphoid nonunions will heal if the biomechanical strain on the fracture site is reduced. When considering the stability, the rotational stability achieved by a locking plate is significantly higher than that achieved by a single screw.[16] The high union rate in patients with previous screw fixation in this series might be explained due to the superior interfragmentary stability of the plate fixation compared to a single screw.

In our opinion, given the success rates of this technique, the indication for vascularized bonegrafting techniques is limited to necessity for autografting articular chondral defects of e.g. the proximal pole. As for the consideration for the different methods of internal fixation, Jurkowitsch et al reported that the rotational stability of the locking plate did not differ significantly from that of double screw fixation.[16] Besides the technically demanding placement of a double screw fixation in these patients, the placement of two screws across the nonunion will greatly reduce the surface area available for healing.[17] Due to anatomical precontouring of the implant, the scaphoid plate allows for anatomical restoration of a volar collapsed nonunion and therefore correction of an eventual humpback deformity. However, the effect of plate fixation on the carpal alignment remains unclear and the relation between restoration of carpal alignment and functional outcome in the treatment of scaphoid nonunion is unknown. Further studies on the effect of plate fixation on carpal alignment might lead to a better understanding of the indications for this technique in the treatment of scaphoid nonunion.

ABOUT THE AUTHORS

Dr. Philip M. J. Schormans
Trauma Surgeon
Amphia Hospital
4818 CK Breda
The Netherlands

Dr. Pascal F. W. Hannemann
Trauma and Hand Surgeon
Maastricht University Medical Centre
Department of Surgery and Trauma Surgery
6202 AZ Maastricht
The Netherlands

REFERENCES

1. *Singh HP, Taub N, Dias JJ.*
Management of displaced fractures of the waist of the scaphoid: meta-analyses of comparative studies.
Injury. 2012;43:6:933-9.

2. *Pinder RM, Brkljac M, Rix L, et al.*
Treatment of Scaphoid Nonunion: A Systematic Review of the Existing Evidence.
J Hand Surg Am. 2015;40:9:1797-805 e3.

3. *Leixnering M, Pezzei C, Weninger P, et al.*
First experiences with a new adjustable plate for osteosynthesis of scaphoid nonunions.
J Trauma. 2011;71:4:933-8.

4. *Ghoneim A.*
The unstable nonunited scaphoid waist fracture: results of treatment by open reduction, anterior wedge grafting, and internal fixation by volar buttress plate.
J Hand Surg Am. 2011;36:1:17-24.

5. *Dodds SD, Patterson JT, Halim A.*
Volar plate fixation of recalcitrant scaphoid nonunions with volar carpal artery vascularized bone graft.
Tech Hand Up Extrem Surg. 2014;18:1:2-7.

6. *Singh HP, Forward D, Davis TR, et al.*
Partial union of acute scaphoid fractures.
J Hand Surg Br. 2005;30:5:440-5.

7. *Dodds SD, Halim A.*
Scaphoid Plate Fixation and Volar Carpal Artery Vascularized Bone Graft for Recalcitrant Scaphoid Nonunions.
J Hand Surg Am. 2016;41:7:e191-8.

8. *Schormans PMJ, Brink PRG, Poeze M, et al.*
Angular Stable Miniplate Fixation of Chronic Unstable Scaphoid Nonunion.
J Wrist Surg. 2018;7:1:24-30.

9. *Esteban-Feliu I, Barrera-Ochoa S, Vidal-Tarrason N, et al.*
Volar plate fixation to treat scaphoid nonunion: a case series with minimum 3 years of follow-up.
The Journal of hand surgery. 2018;43:6:569. e1-. e8.

10. *Putnam JG, DiGiovanni RM, Mitchell SM, et al.*
Plate fixation with cancellous graft for scaphoid nonunion with avascular necrosis.
The Journal of hand surgery. 2019;44:4:339. e1-. e7.

11. *Mehling IM, Arsalan-Werner A, Wingenbach V, et al.*
Practicability of a locking plate for difficult pathologies of the scaphoid.
Archives of orthopaedic and trauma surgery. 2019;139:8:1161-9.

12. *Wu F, Ng CY, Hayton M.*
The authors' technique for volar plating of scaphoid nonunion.
Hand clinics. 2019;35:3:281-6.

13. *Singh A, Davis T, Dawson J, et al.*
Gadolinium enhanced MR assessment of proximal fragment vascularity in nonunions after scaphoid fracture: does it predict the outcome of reconstructive surgery?
Journal of Hand Surgery. 2004;29:5:444-8.

14. *Qu G, von Schroeder HP.*
Trabecular microstructure at the human scaphoid nonunion.
The Journal of hand surgery. 2008;33:5:650-5.

15. *Elliott DS, Newman KJ, Forward DP, et al.*
A unified theory of bone healing and nonunion: BHN theory.
Bone Joint J. 2016;98-B:7:884-91.

16. *Jurkowitsch J, Dall'Ara E, Quadlbauer S, et al.*
Rotational stability in screw-fixed scaphoid fractures compared to plate-fixed scaphoid fractures.
Arch Orthop Trauma Surg. 2016;136:11:1623-8.

17. *Hart A, Mansuri A, Harvey EJ, et al.*
Central versus eccentric internal fixation of acute scaphoid fractures.
The Journal of hand surgery. 2013;38:1:66-71.

RSL arthrodesis: indications and mid-term follow-up results

Massimo Corain, Filippo Zanotti, Mattia Giardini, Lorenzo Marcucci

INTRODUCTION

Radiocarpal arthrodesis is a standard procedure performed to achieve pain relief and to correct deformity in the wrist. This may be performed as a total wrist fusion (TWF) extending from the radius across the carpus and carpometacarpal (CMC) joints; or may be performed as a partial arthrodesis to maintain part of the range of motion (ROM).

Partial carpal fusions have been shown to be effective methods of treating specific carpal disorders[1]. The goal of these procedures is to optimize postoperative wrist motion, strength and stability while reducing pain.

The after-effects of distal radius articular fractures with a step-off greater than 2 mm have been shown to indicate high risk for post-traumatic degenerative arthritis, leading to pain and functional limitations[2] (Fig.1). Similarly, radiocarpal destruction from systemic inflammatory arthritis can cause pain and limit upper extremity function. High fusion rates and good pain relief can be expected with complete wrist arthrodesis, but many patients may find the complete loss of motion limiting. Most activities of daily living can be accomplished with wrist motion in the range of 10 flexion, 35 extension, 10 radial deviation, and 15 ulnar deviation[3], indicating that preservation of partial motion is a worthwhile goal. Although wrist replacement arthroplasty can restore a pain-free functional arc of motion, it is not a lasting option for patients who have high physical demands. In 1961, Gordon and King[4] reported the first experience with radioscapholunate arthrodesis (RSL). Although RSL arthrodesis is an intuitively appealing option arthritis that is limited to the radiocarpal joint, few studies have been published on the topic. A successful radioscapholunate arthrodesis is predicated on having a nearly normal midcarpal joint. Despite previous reports of high complication rates for limited arthrodesis procedures in the wrist[5], degenerative post-traumatic[2] or inflammatory arthritis[6] found isolated to the radiocarpal joint presents the surgical option of an RSL arthrodesis to preserve some wrist motion.

The purpose of this article is to review the surgical technique, and the results of RSL arthrodesis using a dedicated volar plate.

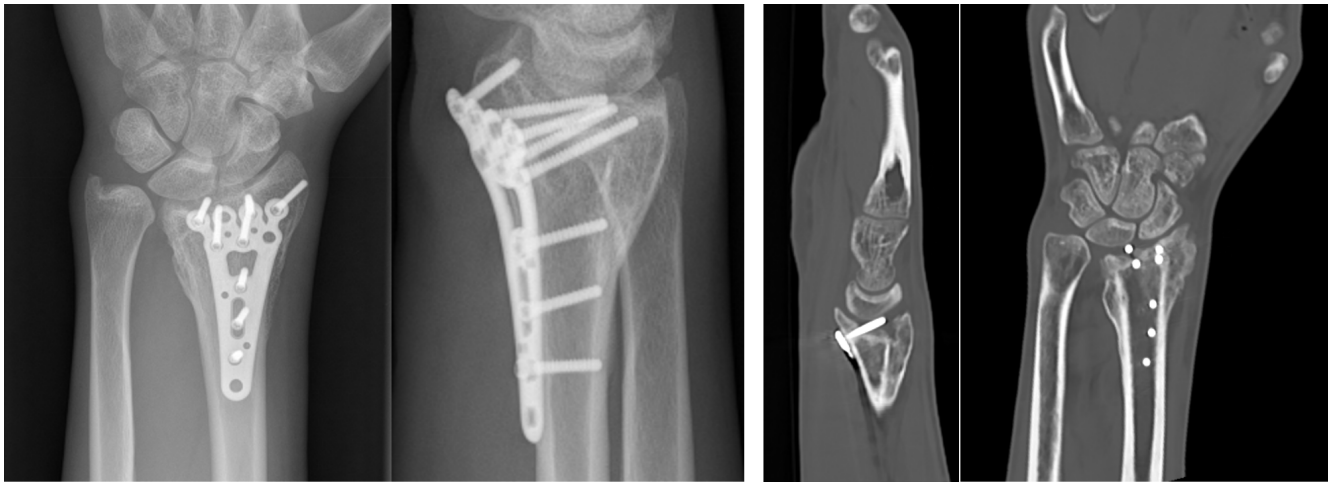

Fig. 1 Unsuccessful distal radius synthesis, x-ray and CT presentation

MATERIALS AND METHODS

From 2017 to 2019, nine cases of radiocarpal arthritis localized to the radioscaphoid and radiolunate surfaces were surgically treated with RSL arthrodesis with a dedicated volar plate. The average age of the patients at the time of surgery was 43.4 years, with a minimum age of 26 and a maximum of 67 years. The mean follow up was 24.9 months (40-12). Seven patients underwent surgery on the right arm and the remainder had surgery on the left.
Every patient before surgery was studied with standard AP and LL projections and views on x-ray. An MRI was carried out to assess the extent of joint damage and the integrity of the articular surface of the midcarpal (Fig. 2).
All patients were treated surgically with a Medartis Radioscapholunate Arthrodesis System with 2.5 TriLock RSL Fusion Plates and using the volar approach. After surgery, patients were splinted for 4 weeks followed by a progressive physiotherapy rehabilitation program. All patients were evaluated with postoperative radiographs at 1, 3 and 6 months.
At every follow-up, we evaluated the joint ROM in flexion-extension, pronation-supination, radial and ulnar deviation and strength with the Jamar test and the Pinch test, comparing the results with the contralateral wrist. DASH score (Disability of the Arm, Shoulder and Hand) and Mayo Wrist score were used on every patient.

Fig. 2 MRI study of the midcarpal join

TECHNIQUE

The distal radial surface is exposed according to Henry's[7] approach and distally extended until reaching the thenar crease, also incised longitudinally. Distally, the volar transverse carpal ligament is excised.
Being careful not to injure the palmar cutaneous branch of the median nerve, the median nerve and its motor branch are radially retracted and protected and the superficial and deep flexors of the fingers are retracted towards the ulna so as to expose the volar capsule of the wrist, which is incised through a reverse T approach. The bones of the proximal row are exposed and the midcarpal joint is inspected to document its integrity. The articular surfaces are then scraped using a burr. It is recommended to remove the volar portion of the SL ligament and to rasp this surface as well. Distal pole emiscaphoidectomy is then performed. The construct is temporary stabilized with Kirschner wires between the scaphoid and lunate to the radius. Cancellous bone taken from the distal radius and from the removed part of the scaphoid is grafted into the arthrodesis sites where necessary, taking advantage of the "core decompression" effect, according to Illarramendi[8]. The plate is then positioned (Medartis TriLock RSL Fusion Plates).

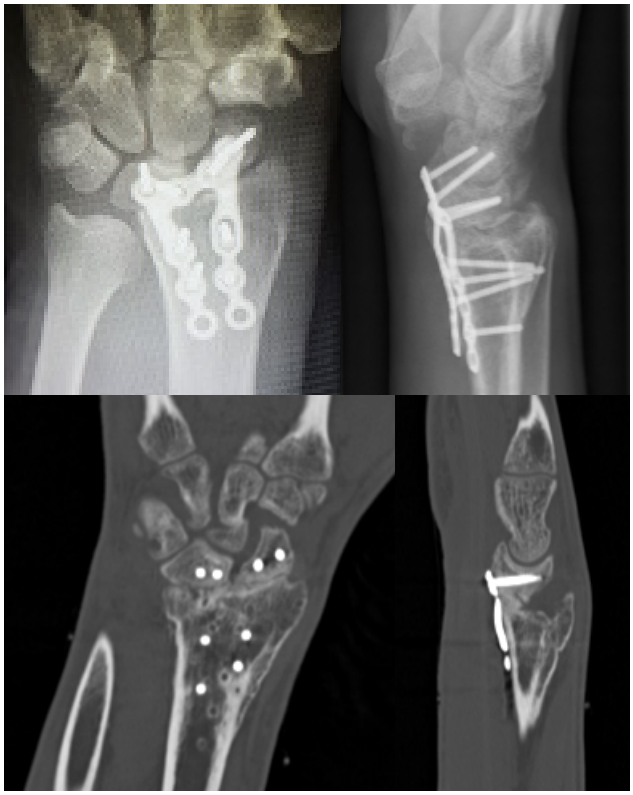

Fig. 3 RSL Arthrodesis, Xray an CT control

For better plate placement, blunting the volar rim of the radius articular surface just distal to the watershed line is suggested.
First, a compression screw is inserted in the oval hole on the radius, the correct positioning of the plate is checked by means of a fluoroscope. The distal screws are then positioned (2 in the scaphoid and 2 in the lunate). The first compression screw placed in the radius can be slightly loosened and the plate slid slightly disto-proximally and then compressed again to increase radio-carpal joint compression. The remaining stability screws are placed at the level of the radius (Fig. 3).
After the final checks in radioscopy and having proved the movement of the midcarpal we proceed with the reconstruction of the access layers and the interrupted structures. It is not recommended to reconstruct the transverse carpal ligament in order to avoid possible negative effects on the median nerve.

RESULTS

At follow-up, the mean range of motion in flexion extension (FE) was 66.7° (45°- 80°), 41.7% of a normal wrist (160°). The average of radioulnar deviation ROM (RUD) was 38.6° (30°- 45°), corresponding to 55% of a healthy wrist(70°). The pronosupination suffered minimal repercussions in few cases, the average ROM value is 174.5° (160°-180 °). The average grip strength (Jamar test) of the operated hand is 25.5 kg (6-44) while for the healthy contralateral it was measures at 35.8 kg (12-52). As a percentage, it can be stated that the average grip strength of the treated hand was 71% compared to the contralateral.

The mean DASH score calculated at follow-up was 30.6 (5.8-61.7) whereas when calculated during the preoperative time the mean value was 70.15 (50.8-86.7). The mean Mayo Wrist score calculated at follow up was 59.5 (25-75) whereas when calculated during the preoperative period, the mean value was 28.9 (0-55). (Fig. 4)
In only one case, it was necessary to remove the plate after consolidation of the arthrodesis due to median nerve neuritis caused by scar adhesions.
All patients returned to their work and recreational activities. There was no case of non-fusion of the arthrodesis at radiographic control at 6 months. There was no case of mobilization of the device or infection.

	ROM FE °	PS °	DRU °	MWS		DASH		JAMAR kg		PINCH kg	
				pre	post	pre	post	Op	CL	Op	CL
1	65°	175°	39°	50	60	70	36.7	32	47	5	7
2	80°	180°	45°	55	75	50.8	5.8	44	52	7	8
3	60°	170°	40°	10	55	79.2	29.4	31	44	5.5	7
4	75°	180°	38°	40	70	66.7	16.3	23	34	4.5	5.5
5	45°	175°	30°	0	25	84.2	61.7	6	12	2	2
6	75°	160°	35°	20	60	86.7	55.8	19	31	4	5
7	70°	180°	42°	10	65	73.5	19.1	25	31	4.5	6
8	55°	170°	33°	30	60	61.4	30.8	21	36	4	6.5
9	75°	180°	45°	45	65	58.8	12.2	28	35	5	6.5

DISCUSSION

The main purpose of a radioscapholunate arthrodesis as a rescue intervention is the reduction of pain and the recovery of a strong grip allowing a return to work and daily activities. In most cases, RSL arthrodesis is indicated following post-traumatic arthritis that is the after-effect of a distal radius malunion. Intra-articular fractures involving the volar-ulnar fragment are particularly difficult to treat. Often referred as a "critical corner", the failure of synthesis of this fragment can lead to volar subluxation of the carpus and therefore to osteoarthritis. In our series, 7 patients were treated for post-traumatic arthrosis, two of which were due to failure of the surgical fracture fixation.
The remaining 2 patients were treated for degenerative osteoarthritis within the context of systemic juvenile rheumatoid arthritis. The involvement of the DRUJ joint is often concomitant with that of the radiocarpal, causing instability and pain that cannot be solved with RSL arthrodesis alone. Ishikawa et al.[9] suggest using a distal ulna osteotomy, according to the Darrach[10] approach, alongside RSL arthrodesis to prevent the development of instability and secondary pain that are characteristic of RA. In both patients evaluated in our study, the clinical results at follow-up suggest initial instability of the DRUJ due to the progression of rheumatoid arthritis, which significantly influenced the results of the surgery.

The mid-term follow-up does not allow us to correctly assess the percentage of surgically treated patients who will experience the development of midcarpal arthrosis, but an incidence rate of 35–53% is reported in the literature. Nagy and Büchler[11,12], speaking of the results of RSL arthrodesis, said that the long-term complication rate is unacceptable; in their 8-year FU study, 5 of 15 patients (33%) required conversion to total wrist arthrodesis. However, this study took into consideration obsolete means of synthesis and did not account for distal pole scaphoidectomy.
Our results for postoperative ROM are in line with those found in literature. Cadaver studies[13] report a flexion arc of up to 122°, compared to the 60° documented without excision of the distal pole of the scaphoid.
However, it should be emphasized that other in vivo studies do not report such ranges of motion. The ROM in radioulnar deviation reported in the studies varied from 34° to 43°, similar to the results obtained in our study.

A cadaver study performed by Berkhout et al.[14] demonstrated the possibility of further increasing joint ROMs in flexion extension and radioulnar deviation through complete excision of the triquetrum.
According to the studies of Garcia Elias[15], we haven't had any cases of nonunion. Garcia Elias argues that the removal of the distal pole of the scaphoid eliminates an important lever arm thus reducing the tensions otherwise present at the focus of arthrodesis, leading to a higher rate for fusion and a lower incidence of midcarpal arthritis. A further stimulus for fusion is given by the removal of the cancellous bone tissue at the level of the distal radius. By exploiting the "core decompression" effect, as described by Illarramendi[8], an increase in vascularization is produced at the level of the lunate and the first carpal chain, so as to increase bone consolidation.
Our patients were all treated with RSL arthrodesis using a volar plate and distal pole scaphoidectomy. The volar plate allows the carpus to be supported in the most biomechanically effective way compared to other approaches. In rheumatoid arthritis, there is a progressive volar translocation of the carpus; in fractures of the volar rim of the lunate radius dimple, the real risk is volar carpal dislocation. For this reason, in such conditions, the volar approach with a dedicated plate finds a perfect indication.
In case of a volar plating failure, the volar approach allows for the removal of the previous device from the radius in order to proceed with an RSL fusion.
After the plate is positioned, it is often possible to cover part of the plate with the pronator quadratus muscle and volar ligaments and capsule, thus reducing any risk of tendon impingements.
A complication related to the extended volar approach is median nerve entrapment syndrome ; it has been documented in two patients, one of which required neurolysis of the median nerve and plate removal.
Our study documents a grip strength in the treated hand of 71% compared to the contralateral, the literature reports a percentage of 63%[16]. It can be interpreted from the DASH score results as, on average the patients perceived a subjective improvement in their clinical condition compared to the previous situation.
It is documented that the majority of healthy people who fill in this questionnaire have a result that varies from 0–29; therefore, within this range, a patient is considered to have a normal wrist[17].
It is not so for the Mayo wrist score[18]. The limit value for a "satisfactory" result in this case is 60 points. The average value calculated for our patients is 59.5, a score affected of the small sample. Of all the patients the only ones with an "unsatisfactory" score are M (MWS of 25), a patient with destructive rheumatoid arthritis and instability of the RUD and B (MWS of 55), high-energy polytrauma with multiple fractures, ineffective surgical fixation and subsequent RSL arthrodesis rescue. Another bias for the evaluation of these patients with the Mayo wrist score is the percentage of the final score linked to the residual joint ROM, which obviously, given the nature of the intervention, cannot be beyond a certain value.

CONCLUSION

RSL arthrodesis is a valid surgical rescue intervention among the options available when performed according to the correct indications. First of all, it is mandatory to ascertain the validity of the midcarpal joint, a necessary condition to be able to trust in the success of the intervention, even in the medium and long term.
These same indications suggest the validity of the volar approach and of synthesis with a dedicated plate, which prevents the risk of of volar carpal subluxation in the outcomes of marginal articular fracture of the radius and blocks the progression of volar and ulnar transition of the lunate in rheumatoid arthritis.
It can't be omitted that of the 9 patients treated, 2 developed median nerve entrapment syndrome caused by scarring of the surgical access and one of these underwent a second neurolysis and plaque removal operation.
It must be emphasized that the results obtained with regard to the range of motion and residual strength are comparable to those in the literature. This highlights how the removal of the distal pole of the scaphoid contributes to improving the range of motion and the rate of fusion, as described by Garcia Elias.
The limits of the study are the small sample of patients and the short- to mid-term follow-up, which does not allow for the evaluation of the actual risk of developing midcarpal arthrosis.

Fig. 4 Clinical result: Ulnar and radial deviation, extension, flexion.

ABOUT THE AUTHORS

Dr. Massimo Corain
Head of Hand Surgery
at Policlinico G.B. Rossi
Verona
Italy

Dr. Filippo Zanotti
Upper Limb Surgeon
at Policlinico G.B. Rossi
Verona
Italy

Dr. Mattia Giardini
Upper Limb Surgeon
at Policlinico G.B. Rossi
Verona
Italy

Dr. Lorenzo Marcucci
Resident in Orthopedic and Traumatology
at University of Verona
Italy

REFERENCES

1. *Watson HK, Weinzweig J, Guidera PM, Zeppieri J, Ashmead D.*
One thousand intercarpal arthrodeses.
J Hand Surg [Br] 1999;24(3): 307–315.

2. *Knirk JL, Jupiter JB.*
Intra-articular fractures of the distal end of the radius in young adults.
J Bone Joint Surg [Am] 1986;68(5):647–59.

3. *Palmer A.K., Werner F.W., Murphy D., Glisson R.*
Functional wrist motion: a biomechanical study.
J Hand Surg 1985; 10A: 39-46.

4. *Gordon LH, King D.*
Partial wrist arthrodesis for old un-united fractures of the carpal navicular.
Am J Surg 1961;102:460–4.

5. *McAuliffe JA, Dell PC, Jaffe R.*
Complications of intercarpal arthrodesis.
J Hand Surg [Am] 1993; 18(6):1121–8.

6. *Chamay A, Della Santa D.*
Radiolunate arthrodesis in rheu- matoid wrist (21 cases).
Ann Chir Main Memb Super 1991; 10:197–206.

7. *Jorge L., Orbay M.D.*
DVR Anatomic Plate, The Established Standard in Volar Plating.
Surgical Technique Guide, Hand Innovations, 2007.

8. *Illarramendi AA, De Carli P.*
Radius decompression for treatment of kienböck disease.
Tech Hand Up Extrem Surg. 2003;7(3):110-113.
doi:10.1097/00130911-200309000-00007

9. *Ishikawa H, Murasawa A, Nakazono K.*
Long-term follow-up study of radiocarpal arthrodesis for the rheumatoid wrist.
J Hand Surg Am 2005; 30: 658-66.

10. *Darrach W.*
Anterior dislocation of the head of the ulna.
Ann Surg 1912;56:802–803.

11. *Sturzenegger M, Büchler U.*
Radio-scapho-lunate partial wrist arthrodesis following comminuted fractures of the distal radius.
Ann Chir Main Memb Super 1991;10(3):207–216.

12. *Nagy L, Büchler U.*
Long-term results of radioscapholunate fusion following fractures of the distal radius.
J Hand Surg [Br] 1997; 22(6):705–710.

13. *McCombe D, Ireland DC, McNab I.*
Distal scaphoid excision after radioscaphoid arthrodesis.
J Hand Surg Am 2001;26(5):877–882.

14. *Berkhout MJ, Shaw MN, Berglund LJ, An KN, Berger RA, Ritt MJ.*
The effect of radioscapholunate fusion on wrist movement and the subsequent effects of distal scaphoidectomy and triquetrectomy.
J Hand Surg Eur Vol 2010;35(9):740–745.

15. *Garcia-Elias M, Lluch A, Ferreres A, Papini-Zorli I, Rahimtoola ZO.*
Treatment of radiocarpal degenerative osteoarthritis by radio-scapholunate arthrodesis and distal scaphoidectomy.
J Hand Surg Am 2005;30(1):8–15.

16. *Murray PM.*
Radioscapholunate Arthrodesis.
Hand Clinics. 2005;21(4):561-566. doi:10.1016/j.hcl.2005.08.003

17. *Gummesson C, Atroshi I, Ekdahl C.*
The disabilities of the arm, shoulder and hand (DASH) outcome questionnaire: longitudinal construct validity and measuring self-rated health change after surgery.
BMC Musculoskelet Disord. 2003;4(1):11.
doi:10.1186/1471-2474-4-11

18. *Cooney WP, Bussey R, Dobyns JH, Linscheid RL.*
Difficult wrist fractures. Perilunate fracture-dislocations of the wrist.
Clin Orthop Relat Res 1987;(214):136–147.

Biomechanical considerations of a CT-based treatment-oriented classification in radius fractures

Wolfgang Hintringer, Rudolf Rosenauer, Stefan Quadlbauer

INTRODUCTION

A wide range of different classifications for distal radius fractures (DRF) exist. Most of them are based on plane x-rays, and they do not give us any information on how to treat these fractures. A biomechanical understanding of the mechanical forces underlying each fracture type is important to treat each injury specifically with the optimal choice for stabilization.

CLASSIFICATIONS OF DISTAL RADIUS FRACTURES

In the past, classifications were mainly based on plain x-rays. CT scans, 3D reconstructions and 3D printing are useful diagnostic tools to enhance our understanding of these fractures and improve treatment options.
Mandziak et al.[1] demonstrated the correlation between fracture lines and the insertion points of the ligaments on the palmar and dorsal aspect of the radius.
Bain et al.[2] showed that in most two-part fractures, recurring fracture lines can be found depending on the ligament insertions. He introduced the term "osteoligamentous unit".

Brink and Rikli[3] provided a simplified classification based on four pillars, each possessing specific biochemical functions and a special bearing on the dislocation mechanism. The critical fracture fragment, which causes the shift of the carpus in different directions, was called the "key fragment".
The main aim of this paper is to combine and modify these classifications, with an improved understanding of the biomechanics of the "key fragments". It is therefore an opportunity to establish a treatment concept to stabilize critical fracture fragments by using different types of internal fixation.[4]

Fig. 1

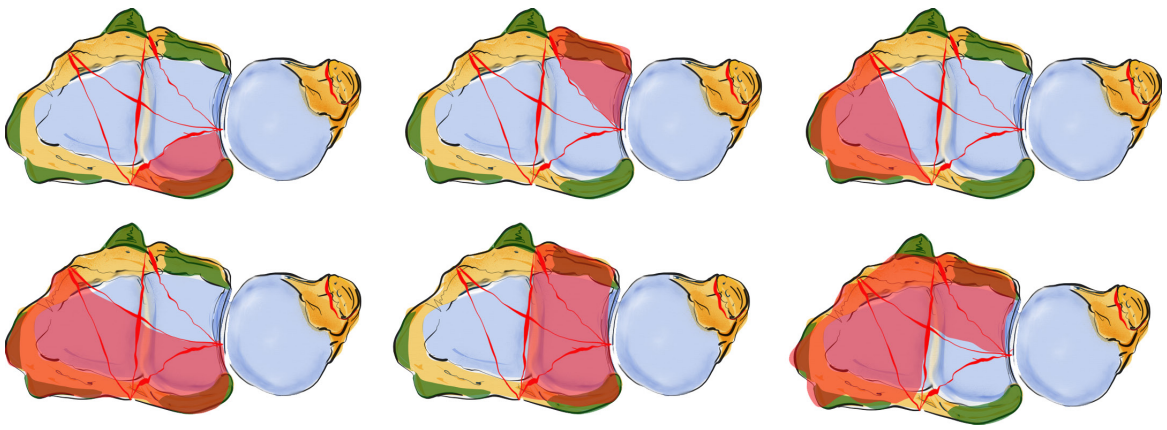

The osteoligamentous units include the insertions of the extrinsic stabilizing ligaments when they are fixed and stable, the stability of the ligament is guaranteed.
We call these fragments key fragments, because they are the cornerstone of the stability of the carpal bones that are attached to them. In partial intra-articular fractures, six different patterns can be observed. At least one corner remains intact and in continuity with the shaft. The origins of the extrinsic ligaments are shown, which seem to reinforce the bone[2] (see Fig. 1).
We want to pick out one key type, the volar key type, from the whole classification and consider how this osteo-ligamentous unit can be fixed.

VOLAR KEY TYPE FRACTURES

A palmar acting force leads to a fracture of the palmar cortical bone (see Fig. 2A and B) with depression of the volar aspect of the radius or a volar dislocation fracture with smaller or larger fragments (see Fig. 2A and B). This highly depends on the position of the dorsally extended wrist. An isolated fracture of an ulnar rim fragment is possible, or, alternatively, the palmar fracture extends from the ulnar to the radial side (see Fig. 2E).

Due to the fact that the palmar V ligaments are connected to these palmar fragments and they support the proximal row like a belt (see Fig. 2F), the whole carpus tends to dislocate in a palmar direction in the case of a fracture of this osteoligamentous unit. The volar ulnar fragment is the origin of the ulnocarpal and the volar radioulnar ligaments, which are the main stabilizers of the distal radioulnar and the ulnocarpal joint (see Fig. 2E). If these ligaments are impaired, the radiocarpal and radioulnar joints are destabilized.
Furthermore, palmar fractures with smaller fragments—so-called rim fragments—are often overlooked and tend to show a higher degree of instability. Beyond these bony injuries, accessory ligament injuries are possible.

Fig. 2A

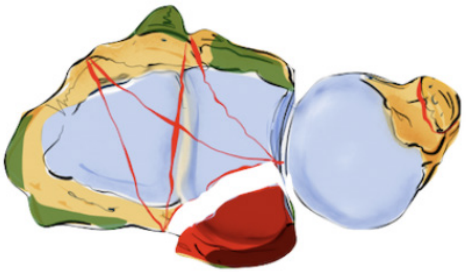

Fig. 2B

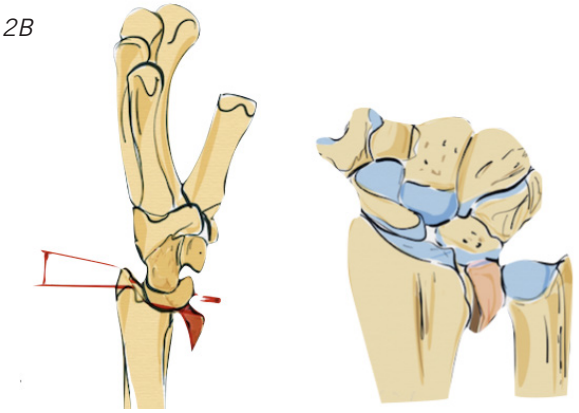

Fig. 2C

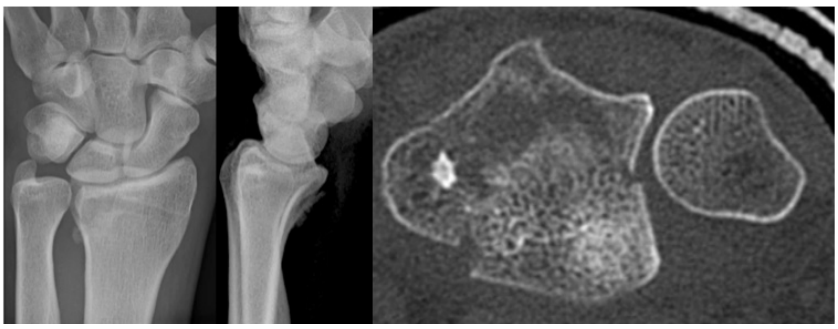

Fig. 2D

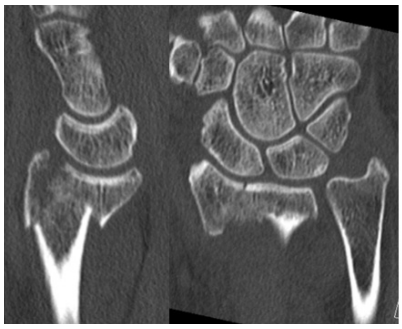

Fig. 2E

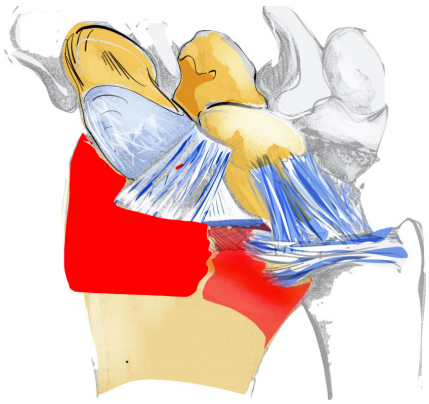

Fig. 2F

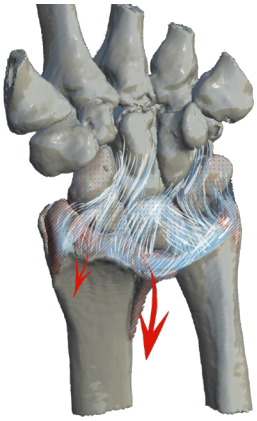

Volar rim fragments can be situated ulnar or radial. (see Fig. 3A, B, C, D). A single ulnar volar rim fragment causes a rotational displacement of the carpus towards the volar side, (see Fig 3B). If the entire rim is broken the carpus displaces symetrically and parallel towards the volar side. (see Fig. 3C) According to the applied force from dorsal to volar shearing fragments are formed. (see Fig. 3F).

If the force acts inversely from volar to dorsal, volar tear out fragments and dorsal shear fragments are formed (see Fig. 3G, H). During reduction, the volar rim fragment is rotated 180 degrees and is an indicator of this multi-directional instability, since both palmar and dorsal osteo-ligamentous units are unstable. (see Fig. 3H)

Fig. 3

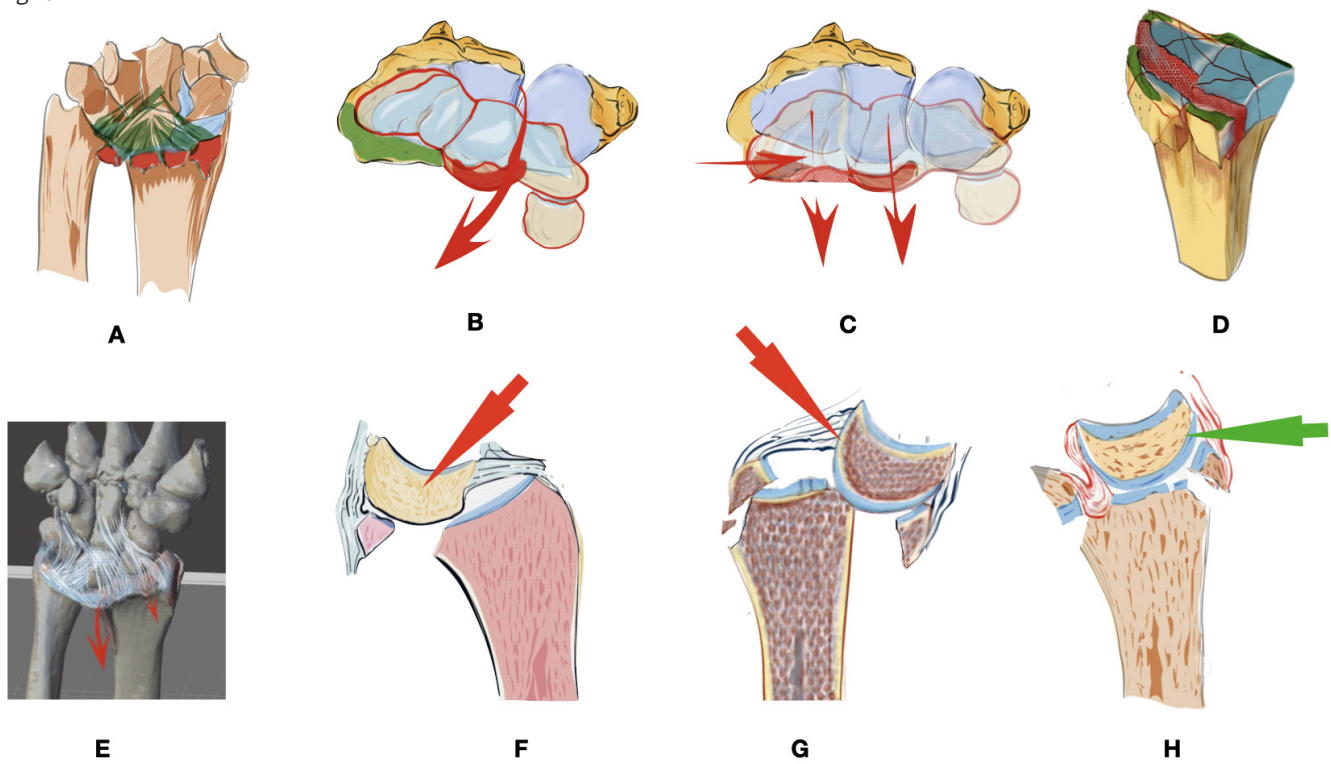

After stabilization of volar rim fragments, a palmar shift test must always be performed, as accessory ligament injuries may be present. If the carpus is unstable, it is recommended to drill a transfixation drill wire from the radius into the lunate in the correct position (see Fig. 4).

Fig. 4

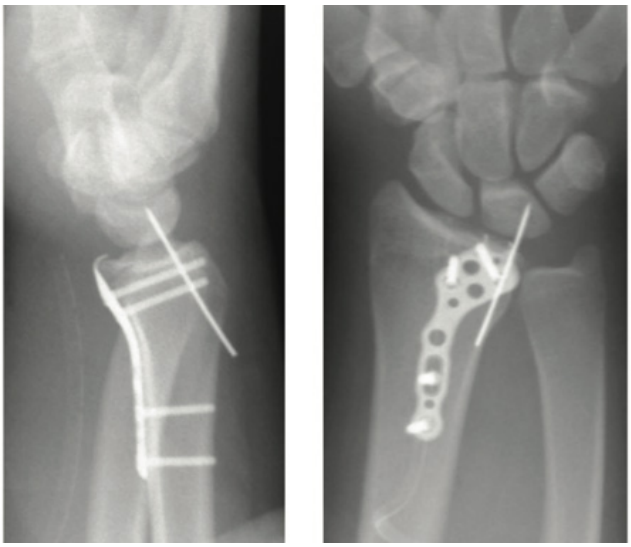

This paper is only an excerpt from the original paper:
W. Hintringer, R. Rosenauer, Ch. Pezzei, S. Quadlbauer, J. Jurkowitsch, T. Keuchel, T. Hausner, M. Leixnering, H. Krimmer
Biomechanical considerations on a CT-based treatment-oriented classification in radius fractures
https://link.springer.com/article/10.1007/s00402-020-03405-7

Fig. 5

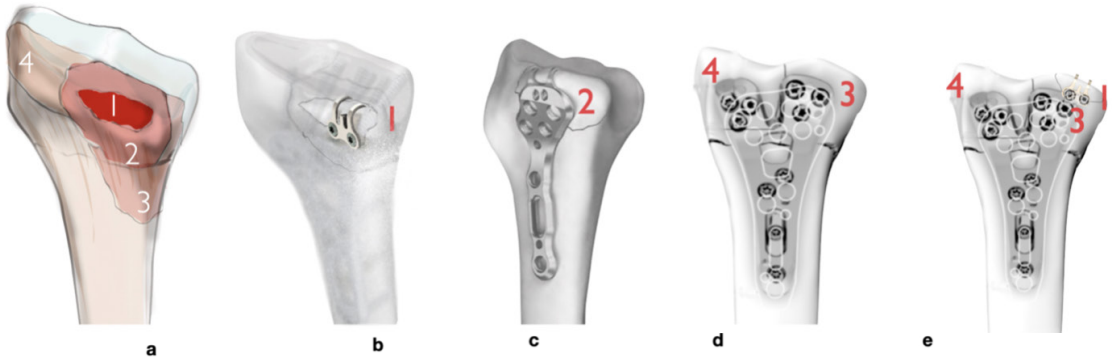

Different treatment options in different volar key fragments with different sizes in different locations: hook plate for small rim fragments[1]; fracture-specific plate for volar-ulnar fragments in larger fragments[2]; watershed plate; and FPL plate. Please note the different shapes on the overlay contours. The FPL plate reaches more distally on the ulnar and also radial side.[4,3] The column principle of the FPL plate allows for it to be positioned far more distally.
Hook plates can be used in addition to watershed plates [4,3,1].

REFERENCES

1. *Mandziak D, Watts A,*
   Ligament contribution to patterns of articular fractures of the distal radius.
   Surgery GB-TJ of hand, 2011 undefined Elsevier

2. *Bain G, MacLean S, McNaughton T, Williams R (2017)*
   Microstructure of the distal radius and its relevance to distal radius fractures.
   J Wrist Surg 06:307–315.
   https://doi.org/10.1055/s-0037-1602849

3. *Brink P, Rikli D (2016)*
   Four-corner concept: CT-based assessment of fracture patterns in distal radius.
   J Wrist Surg 05:147–151.
   https://doi.org/10.1055/s-0035-1570462

4. *Hintringer W, Rosenauer R, Pezzei C, et al.*
   Biomechanical considerations on a CT-based treatment-oriented classification in radius fractures.
   Arch Orthop Tauma Surg 2020;140(05):595–609

5. *Pechlaner S*
   Die Hyperextensionsverletzung des Handgelenkes: experimentelle Untersuchungen und klinische Aspekte
   Handchirurgie. 1. 1999:27–54

6. *Hintringer W., Quadlbauer S. ,.Rosenauer R.*
   Computed Tomography and Pathobiomechanical-Based Treatment of Volar Distal Radius Fractures
   J Wrist Surg 2021;00:1–11.

ABOUT THE AUTHORS

Prim. Dr. Wolfgang Hintringer
IBRA Past-President
Specialist on Hand and Microsurgery
Private Clinic Döbling
Vienna
Austria

Dr. Rudolf Rosenauer
AUVA Lorenz Böhler Unfallkrankenhaus
Vienna
Austria

Dr. Stefan Quadlbauer
AUVA Lorenz Böhler Unfallkrankenhaus
Vienna
Austria

Headquarters

IBRA
International Bone Research Association
Hochbergerstrasse 60E
CH-4057 Basel
Phone +41 61 319 05 05
Fax +41 61 319 05 19
info@ibra.net
www.ibra.net

Administration Office

IBRA
International Bone Research Association
North America, Inc.
224 Valley Creek Boulevard, Suite 100
Exton, PA 19341
info@ibra.net
www.ibra.net