IBRA scholarship report

Information about Scholar and fellowship

- Name of Scholar: David Bodansky
- Country of Citizenship: United Kingdom
- Name and Country of Training Center: Badia Hand to Shoulder Center, Miami, FL, USA
- Name of Fellowship Director: Alejandro Badia, M.D, F.A.C.S
- Scholarship Type: Program B
- Scholarship date: April 2022

Information about Scholar and fellowship

I am an Orthopaedic Fellow, David Bodansky from the United Kingdom. I completed my registrar training scheme (residency) in Liverpool in the UK and applied to IBRA to visit Dr Badia at the Badia Hand to Shoulder centre in Miami, USA under a program B scholarship in April 2022. Currently, I am a Senior Fellow in Upper Extremity Trauma and Reconstruction at Sunnybrook Medical Centre, Toronto, Canada and after visiting other centres in North America, intend to return to London, UK to start my consultant practice.

Professional and personal experience

- ·What were your professional and personal expectations of the scholarship?

My professional expectations of this scholarship were to see cases and conditions which I had not much exposure, in particular arthroplasty and arthroscopy of the hand and wrist. Further, I was looking forward to seeing how a private surgeon arranged his practice as my training to date has been in the UK's NHS, which is a hospital-based government funded social medicine system.

My personal expectations were to have the opportunity to discuss technical points with a mentor who could offer me the benefits of their experience and the opportunity to build connections for future collaboration. In addition, I was curious to talk through the differences and similarities of training and practice in the UK and USA.

- ·What is the main focus of the IBRA training center (in general and of the department)

The focus of Dr Badia's practice is orthopaedic hand and wrist surgery as well as upper extremity surgery. Dr Badia has a particular interest in small joint arthroscopy and arthroplasty of the upper extremity.

- ·What did you do during your scholarship/how were you incorporated in the training center's daily routines/activities:

I observed a busy clinic where Dr Badia runs four clinic rooms, with ultrasound, XR, fluoroscopy and an open MRI scanner all within one clinic set-up. In addition, I saw how the patient pathways flow from an adjacent acute care centre, OrthoNow and how the patient pathway can move from a pre-operative assessment on a Monday, Surgery on a Tuesday, Review on a Wednesday and then Therapy at an adjacent therapy centre. Here, there is room for 12 patients with dedicated hand therapists.

I observed interactions with local and international patients from across the Caribbean as well as Central and south America. I also saw how Dr Badia utilises telemedicine, in particular for his international patients, to maintain follow up and counsel them for surgery.

- How many surgeries have you assisted and which concrete technical modifications and methods have you seen?

I had the opportunity to observe 17 procedures in the operating room and was grateful to see a system that used three operating rooms to maximise efficiency. This was the first time I'd seen multiple operating rooms as in the UK, a surgeon only has access to one. This allowed me to understand methods to improve operating room efficiency, overlapping cases.

I saw shoulder arthroscopy from the lateral position, which allows the gleno-humeral joint to be distracted with a boom and allows superb visualisation of the joint.

I saw an endoscopic carpal tunnel release for the first time. Here, you make a transverse incision over the proximal wrist crease, ulnar to where palmaris longus would be (however do not look for it as a landmark, as PL is absent in 20% of the population). Key tips are to ensure that you have a Ragnal in the distal aspect of the skin incision to ensure that you do not cut the skin when you are exiting with the endoscopic blade and that you release the distal forearm fascia from the proximal aspect of the skin incision. Confirmation of full transverse ligament release is through observing the light in the palm and when injecting saline, the palm expands slightly.

I saw a shoulder resurfacing implant, the Catalyst, which offers minimal bone resection on the humeral head allowing for later surgical procedures.

Specify your 3 to 5 favorite procedures and/or new skills you could acquire

NB, pictures are included with patients' written permission.

- After a DIPJ fusion, Dr Badia uses a finger cast to protect the fusion site for 6 weeks until the buried K wires are removed. This is a low-cost option that can be applied in clinic (the office), in comparison to a custom-made removal thermoplastic splint, which I have seen previously which requires another visit. Dr Badia reported that patients tolerate this well and do not request its removal.

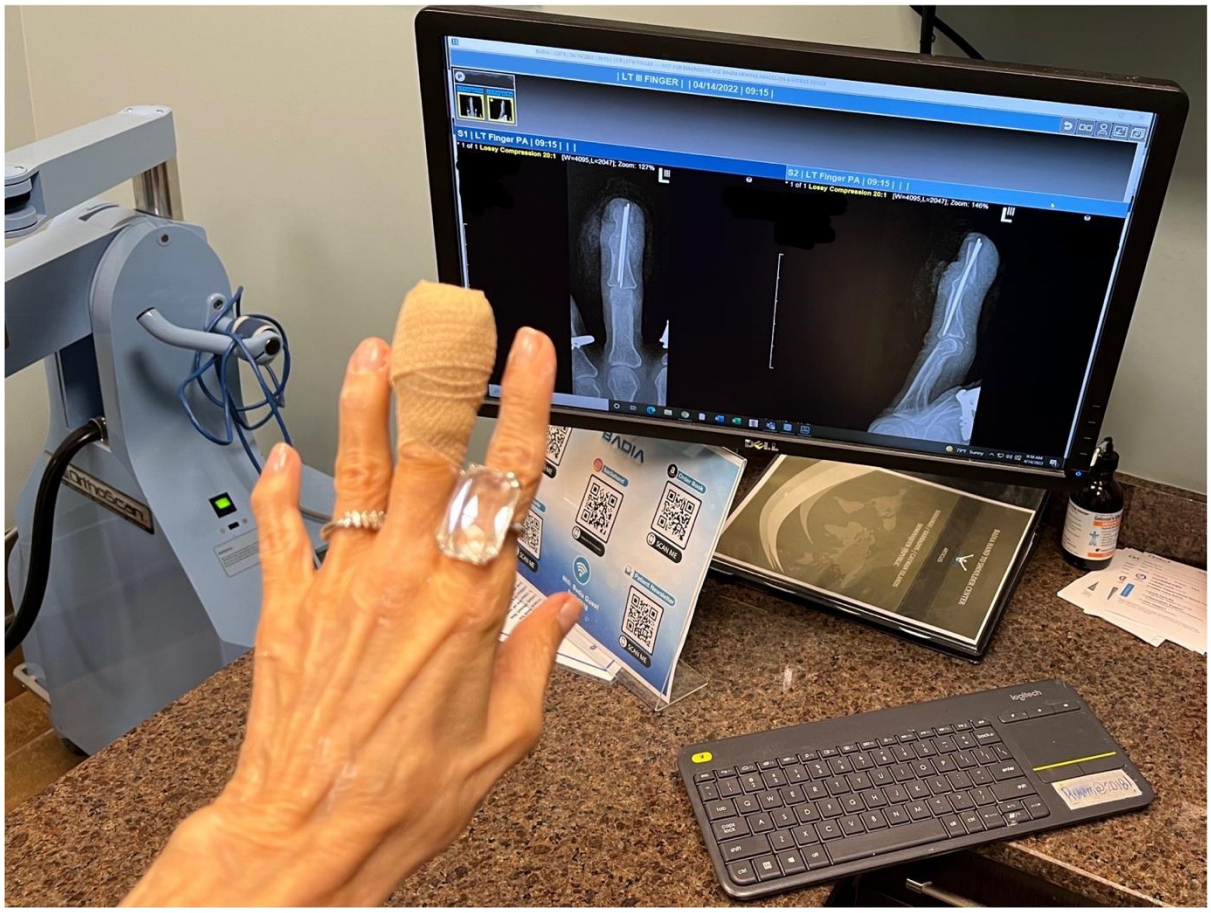

Figure 1: A finger cast- cylindrical Plaster of Paris covered in Coban wrap - for 6 weeks directly onto skin after a DIPJ fusion is tolerated well and provides protection to the fusion site

- Lateral epicondylitis (tennis elbow) is a clinical condition that can be challenging to treat. I had the opportunity to see a percutaneous of the extensor origin with a Tenex device, that uses focused ultrasound to debride percutaneously the extensor origin. This is inserted through a

1cm skin incision distal to the elbow and targeted on the extensor origin under ultrasound control. This can be done as a day-case (ambulatory) procedure under sedation and is the first percutaneous option I've seen for lateral epicondylitis. Previously, I have seen open debridement which requires a general anaesthetic and a longer recovery period.



Figure 2: Placement of the Tenex probe on the extensor origin to debride tendinosis

- Intra-articular distal radius fractures require accurate reduction to reduce the risk of post-traumatic arthritis. Here, I saw wrist arthroscopy to assess the amount of articular step off at the fracture site and achieve accurate reduction before fixation.

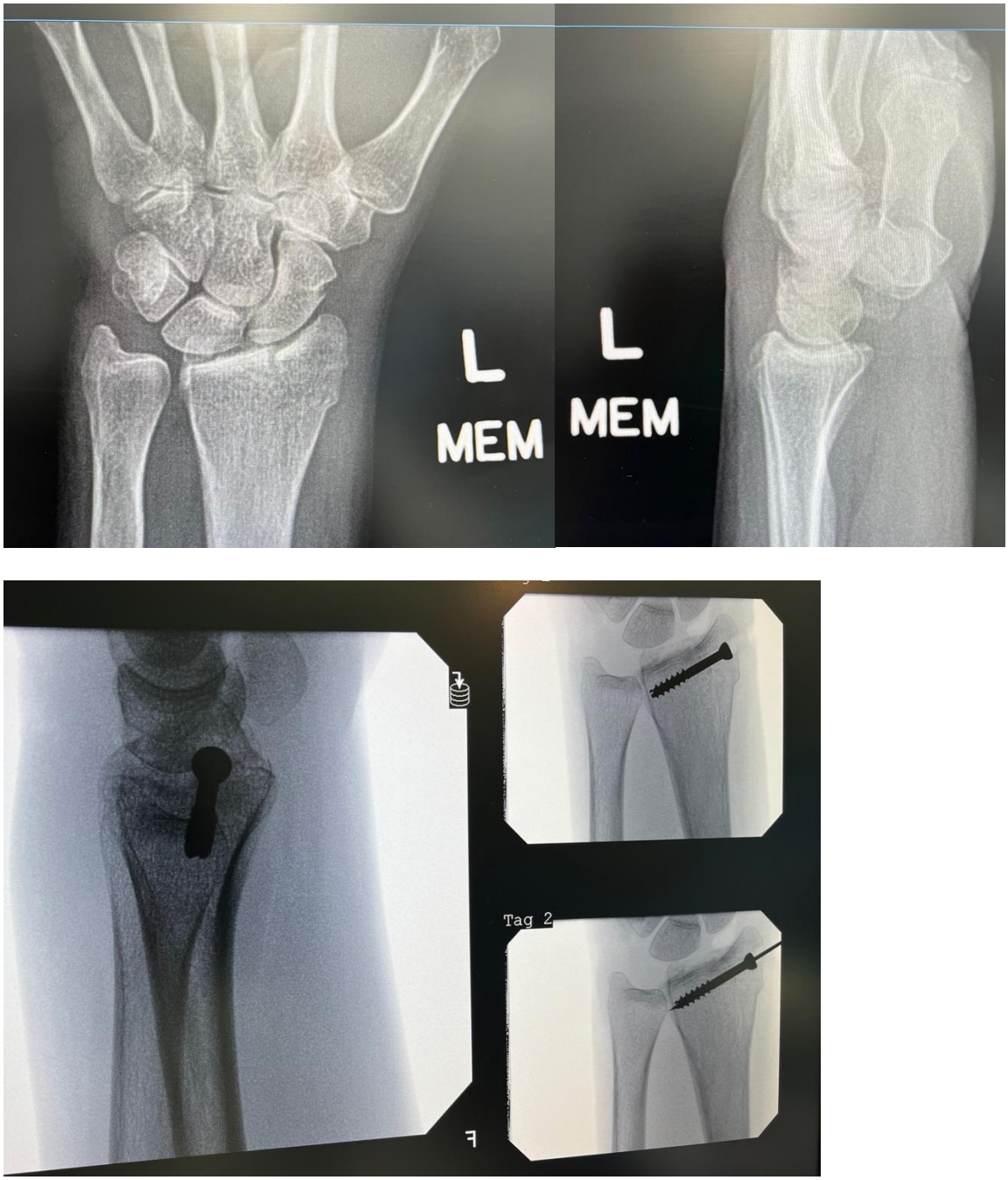

Figure 3: Pre-operative radiographs showing an intra-articular distal radius fracture. Intra-operative radiographs showing arthroscopic assisted reduction and screw fixation

- Key tips are:
    - Insufflate with saline. Aspirate to confirm that you are in the joint and remove haematoma

-
- Make a transverse incision as the scope moves left and right and the incision heals better than a longitudinal incision as it follows Langer's lines
- Use a 2.0mm scope and 3.0 mm shaver
- Have saline to the scope on gravity
- Identify the 6R portal site with a needle
- Use a hook and Frier to lift the fracture fragment

- Inserted a K wire to joystick the fracture fragment can be helpful before inserted a 4mm cannulated partially threaded screw to achieve compression and hold reduction

- Consider a first extensor compartment release. Look for EPB as a common site of compression

- <u>Which procedures can potentially be adopted in your future practice and how do they compare to your experiences at home</u>

Many of the techniques that I have seen can be possibly incorporated into my future practice in the UK. The finger cast works well and offers a cost-effective option; arthroscopic assessment of distal radial fractures can help understand fracture configuration and help reduction. I hope to bring some of the lessons I learnt from Dr Badia's clinic setup on managing patient flow back to the UK.

- What was the most significant personal experience of the scholarship for you (e.g. cultural exchange etc.)?

The most significant personal experience was the opportunity to hear from Dr Badia how the medical system works in the USA. He gave me a copy of his book, (*From the Trenches*, www.drbadiabook.com) which explains his insights as to the challenges and benefits of working in that system.

Closing words

- Tips to future scholars (housing, traveling etc.)

It is helpful to arrange a hotel within walking distance. Give your number to the practice manager or surgical coordinator as well as the doctor that you are visiting, in case there is a change of schedule, or any unexpected cases go to the operating room. Arrive well in advance and try and build in some time to see any local sites.

- Acknowledgement (thanking IBRA and the training center)

I would like to thank IBRA for supporting my fantastic visit Dr Badia and his team. I have learnt a huge amount and above are only a few of the highlights of the many notes that I kept scribbling down from my time with Dr Badia. I have appreciated different ways of working and made a friend and mentor for the future.