IBRA SCHOLARSHIP REPORT

Name of Scholar: **Martin V L Č E K, M.D., Ph.D.**

FN MOTOL

Affiliation: 1st Orthopaedic Clinic of 1st Faculty of Medicine of Charles University and Motol University Hospital , V Úvalu 84, Prague Czech Republic [1]

AUVA

Training Center: Lorenz Böhler Trauma Hospital, Donaueschingenstraße 13, Vienna Austria [2]

Fellowship Period: 03/04/2016 to 15/04/2016

Supervisor: Martin Leixnering, Prof., M.D.

Fig. 1. Lorenz Böhler Trauma Hospital: building of hospital, operating theaters and myself during the traineeship

I have been working on traumatology department on the University Hospital since 2001 as a surgeon. Currently, the traumatology department is organised under the 1st Orthopaedic Clinic of Motol University Hospital and 1st Medical Faculty of Charles University in Prague. I received the attestation of the first degree in the field of surgery in 2001 and specialized competence in the field of trauma surgery in 2008. I finished postgraduate studies in biomedicine in the program of Experimental Surgery in 2014. My dissertation thesis is called "Establishing optimal indications for distal radius fractures, based on fracture type, and comparison of the outcomes of clinical evaluation with mathematical modeling." I have published in several Czech and foreign medical journals as well as lectured at many regional and international conferences focused on the whole spectrum of trauma surgery of adults according to my competence.

Previously I participated in two courses focused on surgery of the hand and wrist in Lorenz Böhler Trauma Hospital organized by IBRA. I was excited about lectures and professional explanation during practice on cadavers. I longed therefore to watch Professor Dr Leixnering and his team during surgery. With the contribution from IBRA company (Scholarship program B: Clinical residential visit to a foreign host institution) I was able to spend two weeks in Lorenz Böhler Trauma Hospital (Fig 1). The aim of my scholarship was to identify differences in sugery in foreign hospitals to improve myself in the field of traumatology with special focus on the area of maximum interest - fractures of the distal radius.

Every day I attended the morning conference in the workplace, watched the surgeries taking place at four operating theaters, assisted in several operations and had the opportunity to watch bone and soft tissue surgery.

Lorenz Böhler Trauma Hospital is a modern hospital with brand new technical equipment and the best current implants are used for their surgery. This hospital

generally works on similar principles as ours. However, compared to the traumatology of Motol hospital I have to discuss many differences in the organization of work, interpersonal relationships and collective behavior to the patients (Fig. 2). The surgeons are minimally burdened by administration, documentation and surgery protocols are recorded on dictaphone. In the operating theater there was an overall friendly atmosphere in which operations could take place in complete tranquility.

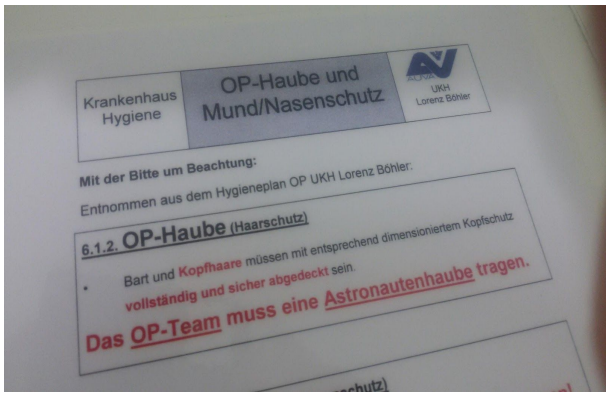

I had the opportunity to watch internal fixation of fractures of the limbs, osteosynthetic material extraction, treatment of wounds and also the surgeries from nontraumatic indications (bone cyst surgery, arthrodesis of the interphalangeal joint for arthrosis, ..). Surgical procedures are essentially similar to ours, however I noticed a lot of subtle differences.

Fig. 2. Antisepsis principles are strictly observed

I personally was interested in the "tips and tricks" during osteosynthesis of distal radius as they are a very common operative diagnosis (Fig. 3).

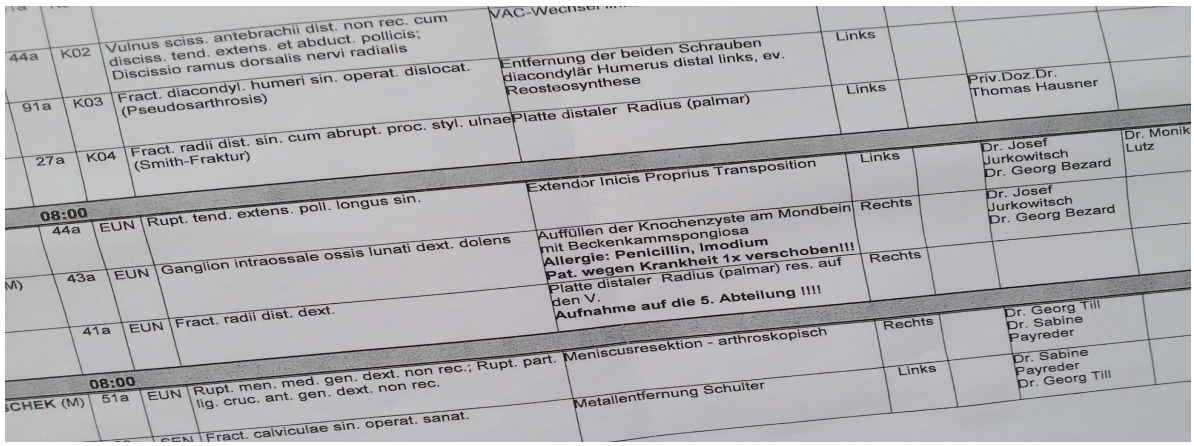

Fig. 3. Osteosynthesis of distal radius in Lorenz Böhler Trauma Hospital take place during the day on several operating theaters.

The best, from my experience, are the Aptus Radius 2.5 (Medartis, Switzerland) plates applied from volar approach. Surgeons are used to precise repositioning by using Kirschner wires to actually achieve anatomic reduction (Fig. 4). The volar "flexor carpi radialis" approach is clearly preferable, but to restore adequate volar tilt an adjunctive small incision from the dorsal side of the wrist is used and the reduction is carried out by the Kirschner wire introduced intrafocally (according to the Kapandji principle). For each fracture of the distal radius CT scans are performed.

I also perfected my theoretical knowledge: For example, I narrowed down the clear indication criteria for extraction APTUS plates (to be explained at the Soong

grade system for evaluating hazard position of the plate in terms of the possibility of flexor pollicis longus tendon rupture [3]).

Fig. 4. Even minimally dislocated fractures are indicated for surgery. Anatomic reduction before the application of variable angle locking plate is carefully achieved using Kirschner wires.

To deepen the theoretical knowledge I studied original papers from the specialised surgeons in this hospital relating to these surgeries. [4,5,6] .

The scholarship served its purpose and added to my experience which I will most certainly apply in my daily practice.

My thanks go especially to Prof Dr Leixnering, also Dr Jurkowitsch, Dr Pezzei and to other members of the surgical team. Thanks to Dr Keuchel for the great

hospitality, willingness in securing scholarships and comfortable accommodation in the hospital and the IBRA for providing this oportunity for me.

Referencies

[1] www.fnmotol.cz

[2] www.ukhlorenzboehler.at

[3] Soong M, Earp BE, Bishop G, Leung A, Blazar P.: Volar locking plate implant prominence and flexor tendon rupture. J Bone Joint Surg Am. 2011, 16; 93(4): 328-335.

[4] Leixnering M, Quadlbauer S, Szolarcz C, Schenk C, Leixnering S, Körpert K.: Prevention of hand injuries - current situation in Europe. Handchir Mikrochir Plast Chir. 2013, 45(6): 339-343.

[5] Weninger P, Dall'Ara E, Leixnering M, Pezzei C, Hertz H, Drobetz H, Redl H, Zysset P.: Volar fixed-angle plating of extra-articular distal radius fractures - a biomechanical analysis comparing threaded screws and smooth pegs. J Trauma., 2010, 69(5): E46-55.

[6] Figl M, Weninger P, Jurkowitsch J, Hofbauer M, Schauer J, Leixnering M.: Unstable distal radius fractures in the elderly patient - volar fixed-angle plate osteosynthesis prevents secondary loss of reduction. J Trauma. 2010, 68(4): 992-998.

Vienna, 2016, April 15th

Vlček Martin, M.D., Ph.D.