IBRA International Bone Research Association

IBRA Scholarship report

Scholarship Type: Program B - Clinical residential visit to a foreign host institution

Name of Scholar: V L Č E K Martin, MUDr. Ph.D.

E-mail: dr.martinvlcek@gmail.com
Telefon: 00 420 602280089

Country of Citizenship: Czech Republlic

Affiliation:

Orthopaedic Clinic of 1st Faculty of Medicine of Charles University and Motol University Hospital [1]
V Úvalu 84
150 06 Prague
Czech Republic

Education:
Educational Insitution: Charles University, First Faculty of Medicine, Prague, Czech Republic
Form of Study: Master's degrese (1992 -1998)

Educational Insitution: Charles University, 2nd Faculty of Medicine, Prague, Czech Republic
Form of Study: Doctoral Studies (2006 – 2014)
Specialization: Experimental Surgery
Thesis topic: Establishing optimal indications for distal radius fractures, based on fracture type and comparison of the outcomes of clinical evaluation with mathematical modelling

Specialized Qualification:
Discipline: Surgery - 1st stage attestation (2001), Traumatology - attestation (2008)

Publications:
21 journal publications (8 in impact factor journals)

Lectures:
35 lectures at international congresses

FIRST INTERNSHIP

Name and Country of Training Center:
Krankenhaus St. Elisabeth
Hand Center [2]
Elisabethenstr. 19
88212 Ravensburg
Germany

Name of Fellowship Director: Prof. Dr. med. Hermann Krimmer

Scholarship date: from April 9th to April 20 th, 2018

The Center for Hand Surgery in Ravensburg **(Fig. 1 and 2)** offers services covering the whole spectrum of hand surgery, The main focus of the Training Center is surgical treatment of degenerative hand and foot disorders, but there are also treated injuries that I personally have the greatest interest. I concentrated on ambulatory and surgical treatment of acute injuries and also post-traumatic conditions I have assisted about 30 surgeries. Once a week, the medical team meets before working time for breakfast at the clinic before to discuse unusual casuistics, to talk about news in the hand surgery, and to communicate new experiences from conferences.

Fig. 1. There is a garden in the area of the hospital developed to relax by staff, patients and their visits.

Fig. 2. Elisabeth Hospital Ravensburg is modern, very well equipped. The operating rooms are equipped with state-of-the-art devices. For the well-being of patients, it is devoted to artistic detail.

Fig. 3. Communication with the patient is devoted to a lot of time and the principles of surgeries are described very clearly in advance. The operation plan is visualized by drawing into X-rays and directly on the patient's hand.

In spite of a considerable number of outpatients, the examination and treatment takes place in a very friendly atmosphere **(Fig. 3)**. Some operations are performed using other operating techniques than at our workplace **(Fig. 4, 5 and 6)**. However, all operating procedures are preceded by a detailed indication balance, the operational technique itself is characterized by high precision. Osteosynthesis of smaller bones, unlike our case, is performed in outpatient and in local anesthesia **(Fig. 4)**.

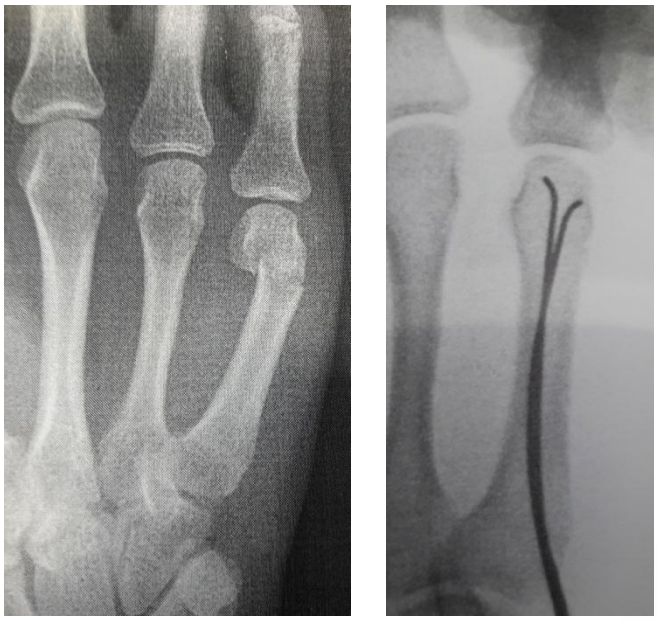

Fig. 4. For the stabilization of simple fractures, "old" proven miniinvasive methods in local anesthesia are use. Fracture of distal end of fifth metacaral bone treated using Förstner pins.

"I recognized a modern and very well equipped workplace where a small team of surgeons treats a large number of patients with maximum precision"

Fig. 5. Treatment of open finger fracture using mini-external fixator.

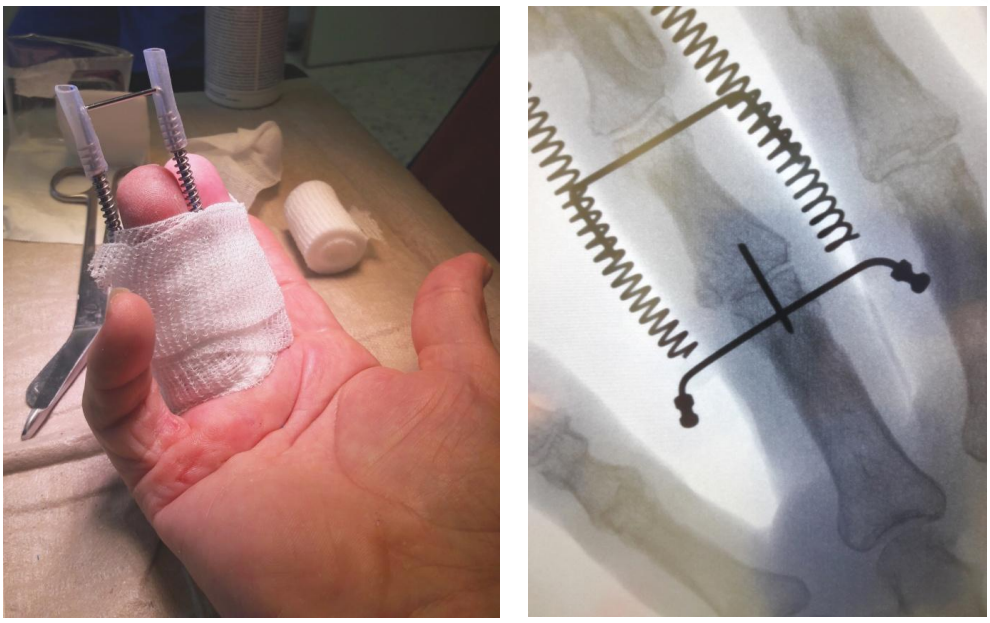

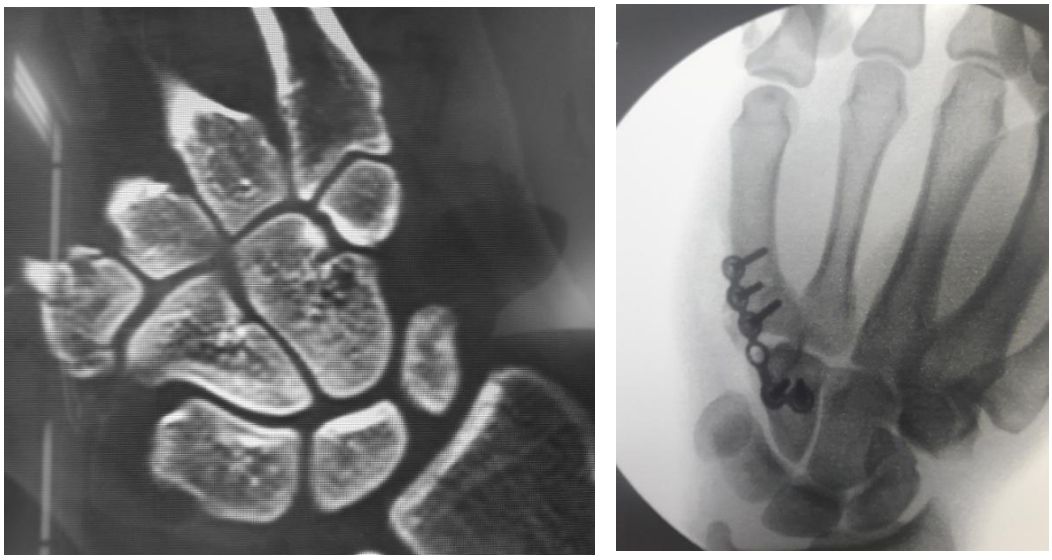

Fig. 6. Multifragmental fracture of the fifth metacarp base stabilized using variable-angle looking plate into the hamate bone.

Even more complicated surgery is done by the surgeons absolutely excellent, carefully and routinely and without any doubt **(Fig. 7)**. I was most attracted by the corrective osteotomy of the distal radius **[3]**. I have gained new experience in the conservative treatment of fractures, respectively in the application of plastic fixations.

„As the greatest benefit I personally perceive watching corrective osteotomies of distal radius.“

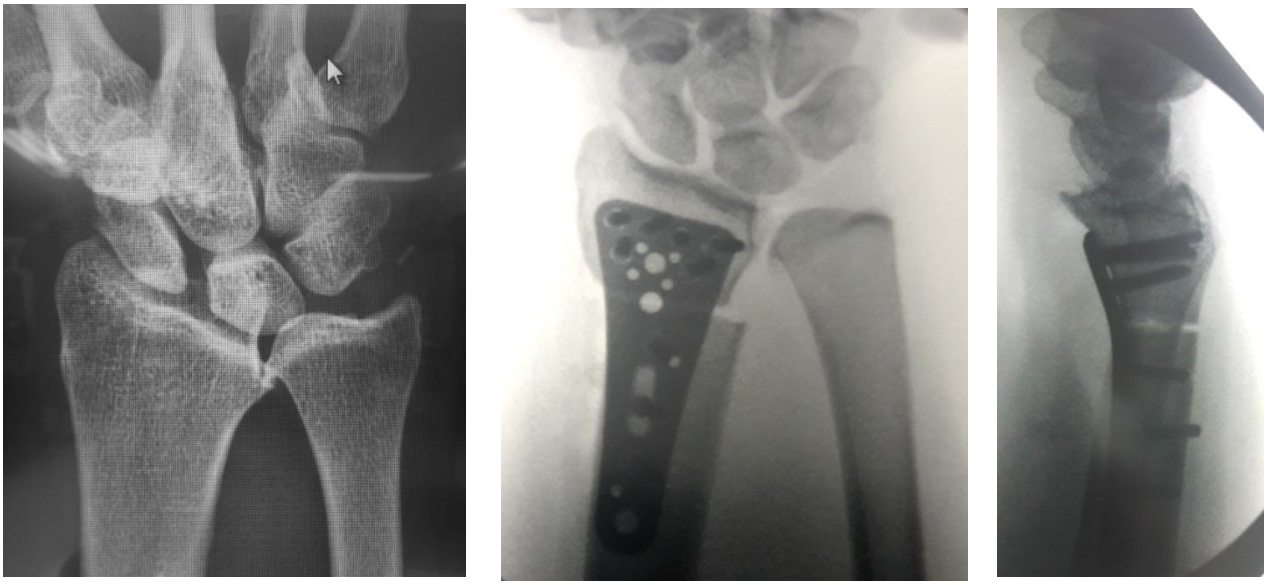

Fig. 7. Corrective osteotomy after failed distal radius fracture treated primarily at another hospital. The spacing between bone fragments is not filled with a graft of cancellous bone or synthetic bone replacement.

SERIOUS CRPS	
Prednison (tablet)	
Day	Dosage
1st	100 mg
2nd	100 mg
3rd	100 mg
4th	70 mg
5th	70 mg
6th	50 mg
7th	50 mg
8th	40 mg
9th	40 mg
10th	20 mg
11th	20 mg
12th	10 mg

LESS SERIOUS CRPS	
Methylprednisolon (tablet)	
Day	Dosage
1st	100 mg
2nd	100 mg
3rd	100 mg

Always to the corticoid + Helicid (tablet)	
Day	Dosage
every day	20 mg morning, 20 mg evening

Fig. 8. Dosage of corticoids during treatment of Complex Regional Pain Syndrome

While plaster fixation is almost exclusively used in my workplace, here it is plastic. Also, the fixation attachment technique is different: for example, we fix the metacarpal fractures with a splint attached from the dorsal side and we fix also fingers, here the splints are applied from the volar side of the wrist and hand, with the free fingers moving from the beginning of the treatment.

I was interested not only in operating procedures but also in pharmacotherapy. Application of corticoids during treatment Complex Regional Pain Syndrome, while here is standard **(Fig. 8)**.

During my stay I spent most of time with prof. Krimmer, dr. Wolters, dr. Schandl, dr. Smieja, and dr. Salama, thanks everyone for the helpful and flendly relationship to me. Despite of large amount of work, always had time to discuss interesting topics as well as answering to all of my questions. For a great help in organizational matters I thank the wife of professor, Mrs. Krimmer.

I found that the city of Ravensburg **(Fig. 9)** is very pleasant to live in the midst of the beautiful nature under the Alps near Lake Constance.

In my work I will certainly use the various techniques of conservative and surgical treatment that I have learned and I consider to be progressive. I will also try to apply to my work here the ubiquitous patience in communicating with patients.

Fig. 9. Ravensburg is an ancient, carefully maintained city with a peaceful atmosphere. The advantage is the possibility to transport through the city and to work by bicycle. Numerous restaurants attract you to sit and taste typical local dishes (on the picture „Schwäbischer Wurstsalat“).

SECOND INTERNSHIP

Name and Country of Training Center:
Klinik und Poliklinik für Orthopädie und Unfallchirurgie [4]
Kerpener Str. 62,
50937 Köln am Rhein
Germany

Name of Fellowship Director: Prof. Dr. med. Lars P. Müller

Scholarship date: from October 8th to October 19 th, 2018

The Department of Orthopedics and Trauma Surgery of University of Cologne **(Fig. 10 and 11)** deals with surgical treatment of acute and chronic conditions in these fields. Special interest and attention is paid to a comprehensive conception in the treatment of elbow joint diseases. I am traumatologist, so I was interested in osteosynthesis, reconstruction of ligaments, implantation of endoprostheses in the elbow **(Fig. 12, 13 and 14)**. All of these surgeries are performed here with unambiguous indication and absolute precision. It is a top scientific workplace, the institution is part of the "CCMB", Cologne Center for Molecular Biomechanics.

Fig. 10. Uniklinik Köln is a high-rise building set in a quiet residential area with low houses and many restaurants.

The research focuses of the CCMB are musculoskeletal injuries and diseases. For me personally, it was an interesting finding that there was a difference in the indication of the individual operating methods than usual in our workplace. In clinic of Cologne, alloplasty is much more often indicated in the treatment of acute traumatic conditions **(Fig. 15)**. Ability to work in

Fig. 11. Live music in the lobby makes it easier for patients to enter the hospital. Hospital equipment is at the top level. X-ray protective vests are extremely lightweight and flexible, making it easier work on operating rooms.

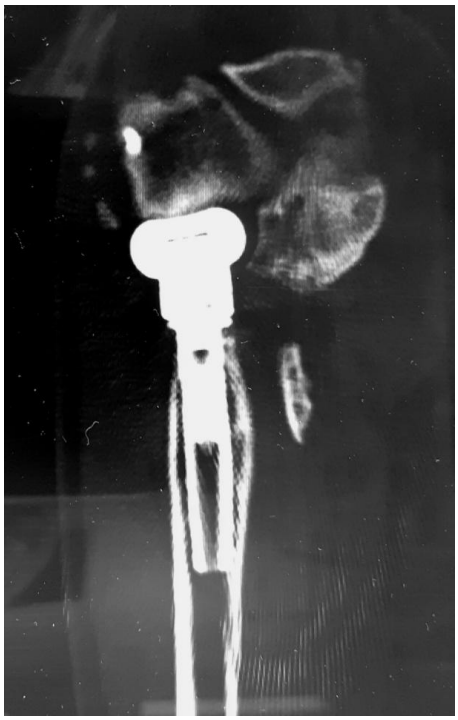

Fig. 12. Fractured capitulum of the humerus after radial head implantatiom resulting from elbow instability. Solved by surgical stabilization of the elbow joint using the tendon graft from brachial triceps muscle.

excellent quality is also due to the absence of time press and professional erudition of the whole team. Surgeons here really work together and not only "side by side".

„I have found top specialists in surgical treatment of elbow joint.“

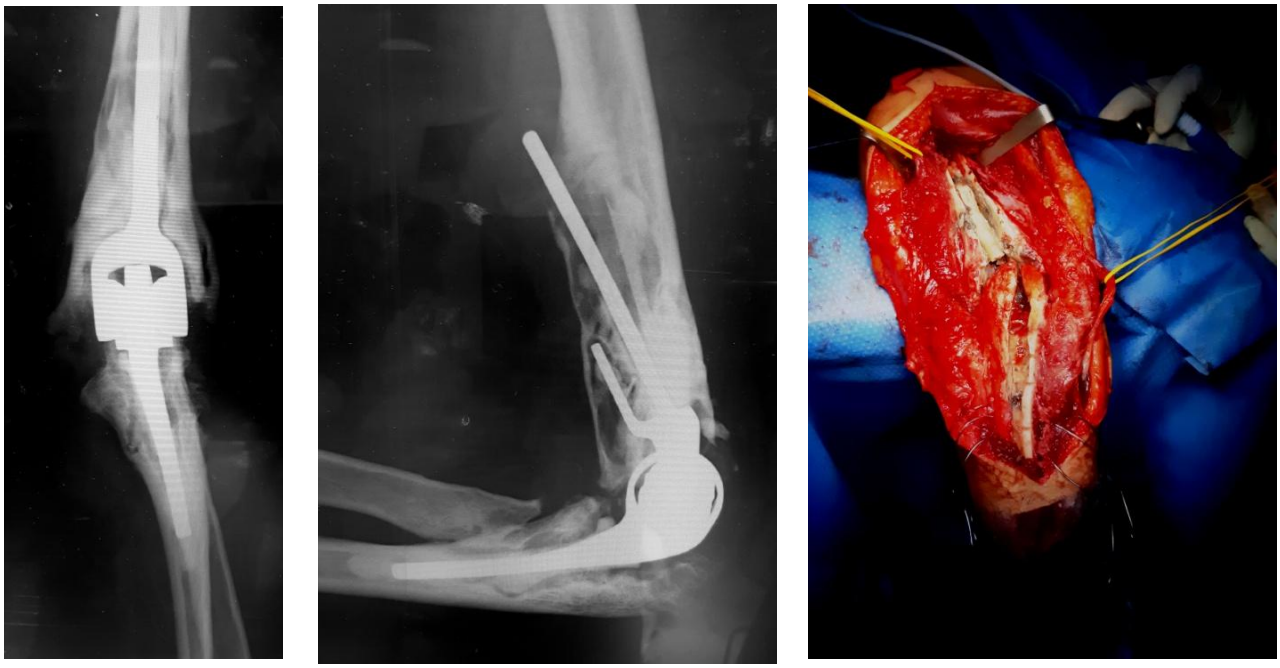

Fig. 13. Despite the possible complications of elbow endoprosthetics, these implants are not rejected.

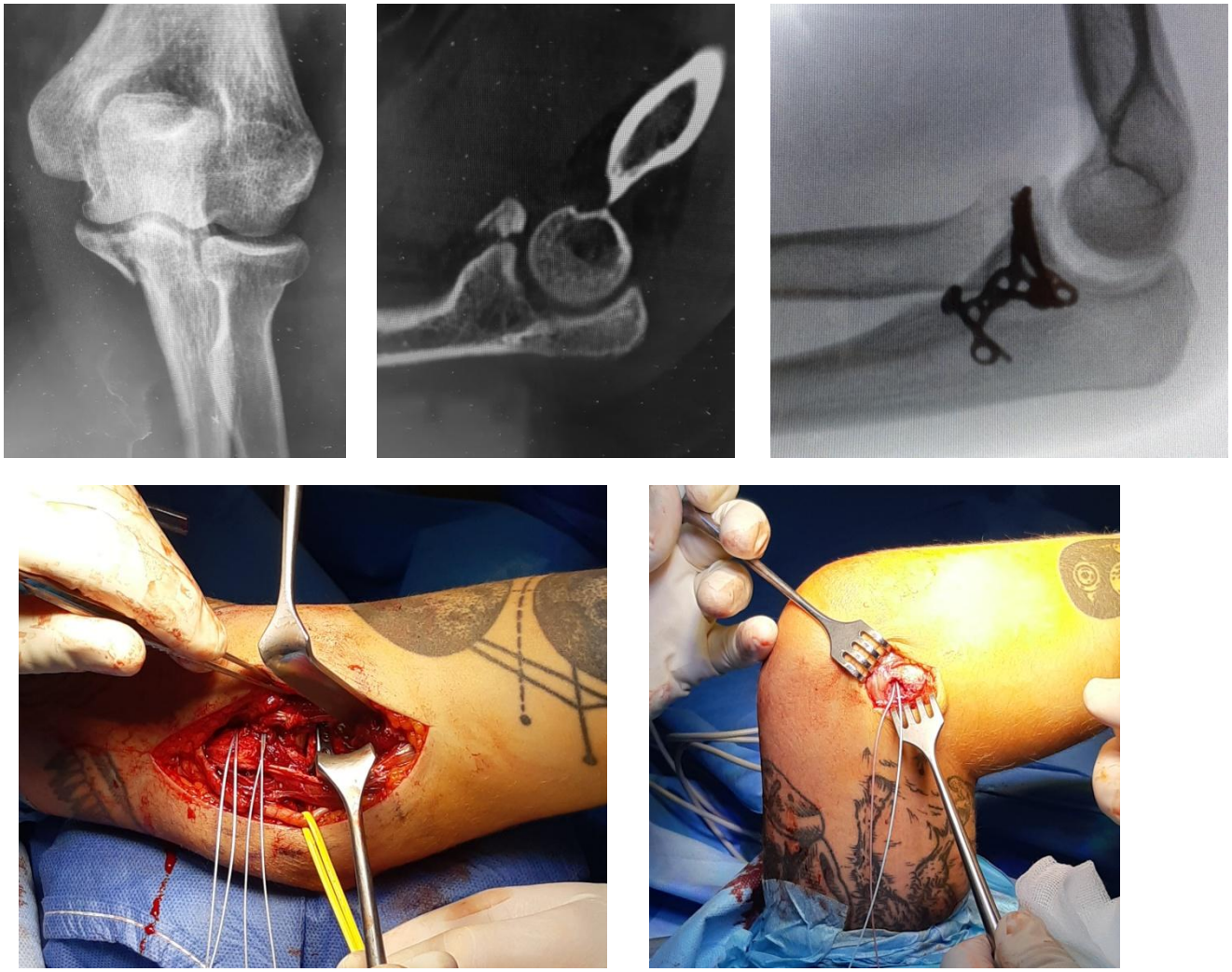

Fig. 14. Fracture of the proximal part of the ulna in a 28 year old patient. Open reduction and internal fixation was performed by a special angle stabile "coronoid plate". During the surgery, the nerves are always carefully prepared. Simultaneous injury of the radial colateral ligament was treated with a suture from a small incision.

„As the greatest benefit I personally perceive watching the techniques of reconstruction of elbow joint ligaments.“

„I recognized workplace where endoprosthetics is used in the treatment of traumatic conditions of the shoulder ant the elbow much more frequenthy than at our clinic.“

Fig. 15. Proximal humeral fracture of 74 your old woman. Indication of shoulder joint endoprosthesis.

Of course there is a perfect organization of work and compliance with standard protocols. Assistants start an operation and perform surgical approach, the professor comes to design the most important part of the surgery. Professor Müller is an excellent surgeon and a great teacher. He can talk about his interest in surgical treatment of elbow disease in a very engaging style. His

expertise is documented by countless publications. I was very pleased that he gave me as a gift one of his textbooks that attracted me with its scope and clarity **(Fig. 16) [5]**. This book will help me in my clinical practice, I know the authors are interested in treatment of the elbow joint very intensively and with great enthusiasm for many years. It's always easier and more enjoyable to learn from a book whose author you had the chance to meet and even see him to make surgery. Professor Müller has been my inspiration for developing not only in surgery, but also in scientific activity. He gave me the zeal to complete a textbook that I have been working on for a long time.

Fig. 16. The textbook "Elbow," the main author of which is Professor Müller, is very extensive and contains 528 pages and 1206 pictures. In the 2017 year, Association of Southern German Orthopedists and Trauma Surgeons granted to the authors for this publication the Carl Rabl Preis.

„I admire surgeons who not only carry out challenging operations, but they are able to pass on their experiences through the creation of textbooks.“

In terms of employee and student care, I was attracted by a local restaurant in the hospital. In a pleasant environment, it provides the possibility of eating according to modern principles of healthy nutrition **(Fig. 17)**. Cologne has a special atmosphere, although it is located in the northern part of Germany, local life especially at the weekend commemorates the holiday atmosphere of the south of Europe **(Fig. 18)**.

Fig. 17. The racing dining room contributes to the real coolness, where you can really enjoy delicious food. The freshness of fresh fish and excellently flavored vegetables is a matter of course.

Fig. 18. Although Cologne is the fourth largest city in Germany, life has a very peaceful atmosphere. A typical beer colled "Kölsch" can be tasted in many historic pubs. The special feature is their picking with barrel gravity into very small glasses of volume two deciliter.

ACKNOWLEDGMENT

My thanks go to IBRA to allow both traineeships to pass. My expectations have been fulfilled and in many ways even overcome. Thanks to prof. Krimmer and prof. Müller and their teams for a friendly admission to me. I have found extremely pleasant places for peaceful living and highly professional work in friendly teams. This scholarship program has been real great personal benefit to my career. In short, it was filled with the proverb that I saw written on window in the museum in Cologne: "The eye sees what it is looking for" **(Fig. 19)**.

Fig. 19. Quote of Slevogt on window in the museum in Cologne.

References

[1] www.fnmotol.cz

[2] www.handchirurgie-ravensburg.de

[3] Krimmer H.: Commentary on Farshad et al. Corrective osteotomy of distal radial deformities: a new method of guided locking fixed screw positioning. J Hand Surg Eur 2013;38:35.

[4] https://orthopaedie-unfallchirurgie.uk-koeln.de

[5] Müller L.P., Hollinger B., Burkhart K.: Ellenbogen. Georg Thieme Verlag KG, 2016. ISBN: 9783131749819

Prague, October 21th, 2018

Martin Vlček